HEARING IN CETACEANS

EVOLUTION OF THE ACCESSORY AIR SACS AND THE STRUCTURE AND FUNCTION OF THE OUTER AND MIDDLE EAR IN RECENT CETACEANS

BY

F. C. FRASER and P. E. PURVES
British Museum (Natural History)

Pp. 1–140 ; *Plates* 1–53 ; 34 *Text-figures*

BULLETIN OF
THE BRITISH MUSEUM (NATURAL HISTORY)
ZOOLOGY Vol. 7 No. 1
LONDON : 1960

THE BULLETIN OF THE BRITISH MUSEUM (NATURAL HISTORY), *instituted in* 1949, *is issued in five series corresponding to the Departments of the Museum, and an Historical Series.*

Parts appear at irregular intervals as they become ready. Volumes will contain about three or four hundred pages, and will not necessarily be completed within one calendar year.

This paper is Vol. 7, *No.* 1 *of the Zoological series.*

PRINTED BY ORDER OF THE TRUSTEES OF
THE BRITISH MUSEUM

Issued September, 1960 *Price Eighty Shillings*

HEARING IN CETACEANS

EVOLUTION OF THE ACCESSORY AIR SACS AND THE STRUCTURE AND FUNCTION OF THE OUTER AND MIDDLE EAR IN RECENT CETACEANS

By F. C. FRASER AND P. E. PURVES

CONTENTS

Notes. In the diagrams referred to in Figs. 16–21 as "transverse section" the plane of the section is through the foramen ovale and pterygoid hamulus. Owing to the progressive displacement forward of the hamuli from the foramen a varying degree of obliquity is introduced.

In relating Diagrams 22–25 to the skulls figured in Plates 5–47, it should be remembered that the latter represent ventro-lateral views of the skull.

Contractions used in the text-figures are to be found in the Key, Page 137.

HISTORY

In their previous paper (Fraser and Purves 1954) the writers made reference to the subject of pressure equalization and adjustment on either side of the tympanic membrane in the Cetacea. It was shown that Beauregard was the first to suggest a hypothesis which appeared to satisfy all the anatomical and physical requirements of the conditions encountered by cetaceans in their natural environment. Beauregard was however by no means the first to recognize the existence of the accessory air sinuses of the middle ear, and as a preliminary to the writers' own observations a brief historical summary of the earlier work on this subject is required.

Camper (1777) gives reference to Joh. Dan Major as the discoverer of the peribullary sinus in the year 1672, quoting the latter's paper he states " one should know that the petrous bones are not tightly attached to the cranium, but are lying loosely between the flesh and the fat close to the base of the brain and the occiput, at the side of the head, in a sinus, which is formed by two processes which do not touch each other ". Dan Major thus antedates Tyson (1680) who in his *Anatomy of the Porpoise* made much the same observation.

Hunter's (1787) description is a little more detailed. It is as follows :

" The Eustachian tube opens on the outside of the upper part of the fauces ; in some higher in the nose than in others ; highest I believe, in the Porpoise. From the cavity of the tympanum, where it is largest, it passes forwards and inwards, and near its termination is very much sacculated, as if glandular ".

" The Eustachian tube and tympanum communicate with several sinuses, which passing in various directions surround the bone of the ear. Some of these are cellular, similar to the cells of the mastoid process in the human subject, although not bony. There is a portion of this cellular structure of a particular kind, being white, ligamentous, and each part rather rounded than having flat sides. One of the sinuses passing out of the tympanum close to the membrana tympani goes a little in the same direction and communicates with a number of cells ".

" The whole function of the Eustachian tube is perhaps not known ; but it is evidently a duct from the cavity of the ear, or a passage for the mucus of these parts ; the external opening, having a particular form would incline us to believe that something is conveyed to the tympanum ".

Monro (1785) from the results of the dissection of a porpoise appears to have been the only writer to suggest the relationship of the air sinuses with the frontal, sphenoidal and maxillary sinuses of terrestrial mammals and it is noteworthy that these sinuses as such are totally absent in cetaceans.

Home (1812) found in *Balaena mysticetus* that the Eustachian tube had a similar glandular and sacculated appearance to that seen by Hunter in the porpoise.

Rapp (1837) made a review of the existing information about the cetacean ear and demonstrated in the porpoise the relation of the air sacs to adjacent bones. He stated that the anterior end of the tympanum was open and extended into a branching sinus. In front of the cavity of the tympanum lay a membranous, ovoid cavity over an inch long and wide enough for the insertion of a finger. Its upper and inner wall lay immediately against the bony surface of the skull. Branches extended further out, one forward, ending in the cavity of the pterygoid bone. Another went somewhat higher and forward to the outer side of the ascending branch of the palatine, and ended blindly, immediately behind the tooth row of the upper jaw. Still another branch went upwards, and passed into a bony canal which was found in the bone of the upper jaw, ascending on the outer side of the nasal cavity, until it reached the frontal bone and ended blindly. An extension of the main sinus passed outwards and ended under the supra-orbital process of the frontal, and finally a backward extension passed between the ear bones and the ridge of the basioccipital bone. All the sinuses were lined by a thin, and on the inner surface, smooth, white, glandular membrane. He described the Eustachian tube and in addition to what was already known, noted the absence of cartilage in its structure and that it passed through no bone. He observed the presence of crescent-shaped valves projecting into the lumen of the tube and directed towards the nares. In his opinion the valves could not quite close the lumen. Rapp gave a description of the pterygoid muscles and in general Stannius' (1849) account agrees with that of the former author.

Carte and Macalister (1868) gave an account of the dissection of a Lesser Rorqual which, in addition to a short description of the osteology and musculature of the pterygoid region, included a more detailed reference to a very remarkable plexus of arteries and veins which lay in a distinct cavity bounded internally by the pterygoid muscle and externally by the angle of the mandible and fibro-cartilage. The cavity was lined by an extremely delicate, glistening, membranous structure, similar in texture and appearance to the serous lining membrane of the veins. The vascular plexus itself extended from the coronoid process of the lower jaw to a point midway between the angle of the latter bone and the upper border of the sternum. The venous ramifications that partly formed the plexus gradually united as they passed backwards and ultimately formed one trunk, the jugular vein.

In the course of his work on the anatomy of the Pilot Whale (*Globicephala melaena*) Murie (1878) noted several anatomical features which he considered to be common to cetaceans in general. " In all the Cetacea cut up by me I have observed well developed and separate *pterygoidei*. The external, flat, broad, fleshy and of a quadrilateral shape, is fixed to the outer surface of the pterygoid plate and with a downward and forward plane goes to the inner surface of the lower jaw chiefly to the upper margin of the bone. The internal muscle arises from the superficies of the prominent portion of the pterygo-palatine, passes backwards and downwards to the mandible. Inferiorly and on its posterior border, the latter muscle sends off tendinous fibres which join those of the articulating condylar process of the mandibular." Following a description of the tympanic bulla and neighbouring tissues which coincides with those of earlier writers he goes on, " The Eustachian canal as it leaves the tympanic bulla, has considerable diameter and retains it more or less uniform as it passes towards the fauces. A tough membrane and retia mirabilia lie superficial to it ".

Later he states : " Of the cranial vascular distribution, circumstances did not permit me to master it in detail. The more notable observations I could make were chiefly regarding a great plexus situated at the inferior base of the skull and situated with a rete occupying the proximal infundibular cavity of the mandible. I subsequently had an opportunity of investigating the same in *Grampus* and *Lagenorhynchus* where it likewise obtains ".

" The internal maxillary artery having passed deeply behind the lower jaw, and made a bend, sends forwards a long inferior dental artery. As this pursues its course it distributes ramifications among the fatty matters and plexus presently to be mentioned. The mandibular cavity contains a mass of softish, marrow-like substances held together by a network of fibrous tissue. Moreover the interstices are occupied with a maze of vascular channels partly composed of arterial and partly of venous capillaries interwoven irregularly. Next the bone the tissue and vessels are firmly adherent to the periosteum in some cetaceans, e.g. the great *Balaena mysticetus* and *Balaenoptera musculus*, as I myself have been a witness to, the cavity in question possesses a perfectly enormous amount of oily material. Even in smaller genera the quantity is by no means sparse ; so that the tissues hereabouts as a whole and on section may be compared to blubber supercharged with blood vessels. Further on, the internal maxillary gives off large muscular branches and others forming pterygo-maxillary divisions. These latter were not followed into the cranium. The inferior base of the skull, from the tympanic bone forwards to the maxillary, internally bounded by the levator and sphincter muscles of the posterior nares, represents one continuous rete mirabile. This spongy network of vessels lies upon a thick layer of fibroid tissue, and the vessels anastomose with the aforesaid mandibular rete whilst they likewise appear to inter-communicate with another venous locular network behind and at the root of the Eustachian tube. The venous capillaries collect into a jugular channel more or less connected with the rete of the neck ".

Anderson (1879) in his account of the anatomy of *Platanista* found the situation of the air sacs so comparable with the " guttural pouches " of the Perissodactyla that he refers to them as such.

His description reflects the highly involved and complicated arrangement of these cavities but essentially they are a paired structure each member of which originates from the Eustachian tube. Part of each sac lies between the stylo-hyoid and the thyro-hyal, forming attachments to these, with its internal wall against the the outer wall of the back of the pharynx while the roof of the sac lies below the exoccipital and basioccipital bones. The inner surface of the sac is " white, smooth, glistening and tendinous in appearance and its wall has numerous deep recesses of various dimensions formed by arching folds of the membrane constituting the walls of the sacs—some of the recesses lead into small secondary pouches and from from these into a labyrinth of smaller passages."

" A pair of diverticula from these sacs converge in front of the thyroid cartilage where they are separated only by a thin membrane ".

Of the microscopical appearance of the Eustachian sacs Anderson says that they are composed of loose folds of thick mucous membrane. " Flat, irregular papillae invest the surface, and everywhere, . . . are small pits and minute orifices of mucous glands. These glands are most of them superficially situated but some are sunk deeper into the tissue, chiefly simple and tubular. Certain of them nevertheless are slightly racemose ; and all contain cylindrical epithelium with often a central cavity. The elevated papillae are exceedingly vascular, indeed possess a thick network of fine capillaries the parent vessels of which are both numerous and of considerable calibre. The free surfaces of the papillae are covered by a close-set layer of cylindrical, fringed or ciliated epithelium. The deep connective tissue of the submucous membrane is loose, strong fibred, but very open, some fat cells and oily particles being mingled with the tissue, while elliptical-shaped great bundles of striped muscular fibres course in different directions, right up almost to the glandular layer in some instances ".

The contributions of Beauregard (1894) to the knowledge of the anatomy and physiology of the organ of hearing of mammals constitute a major advance, especially to the extent that they concern cetaceans. He was the first person to inject the sacs of the middle ear and to give names to the component parts. In addition he puts forward a physiological hypothesis of their function which appears to be more acceptable than those of earlier writers. Having successfully injected the middle ear and sacs, both of Odontoceti and of Mysticeti, the following features were noticed. In the Common Dolphin the Eustachian tube was funnel-shaped anteriorly, its orifice a longitudinal slit in the posterior region of the nares. The tube was about 4 mm in diameter and lay against the bony wall of that part of the nostril formed by the pterygoid. For two centimetres from its orifice the tube passed obliquely outwards and posteriorly along a notch formed by the sphenoid and pterygoid. The mucous membrane of the tube was areolar throughout its length. There was in addition on the inner wall, a longitudinal fibrous ridge which extended to the lower wall of the tube and united with it near the entrance to the bulla. The duct was thus divided into two parts, one external, which terminated in a cul-de-sac, and another internal, which showed inside an orifice, joining the end of the bulla and making communication between the Eustachian tube and a vast air cavity emanating from the bulla. The orifice in question measured one cm long by three mm wide and was placed in such a way that by its intermediate position it communicated simultaneously with the blind canal, the tympanic cavity and air sacs.

A downward extension of the squamosal, a characteristic feature of all cetaceans, was designated the *falciform process*, a name by which it is now recognized. The names employed by Beauregard for the divisions of the sinus system are so generally applicable that they will be used as applied by Beauregard throughout this paper with one exception. The following is a summary of Beauregard's description. The sacs or sinuses are as follows :

1. *The Anterior Sac.*
2. *Pterygoid Sac.*
3. *Peribullary Sac.*
4. *Posterior Sac.*
5. *Medial Sac.*

All of these cavities communicate with the middle ear proper.

The anterior sac. This is very large—extending over all the ventral surface of the cranium anterior to the falciform process, surrounding the foramina of the cranial nerves and penetrating between the irregularities of the bone in the frontal and preorbital regions. In the Common Dolphin it is prolonged in a deep channel extending in the ventral surface of the maxilla for about two thirds of the latter's length. (As the greater part of the sac has been identified by the present writers as belonging properly to the pterygoid sac, the use of " Anterior Sac " will be restricted to that part of the system projecting beyond the posterior limit of the rostrum).

The pterygoid sac. A large diverticulum, filling the deep cavity which the palatine and pterygoid make as they fold below the sphenoid, is given the name of the pterygoid sac. Part of the Eustachian tube in its course to its external opening lies in close apposition to this sac.

The peribullary sac. Beauregard's anterior sac communicates posteriorly with a space which lies between the periotic and the bones of the cranium. This cavity, limited mesially by the occipital crest and dorsally by the dura mater contains the ear bones. The fibrous, saccular extension from the " anterior sac " which lines the cavity is called the peribullary sac. Beauregard pointed out that it does not extend to the ventral surface of the bulla which is covered in this region by a thick pad of fibrous tissue.

The posterior sac. The posterior sac communicates with the tympanic cavity by the posterior orifice of the bulla. It occupies the concavity of the paroccipital process. This cavity is sheathed in thick cartilage and enveloped anteriorly and posteriorly in a strong cushion of fat.

The medial sac. The medial sac communicates with the tympanic cavity by the petro-tympanic orifice and is situated under the concave surface of the zygomatic process, internal and posterior to the glenoid fossa. It is prolonged into the groove formed in this region and is limited anteriorly by the curved and concave border of the falciform process. The present writers will refer to the concavity in the squamosal in which the medial sac is lodged as the tympano-squamosal recess.

All the sacs are distinguished by the presence of numerous trabeculae which divide their cavities into complicated air pockets. Blood vessels, especially veins, form a rete of great richness. From the superior wall of the great "anterior sac" a thick, prominent ridge of mucous membrane protrudes, which is areolar and very vascular and gains access to the bulla by which it penetrates the tympanic cavity. This fold, reduced to very nearly a cylindrical cord when it enters the cavity, is there developed into a spongy mass which passes along the whole length of the bulla. Beauregard goes on to say that it is attached by its concave border to the anterior process of the external lip of the bulla, then to the body of the malleus near the tubercle to which is attached the ligament of the tympanic membrane. It terminates by an enlarged extremity near the fenestra rotunda, fixing itself to the base of the mastoid process.

According to Beauregard, the relationship of this spongy mass with the hammer and the anterior orifice of the bulla gives rise to the supposition that it acts as a muscle for the malleus ; but on microscopic examination he was unable to find any trace of muscle fibres. (For discussion of this see page 29).

He injected the vessels of the region of the ear of a foetal dolphin 110 cm long. He found that the internal carotid artery accompanied by the (internal) jugular vein passed along the deep notch separating the basi-occipital from the mastoid region. It penetrated the tympanic cavity in the space which limits the internal lip of the bulla and the groove which separates the posterior promontory of the bulla from the periotic. In this first part of its course the internal carotid artery was a neighbour of the facial nerve. In the tympanic cavity it occupied the long axis of the spongy mass and measured not less than 3 mm in diameter. Its course was sinuous. It made a curve towards the dorsal convexity, another towards the ventral convexity, and then made straight towards the anterior extremity of the tympanic cavity. It emerged from that extremity and penetrated the great " anterior air sac ", crossing the latter obliquely before entering the carotid orifice of the cranium. During its passage across the tympanic cavity the carotid artery was found to be enveloped in a voluminous venous plexus, the varicose ramifications of which measured from 1–5 mm in diameter. This plexus, mixed with fibrous tissue is the enigmatic spongy organ. Beauregard considered the spongy organ, in common with all the other venous retia in the pterygoid region, to be erectile, but this aspect of his hypothesis will be discussed later (pages 119–120).

Beauregard continued his researches by injecting the air sinuses of a Lesser Rorqual. He found that the Eustachian tube, in its course rearwards, passed between the angle formed by the inferior border of the sphenoid and the hamular process of the pterygoid. Subsequently it connected with a large ovoid sinus occupying the pterygoid. He considered the sinus to be an enlargement of the posterior extremity of the Eustachian tube, and established the connection between these and the tympanic cavity proper. He homologized a large cavity on the upper and mesial surface of the bulla with the peribullary sac, and similarly a small diverticulum at the posterior extremity of the bulla was recognized as the posterior sac.

Finally Beauregard identified the "glove finger" of the tympanic membrane with the medial sac, but the present writers (Fraser and Purves, 1954) suggested its relationship with the "pars flaccida" (but see also p. 113–5).

Denker (1902) examined the ear region of cetaceans and although not dealing with the anatomy of the air sinuses suggested a possible means by which they function.

The work of Boenninghaus on *Phocaena phocoena* contained in two monographs produced in 1902 and 1904 constitutes the most comprehensive study of the anatomy of the throat and ear of cetaceans ever published. The earlier paper is concerned chiefly with the musculature of the throat and nose, and the other more particularly with the ear. Parts of the latter paper are more relevant to the subject of the air sinuses but it is necessary in the survey of them which follows to include extracts from the earlier work. His long, detailed description of the bones of the base of the skull recapitulates what has been written by a number of earlier writers and need not be repeated. Information about the morphology and relationships of bones concerned with the air sacs can be seen on Pls. 5–47. As the musculature and associated structures of the throat and mouth are important in the comprehension of the evolution and function of the air sacs, a more detailed note must be made of Boenninghaus' findings. These will be dealt with in the following order: (1) Musculature of the posterior nares; (2) the soft parts of the pterygoid region in general; (3) the fibrous supporting tissue of the skull base; (4) the intra-mandibular fatty body; (5) the pterygoid and palatine muscles; (6) the arteries; (7) the veins.

1. *Musculature of the posterior nares.* According to Boenninghaus, the muscular complex of the posterior nares is made up of the following elements: (*a*) m. constrictor-pharyngeus-superioris, (*b*) m. palato-pharyngeus, (*c*) m. thyro-palatinus, (*d*) m. salpingo-pharyngeus, (*e*) m. levator palati, (*f*) m. tensor palati, (*g*) m. stylo-pharyngeus.

(a) *Constrictor-pharyngeus-superioris.* "The whole pars superioris of the pharynx has been greatly drawn out by the up-turning and lengthening of the presphenoid, thereby the form of the rear wall has become changed. In land mammals the m. constrictor inferioris seen from behind partly covers the m. constrictor medius and the latter partly covers the constrictor superioris. The constrictors lie like the slides of a half-open telescope, one over the other. In *Phocaena*, however, the m. constrictor superioris is completely withdrawn from the medius and inferioris. The gap thus created is filled by the palato-pharyngeus ".

(b) *M. palato-pharyngeus.* " The inner face of the muscular pharynx of *Phocaena* is formed, except at the palato-pharyngeal arc, by a single, extended, thick muscle, the fibres of which lie parallel, while they are in the posterior nares, then behind these radiate fan-wise in sweeping lines towards the rear of the pharynx so that the lowest fibre layers encircle the epiglottis. At their posterior extremity the fibres merge bilaterally but do not form a raphe. This muscle is further distinguished by the fact that near its lower end a powerful sphincter muscle 9 cm thick arises from its inner surface and is so formed that its superior surface merges without boundary into the m. palato-pharyngeus. Its ventral, sharper rim lies mesial to the latter and forms the mesial boundary of a pair of lateral pockets open dorsally. This sphincter lies underneath the swelling of the mucous membrane known as the arcus pharyngeus which tightly encloses the upper part of the epiglottis and arytenoid cartilage."

(*c*) *M. thyro-palatinus.* " From the ventral rim of this constrictor some bundles (of muscle fibre) emerge which do not encircle the epiglottis but proceed laterally and ventrally to be inserted into the thyroid cartilage. This extension of the pars interna of the m. palato-pharyngeus is known otherwise only in man and the horse and is named the thyro-palatinus."

(d) *M. salpingo-pharyngeus.* " From the ventral extremity of the bony nares a muscle originates, which, like the constrictor superioris passes obliquely and medially downwards. Having emerged from the nares it lies alongside its counterpart from the other nostril for a short distance and eventually merges with its fellow. Only a narrow streak of the m. salpingo-pharyngeus can be observed from the inner aspect of the naso-pharynx but on the outer aspect of the naso-pharyngeal muscle mass it can be seen to widen considerably and overlie the united superior constrictor palato-pharyngeus (pars externa). At its ventral extremity the m. salpingo-pharyngeus unites, by means of a light inscriptio tendinea . . . with the m. longitudinalis oesophagi."

(e) *M. levator palati.* " From the upper border of the naso-pharynx there arises a muscle which encircles the boundary of the pterygo-palatine attachment of naso-pharyngeal muscle mass from front to rear in a pointed curve. At the anterior narial wall it dips downward, lying close to the septum and finally merges without visible boundary into its respective half of the pars interna of the palato-pharyngeus."

" In its string-like outer form, as in the delicacy and lighter colouring of its fibres it corresponds so completely with the pars interna of the m. palato-pharyngeus and its continuation, the arcus palatinus that the whole gives the impression of forming a combined muscle system."

(f) *M. tensor palati.* " At the lower margin of the posterior nares and attaching to the origin of the m. salpingo-pharyngeus some delicate muscle streaks leave the region of the mouth of the Eustachian tube and radiate between the fibres of the m. constrictor superior obliquely without our being able to follow them between these fibres for any considerable distance. " Boenninghaus reports that Zuckerhandl confused the tensor palati with the internal pterygoid saying " certainly the tensor palati is to be found in this position in all other mammals except in the whales, i.e. between the internal pterygoid and the Eustachian tube ". This is discussed in the present paper on p. 19.

(g) *M. stylo-pharyngeus.* " This is originally an unpaired muscle which springs from the floor of the posterior nares and diverges into two limbs each of which is attached to the rear part of its respective styloid. The free outer face of the muscle is streaked longitudinally and without a raphe, on the inner face the fibres lack any definite direction and are firmly fused with the ventral face of the m. palato-pharyngeus."

2. *The soft parts of the pterygoid region.* Boenninghaus dissected the pterygoid region in three stages, shown in Pl. 1, figs. *a*, *b*, and *c* (corresponding to his Pl. 12, figs. 3, 4 and 5). The first, the most superficial stage, shows the following structures (fig. *a*). The bony nasopharynx is filled by the naso-pharyngeal muscle mass which rises into the nose through the " false choanae " (Pl. 1, fig. *a*). The whole lateral part of the skull base is covered by the m. pterygoideus internus (2) under which posteriorly can be seen the eminence of the tympanic bulla (17). The m. pterygoideus internus and the pharynx are separated by the pterygoid ligament (5′). When the attachment of the pterygoid muscle is separated from this ligament, and the muscle reflected, one sees that the ligament forms the ventral edge of a mass of tissue, smooth and membranous posteriorly, and anteriorly pierced by large holes. The holes give entry to the vena pterygoidea (16) and to the pterygoid fibro-cavernous venous plexus. Laterally the m. mylo-hyoideus is reflected over the jaw. Boenninghaus' next figure (Pl. 1, fig. *b*) depicts a dissection made one cm more dorsally than that of fig. *a* and from which the naso-pharyngeal muscle mass has been removed. As seen in the figure, the following structures are to be distinguished. Laterally from the pterygoid (18) the Eustachian tube is open at its distal end and leads into the vestibulum pneumaticum (8), this in turn leads into the bulla (17) in which is a conspicuous body (17′) the corpus cavernosum tympanicum. Beside the tube one sees the pterygoid fibro-cavernous venous plexus (5′). The massive fatty body of the lower jaw (6), as well as the jaw itself, can be seen. The third dissection (fig. *c*) is again one cm deeper than the previous one. The pterygoid bone, the lower jaw, fatty body and the pterygoid muscle have been removed. The anterior pneumatic cavities (9, 10, 11) are seen to be connected with the vestibulum pneumaticum (8). Overlying this is the pterygoid fibro-cavernous venous plexus (5′).

In the figure there are probes from space to space.

3. *The fibrous supporting tissue at the skull base.* The skull base of the toothed whales has a supporting tissue which is not found in any land mammals. From this, continues Boenninghaus, it may be assumed that it plays some important role in these aquatic mammals One can distinguish posteriorly a smooth, flatter, non-perforate part from an anterior portion which is thicker and pierced by many veins. The rear part covers the bulla while the anterior part lies in front of it. The fossa of the skull base which contains the tympano-periotic bones is closed ventrally by a fibrous membrane which covers the ventral surface of the tympanic bulla, and is attached to the cartilaginous ventral edges of the basi-occipital, the paroccipital

and the zygomatic process of the squamosal. This tissue bridges the paroccipital fissure and is penetrated by the meatus and facial nerve. Boenninghaus makes the important indication that he regarded the tissue as the perichondrium or the periosteum of the bones just referred to. The tissue round the bulla is up to 1 cm thick and is strongly attached to the roughened, ventral surface of the latter, acting as a support ventrally for the bulla.

From the posteriorly directed tip of the ala palatina (19) and from the adjacent plate of the pterygoid (8) there originates a wide, reticular, ventral membrane. It is directed posteriorly towards the supporting tissue of the bulla and merges with it. Mesially it covers the Eustachian tube (7, fig. *b*) and the vestibulum pneumaticum (8) and ends ventrally in a ligament-like edge, the pterygoid ligament (5″, fig. *a*). Laterally the membrane has a wide attachment to the falciform process. Part of the membrane in this region does not fasten on to the wide line of attachment but runs more posteriorly and laterally, surrounding the bulla, and merging with the thickened periosteum of the zygomatic process. This membranous tissue is traversed by many large and small intercommunicating, venous cavities which appear oval in transverse section. It has extensions which pass round the median aspect of the Eustachian tube and through the gaps in the skull to the dura mater. There is also an extension from the zygomatic process of the squamosal to the post-orbital process of the frontal (fig. *22c*,) which closes the otherwise incomplete orbit ventrally.

4. *The intra-mandibular fatty body*. On the inner surface of the lower jaw of toothed whales is a fatty body of considerable size (Pl. 1, fig. *b*). An interesting peculiarity of the lower jaw is that the posterior half of the median wall is completely absent. The anterior half ends in a posteriorly open arcuate edge which forms the entrance to the wide mandibular hiatus corresponding to the mandibular foramen of other mammals. The wide, bony trough at the hinder end of the lower jaw is occupied by the fatty body. Boenninghaus considers this to be the bone marrow of the posterior half of the lower jaw, and states that it is covered by a strong fibrous tissue continuous with the periosteum of lateral aspect of the lower jaw, and forms an attachment for the pterygoid and mylo-hyoid muscles (see fig. *b*). The fatty body is traversed by the mandibular vessels and nerves and a strong fibrous tissue with a wide mesh. The marrow lying in this tissue mesh is not of the usual consistency but is semi-liquid and oil-like. It has a tendency to hypertrophy since it sends out extensions covered by periosteum in various directions. It forces its way to the mylo-hyoid (Pl. 1, fig. *b*, 5) and grows forward over the edge of the hiatus mandibularis for some distance, lifting the pterygoid muscles from the ventral border of the jaw. Also a further extension lies in the deep trough adjacent to the ventro-lateral aspect of the bulla and, according to Boenninghaus, is continuous with the supporting fibrous tissue of the latter.

5. *The pterygoid muscles*. According to Boenninghaus the internal pterygoid muscle (2 in Pl. 1, figs. *a* and *b*) covers the whole of the ventro-lateral skull base. It originates from the lateral edge of the maxilla, from the lateral edge of the palatine, from the palatine process of the pterygoid, from the pterygoid ligament and from the basioccipital process. From these attachments the fibres stretch obliquely backwards and outwards and are inserted into the mesial periosteal wall of the lower

jaw fatty body. Posteriorly it is attached to the fibrous sheath of the bulla and anteriorly to the bony part of the mandible (but see p. 18).

The external pterygoid lies dorsally and laterally to the internal pterygoid and has a similar but more dorsally situated origin. Its insertion is also partly on the periosteum of the marrow and on the narrow dorsal edge of the posterior portion of the lower jaw. Its course is obliquely outwards and more horizontal than that of the internal pterygoid (but see p. 17–18).

6. *Arterial supply.* Boenninghaus describes the vascular system of the base of the cranium in great detail, but only certain features of his account are relevant to the present paper. His main concern is with the course and atrophy of the internal carotid artery and with the alternative cranial blood supply through the spinal meningeal arteries. Nevertheless, the diagram which he uses to illustrate the first of these features is useful for showing the external carotid and its extensions, although Boenninghaus regarded it as unnecessary of mention in his text. The figure (Text-fig. 1) shows the very short innominate artery giving rise soon to the internal and external carotids. The external carotid curves slightly round the lateral aspect of the tympanic bulla after having given off a branch labelled " external maxillary " by Boenninghaus but more correctly to be interpreted as the transverse cervical, it passes forward lateral to the air sacs and gives off a plexus of vessels supplying the fibro-cavernous venous plexus ; at about the same point the temporal artery originates. The main stem continues anteriorly as the internal maxillary.

7. *Venous drainage.* As with arterial supply so with the venous drainage system Boenninghaus' account is very involved and difficult to follow. It is perhaps best understood, for the purpose of later discussion (p. 29) by reference to his schematic diagrams (Text-fig. 2) reproduced here. Although his identification of the main venous trunks, coincides with that of the present writers his interpretation of some of the details is open to criticism.

Hanke (1914) examined the foetuses of several whalebone whales and was able only to identify the peribullary and medial sinuses. " The largest of the pneumatic cavities the sinus pterygoideus seems to develop at rather a later stage and its size and position is influenced by the position of the tympano-periotic." He further noted that while in the embryo the pterygoid is in contact with the anterior margin of the bulla, in the adult there is a gap of as much as 10 cm between the two.

Brazier Howell (1930) observes that " in the whalebone whales (at least in *Balaenoptera*) the anterior part of the bulla projects into a fossa the size of one's two fists and in freshly killed specimens this is entirely filled with a coarse foam of albuminous rather than greasy texture. . . . There is free communication between this fossa and the choanae. In the odontocetes there is a different but analogous system of air sinuses adjoining the middle ear, and connecting with an intricate labyrinth of ducts. Authors have been very vague and cautious about describing these ducts, and with good reason, for without the injection of a suitable coloured mass into this part of the freshly killed specimen their proper definition is utterly impossible as their finer ramifications are otherwise not to be distinguished from adjoining blood vessels and oil ducts. It must therefore suffice to say that this system of air sinuses communicates with the choanae and apparently sends trabeculated branches rami-

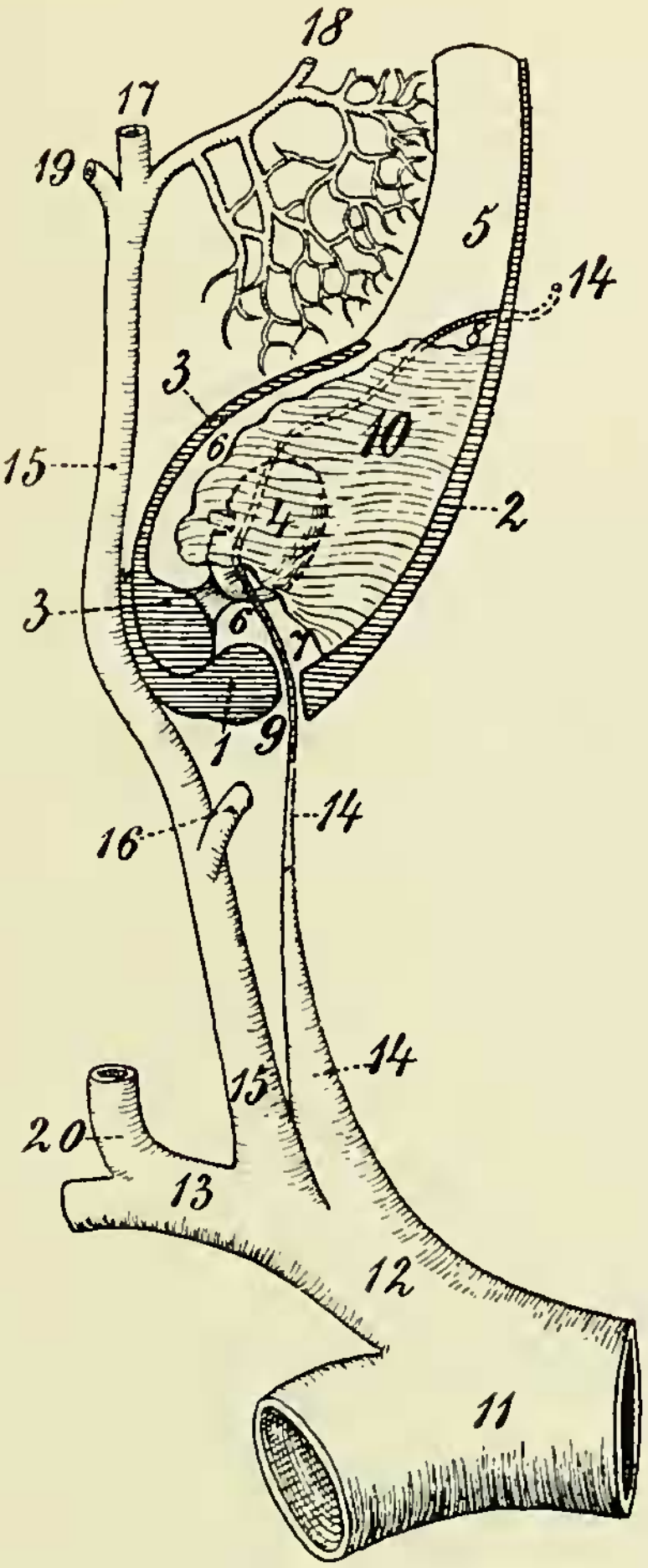

FIG. 1. Boenninghaus' (1903) figure of the course of the internal carotid artery, right side ventral view, of *Phocaena*, 116 cm. long.

1. Paroccipital process. 2. Basioccipital. 3. Tympanic bulla. 4. Periotic. 5. Eustachian tube (= Boenninghaus' vestibulum pneumaticum). 6. Tympanic cavity. 7. Posterior aperture of the tympanic cavity. 8. Anterior entrance of the same. 9. Paroccipital notch. 10. Corpus cavernosum. 11. Aortic arch. 12. Innominate artery. 13. Subclavian artery. 14. Internal carotid artery. 15. External carotid artery. 16. External maxillary artery. 17. Internal maxillary artery. 18. Pterygopalatine artery (or plexus). 19. Deep temporal artery. 20. Occipital artery.

fying through the peculiar fatty tissue that occurs in odontocetes within the angle of the lower jaw."

Anthony & Coupin (1930) appear to be the first to have described the air sacs of a ziphioid, *Mesoplodon bidens.* The extent of their observations is limited by lack of material. Comparison is made between the guttural pouch of various Perissodactyls and the Beaked Whales' air sacs. "In *Mesoplodon* the gutteral pouch consists of a large bag of which the two expansions, one superior and posterior (the smaller), and the other inferior and anterior, are lodged on the external face of the pterygoid bone."

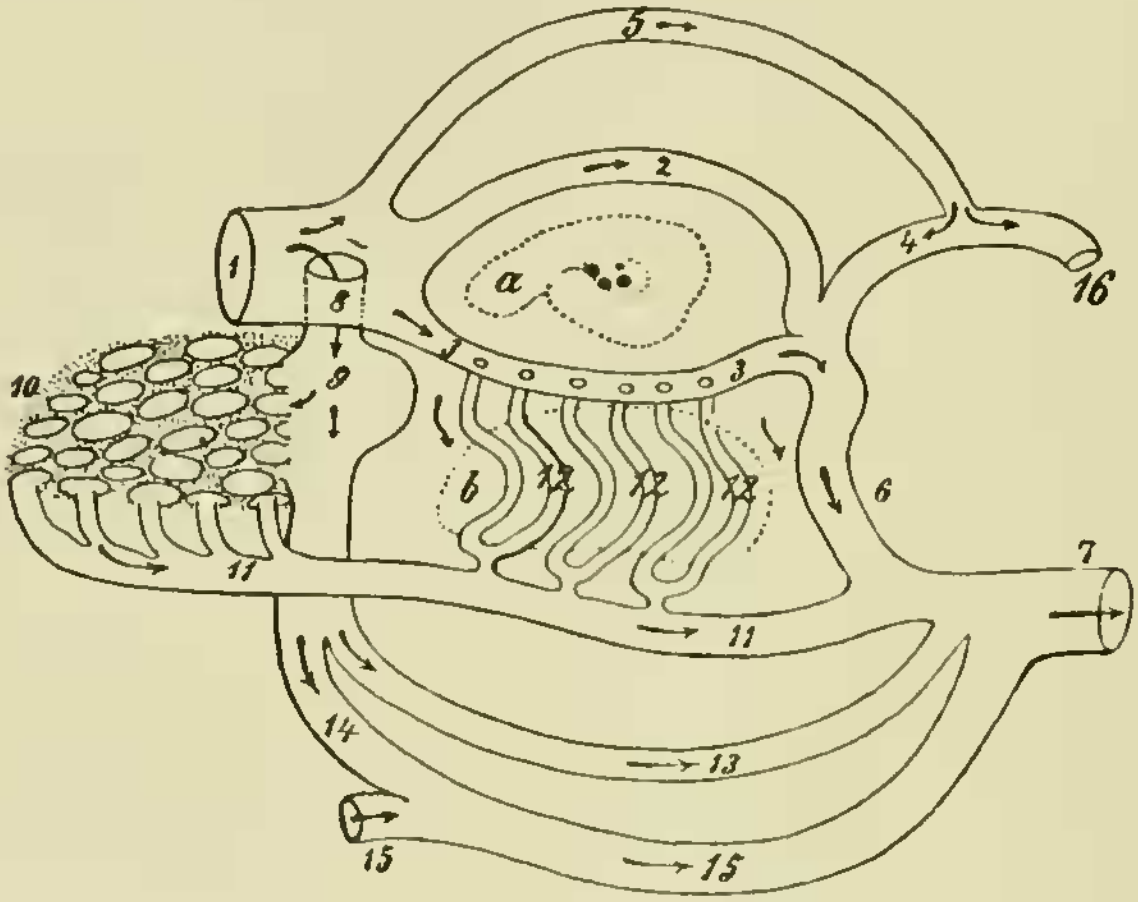

Fig. 2. Boenninghaus' (1903) figure of the venous drainage of the base of the cranium in *Phocaena.*

1. Cavernous sinus. 2. Superior petrosal sinus. 3. Inferior petrosal sinus. 4. Transverse sinus. 5. Longitudinal sinus. 6. Internal jugular vein. 7. Common jugular vein. 8. Emissary vein from the foramen lacerum medium. 9. Bulbous venosus epibularis of Boenninghaus. 10. Fibro-venous plexus of the pterygoid. 11. Pterygoid vein. 12. Corpus cavernosum. 13. Ramus bulbi venosi ad jugularem internam of Boenninghaus. 14. Ramus bulbi venosi ad jugularem externam of Boenninghaus. 15. External jugular vein of Boenninghaus. 16. Spinal venous plexus. *a.* Periotic, *b.* tympanic bulla.

Scholander (1940) in his classic paper on the respiratory function in diving animals and birds states "On the inner rear side of the lower jaw of the Bottlenose on each side, is an air recess, each with a maximal capacity of about 1 l. The recesses are in open connection with the nasal cavity and can be completely collapsed."

Finally Yamada (1953) figures, but does not describe in detail, the arrangement of air sacs in *Berardius bairdi* and *Kogia breviceps.*

The foregoing historical account of the structure of the accessory air sinuses in cetaceans is in general agreement with the writers' own finding, with certain reservations which will be discussed in the following sections.

BASICRANIAL ANATOMY

PTERYGOID AND NASOPHARYNGEAL MUSCLES

(1) DELPHINUS

In his dissections of *Phocaena phocoena* Boenninghaus described a supporting tissue of the skull base which is fully referred to on p. 12. The present writers have found that this tissue is present in all the odontocetes examined by them—*Phocaena phocoena, Lagenorhynchus albirostris, Globicephala melaena, Grampus griseus, Tursiops truncatus* and *Delphinus delphis*. A dissection of the last species is shown in Text-fig. 3. The "wide reticular, ventral membrane (PS) directed posteriorly towards and merging with the supporting tissue of the bulla" is more extensive than Boenninghaus suggests. In fact it constitutes the whole lateral wall of the air sinus system and its histology will be described in the next section. In Pl. 4A it will be seen that voluntary, striped muscle (MFS) is attached to the outermost layer of fibrous tissue (TF). This voluntary muscle is a small part of the pterygoid musculature now to be described.

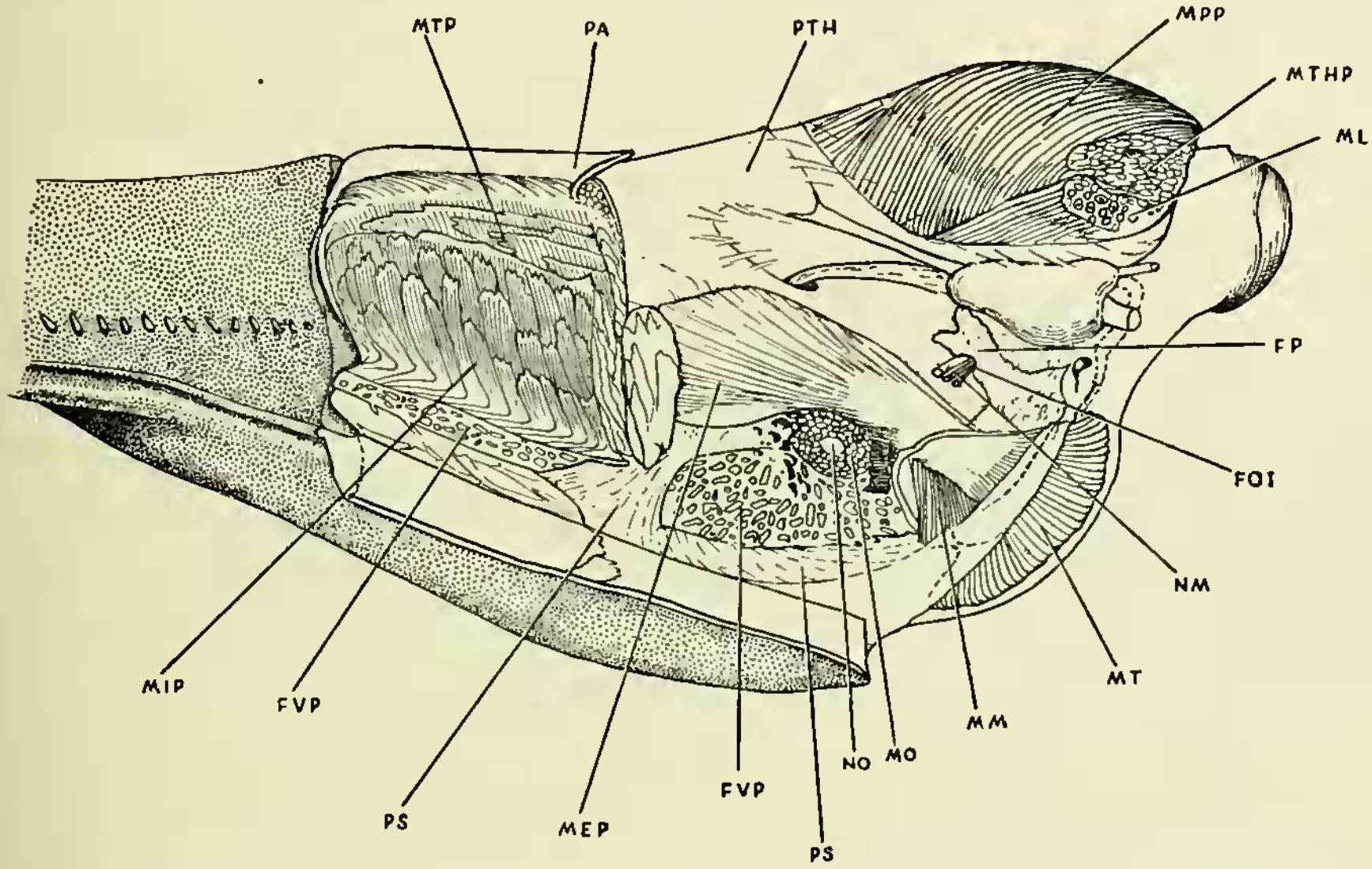

FIG. 3. Dissection of the right half of the head of *Delphinus delphis*, after removal of mandible and posterior part of palatal musculature, to show inter-relationship of muscles and periosteal sheet.

External pterygoid muscle. The external pterygoid muscle (MEP) in *Delphinus delphis* (Text-figs. 3 and 4) is similar in position and extent to that described by Boenninghaus for *Ph. phocoena* but in the former, attachments were observed which were not described by this author. As noted by him there is an attachment to the narrow dorsal edge of the posterior portion of the mandible (MD). In addition there is a more ventral attachment (VTEP) to the fibro-cartilaginous articulation of the lower jaw (MD), which is homologous with the insertion of the pterygoid muscle of man into the articular capsule. On its mesial aspect the muscle is attached at its anterior extremity to the lateral aspect of the tip of the posteriorly directed lateral lamina of the palatine bone, but its greater part on this aspect is attached to the fibrous external wall of the air sinus.

Internal pterygoid muscle. The present writers do not agree with Boenninghaus in his identification of the internal pterygoid muscle (MIP). The ventro-lateral muscle mass identified by him as the internal pterygoid is, in *D. delphis*, clearly divisible into two distinct portions separated by fascia. Only the more anterior portion has the attachments normally associated with the internal pterygoid muscle, namely—as in man—palatine, pterygoid, maxilla, and inner face of lower jaw. This muscle is attached to the ossified palatine bone and to membranous, unossified portions of the air sinus system in the neighbourhood of the other three bone elements. These membranous areas are derived from pterygoid, maxilla and mandible. The position of the internal pterygoid in relation to the external, is such that the qualifications used are misnomers. The internal pterygoid muscle is displaced anteriorly so that it lies entirely in front of, and not alongside, the external pterygoid. In man the internal pterygoid is described as a thick, quadrilateral muscle whereas in the

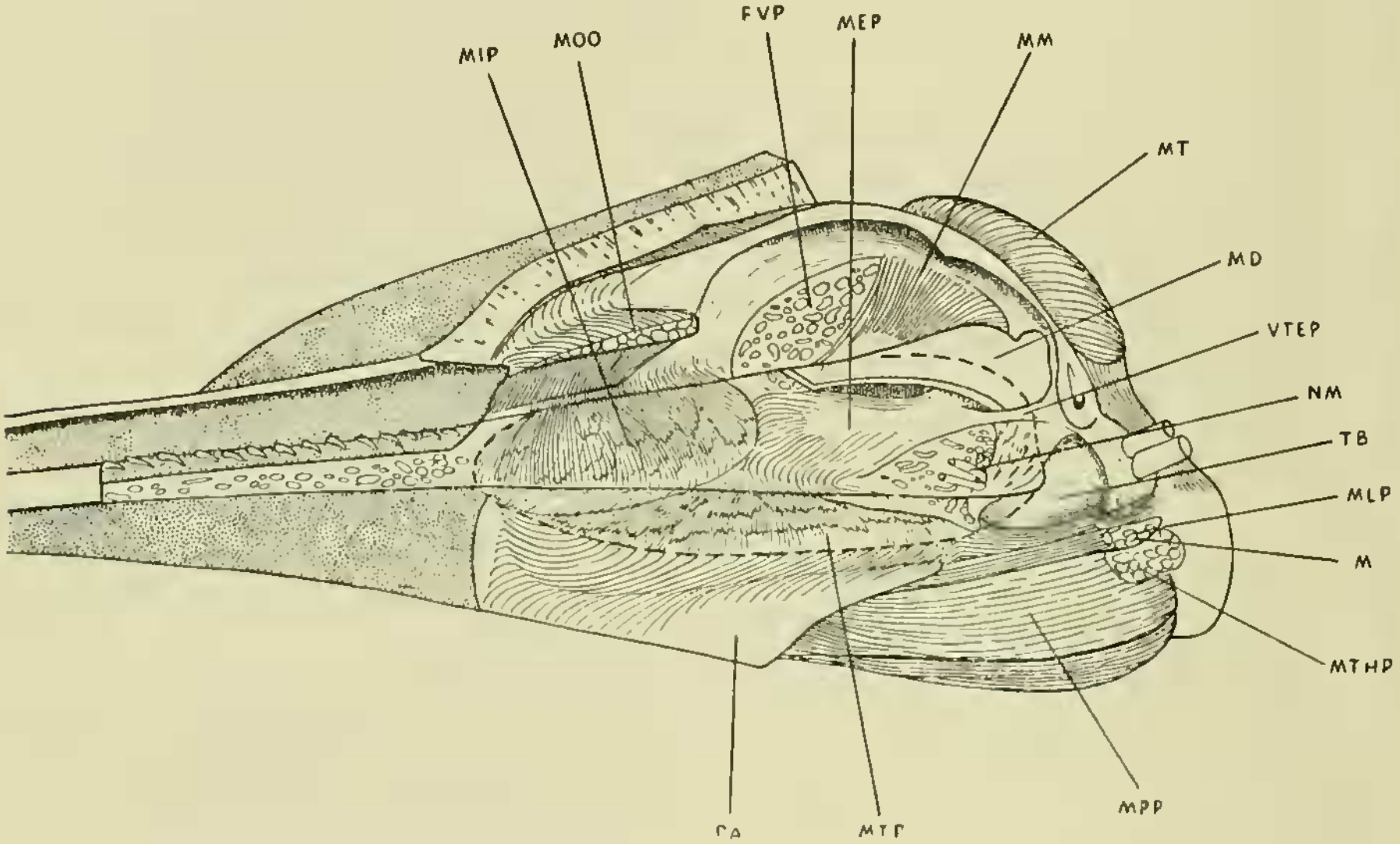

FIG. 4. Dissection of the left half of the head of *Delphinus delphis* to show interrelationships of palatal and pterygoid muscles. (Only the proximal end of the mandible is shown *in situ*, the remainder being indicated in outline.)

Common Dolphin it is elliptical in shape, the longer axis lying parallel to the long axis of the lower jaw.

Tensor palati muscle. The other portion of the ventro-lateral muscle mass referred to above is roughly of an acute angular shape, one side of the triangle lying along and overlapping the angular lateral edge of the pterygoid hamulus. Anteriorly it is attached along the whole posterior ventral margin of the palatine bone; posteriorly to the lateral wall of the Eustachian tube and to the styloid near its junction with the tympanic bulla. Along the ventro-lateral edge of the pterygoid hamulus its muscle fibres run antero-mesially and merge into a strong, fibrous, glistening aponeurosis (PA) which covers the ventral surface of the palate and merges with the muscle of the opposite side. According to Boenninghaus, Zucherhandl wrongly identified this muscle as the tensor palati, but the present writers consider the latter author to be right (see p. 11). In *Delphinus delphis* the part of the mesial aspect of this muscle (MTP) is attached to the lateral wall of the pterygoid air sac posterior to the posterior margin of the lateral lamina of the pterygoid hamulus, whereas in *Mesoplodon bidens* the fascia of this muscle forms nearly the whole of the lateral wall of the pterygoid sac.

Between the postero-dorsal margin of this muscle and the postero-ventral margin of the external pterygoid muscle is a triangular space closed mesially by the fibrous supporting tissue previously mentioned, and pierced by the tensor palati and pterygoid branches of the mandibular nerve (NM).

According to Boenninghaus the tensor palati muscle is restricted to a few, small, inconspicuous, vestigial muscle fibres in the posterior nares close to the opening of the Eustachian tube. It may be pointed out that the muscle identified by the present writers and Zucherhandl as the tensor palati is innervated by a branch of the mandibular nerve, i.e. the conventional innervation of this muscle. The tensor palati of Boenninghaus is remote from this nerve and separated from it by the lateral wall of the posterior nares, the pterygoid air space and the lateral muscle mass.

Temporal muscle. Consideration of the temporal muscle (MT) is not within the scope of the present investigation. It need merely be said that it originates in the temporal fossa and passes through that portion of the zygomatic arch formed by the squamosal, to an insertion on the dorsal edge of the mandible posteriorly. Closely associated with, and situated ventrally to this muscle is another muscle mass which originates from the fibrous covering of the tympano-squamosal recess on the zygomatic process of the squamosal. It is inserted into the lateral face of the mandible and in its general position its identification as the masseter muscle (MM) seems reasonable.

Nasopharyngeal muscles. In order to demonstrate the manner in which the air sinus system has profoundly altered the arrangement of the muscles of the soft palate, it is necessary to review the inter-relationship of the components of the naso-pharyngeal muscle mass using *Delphinus delphis* (Text-figs. 3–6) as the subject. But before doing so it is well to recall the disposition in a typical mammal, for example man. According to Gray's *Anatomy* (1946) " the palatine aponeurosis (tendon of the tensor palati) forms a central sheet enclosing the uvular muscles near the median plane; the levator palati and the palato-pharyngeus are inserted into its upper surface, the two strands of the latter muscle lying in the same plane respectively in front of and behind the levator palati." In Cetaceans, the dorsal and ventral surfaces of the palatine aponeurosis are widely separated by the expanded and distended hamular portions of the pterygoid bones and their associated air sinuses and venous plexuses (FVP). Thus in their narial portions the palato-pharyngeus and levator palati muscles (MPP) are separated from the ventral aspect of the palatine aponeurosis by the interval formed by the pterygoid air spaces. As a result of the development of these air spaces and the modifications of the pterygoid bones enclosing them, profound alterations of the conventional orientation of the naso-pharyngeal muscles have ensued. The "soft palate" is invaded by the pterygoid bones and is thus no longer soft, and the palato-pharyngeal muscle mass is largely enclosed within the bony nares (see Text-fig. 14*g*). The arrangement of this muscle mass in *Delphinus delphis* is almost identical with that so adequately described by Boenninghaus in *Phocaena phocoena* (see p. 11). Thus the partes interna and externa of the palato-pharyngeus muscles (MPP(I)) (MPP(E)) form the greater part of the thick mass of tissue which covers the anterior wall and floor of the posterior narial aperture, whilst the constrictor pharyngeus (MSC), salpingo-pharyngeus (MSP) and longitudinalis oesophagi (MLO) form the posterior portion of its roof. The ventral extremities of all these muscles encircle the glottis in a powerful palato-pharyngeal sphincter (MPP (S)).

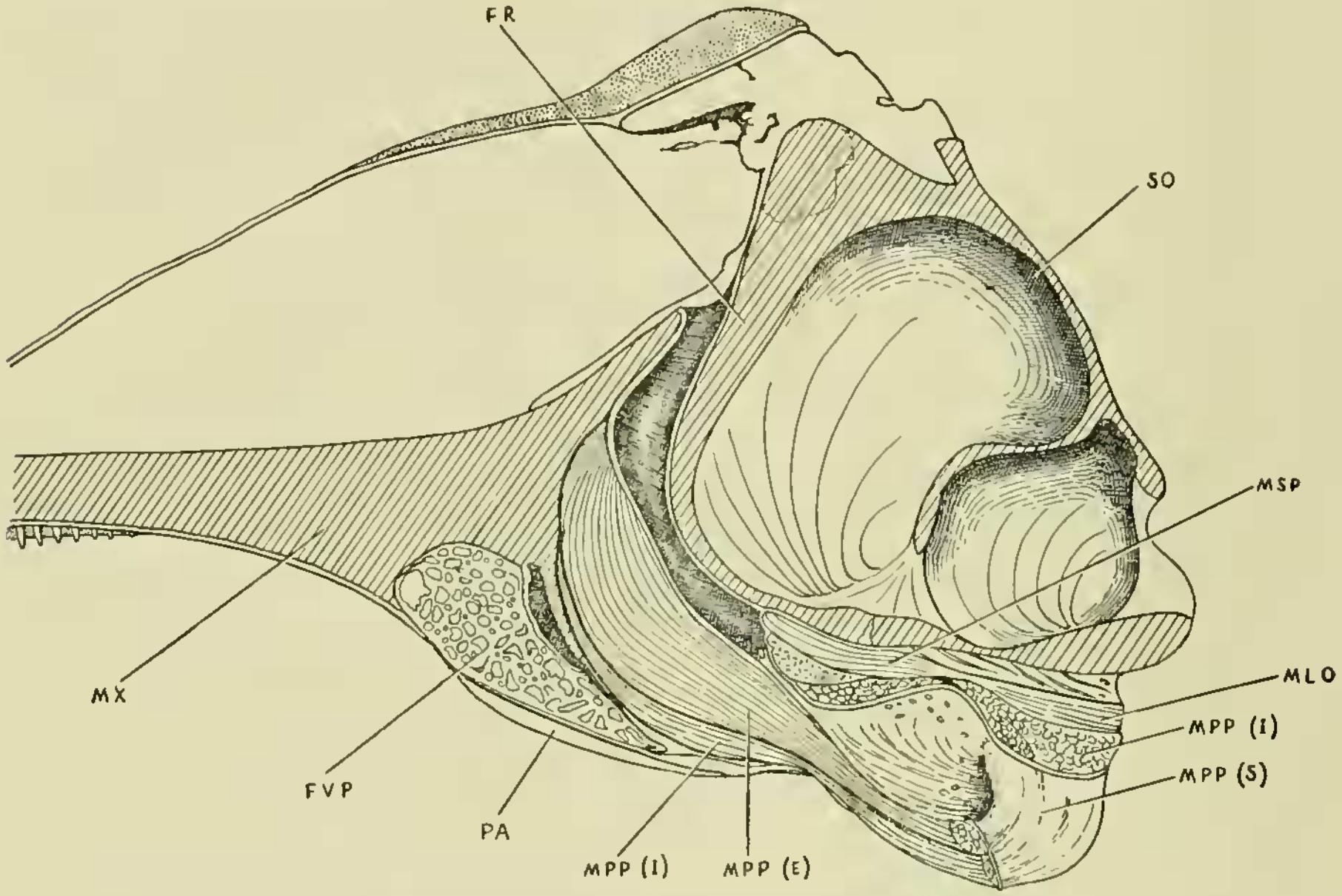

FIG. 5. Bisected head of *Delphinus delphis*, right side, showing naso-pharyngeal muscle mass *in situ*.

In Text-fig. 6. the whole palato-pharyngeal muscle mass has been removed from the nares to show that the individual muscles overlap in a manner similar to their arrangement in terrestrial mammals. The present writers, however, do not concur with Boenninghaus in his identification of the levator palati muscle, and consider that the muscle he so identified is merely a portion of the *pars interna* of the palato-pharyngeus. Indeed, Boenninghaus himself found it difficult to establish a differentiation of the two muscles. In *Delphinus delphis* (Text-figs. 4 and 6) there is a muscle (MLP) which arises from the junction of the styloid with the tympanic bulla, lies along the medial wall of the Eustachian tube, and after passing within the upper, concave border of the superior constrictor, runs dorsally between the partes interna and externa of the palato-pharyngeus ; thereafter it spreads out into the palatine glandular surface near the narial opening of the Eustachian tube. This

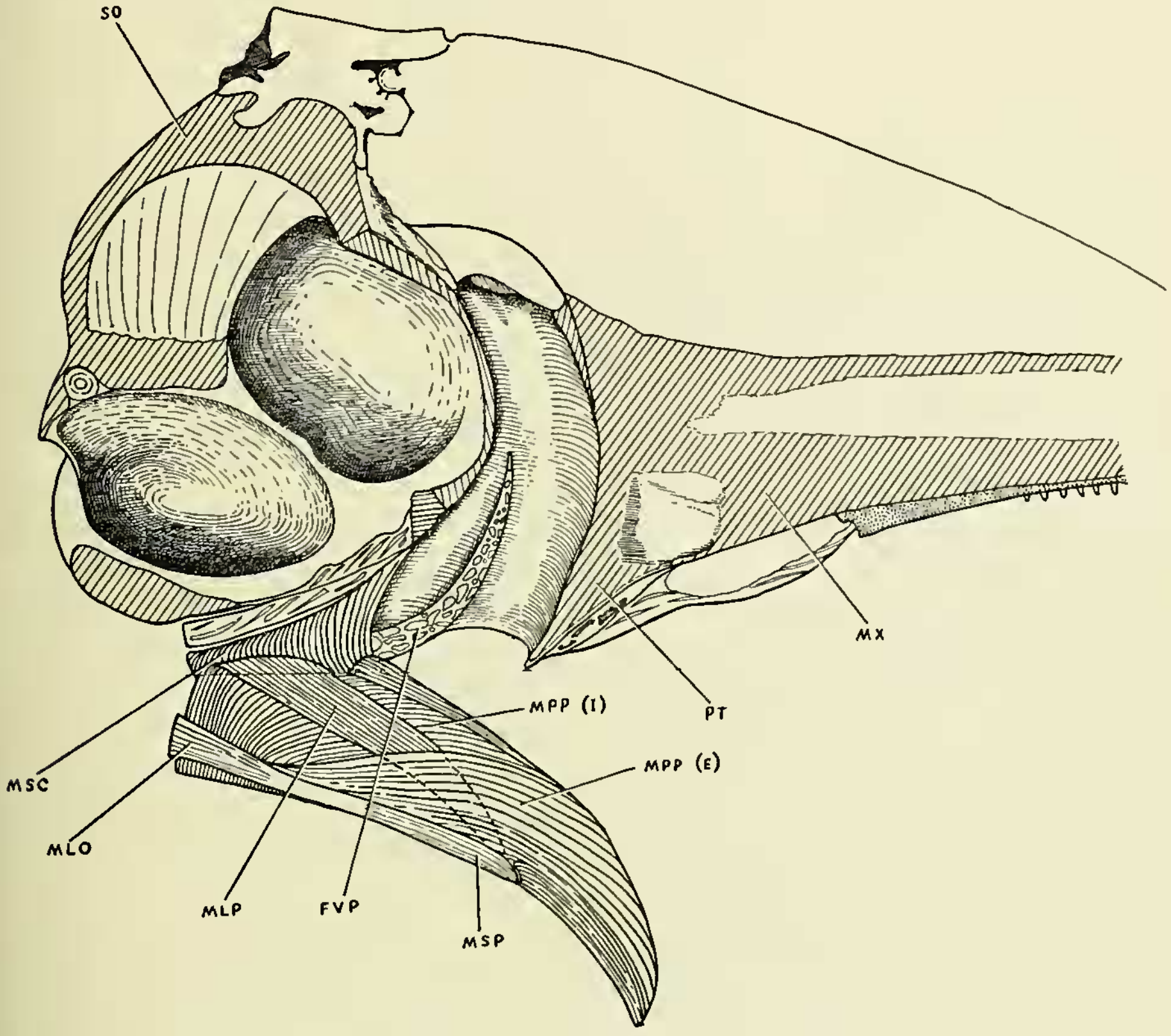

Fig. 6. Bisected head of *Delphinus delphis* left side, with naso-pharyngeal muscle mass reflected.

disposition of the muscle coincides in all its relationships with that identifying the levator palati in man.

(2) MESOPLODON

In the Ziphiidae the size and disposition of the lateral muscle mass are correlated with the enormously enlarged pterygoid hamuli (see Text-fig. 14*c*). It will be seen later that the air sinus system is almost wholly confined to this region, thus whilst the tensor palati muscle is expanded in correspondence with the enlargement of the hamuli, the expansion of each hamulus has apparently been at the expense of the remaining portion of the pterygoid, which is reduced to a long, narrow shelf, situated immediately above the hamular fossa. The "external" and "internal" pterygoid muscles extend from the upper surface of this shelf to the dorsal edge of the mandible and are consequently restricted to the narrow interval which separates these two attachments. The muscles are also flattened dorso-ventrally and in general are very much reduced in size, and presumably in function, compared with those of the Delphinidae. The temporal fossa, and with it the temporal muscle, is also reduced in size as compared with those of the Delphinidae.

(3) BALAENOPTERA

In order to complete the description of the musculature of the air sinus system, it is necessary to describe the arrangement in the baleen whales. Before doing so it may be noted that Beauregard (1894) identified in *Balaenoptera acutorostrata* a sheet of fibrous tissue covering the lower surface of the cranium, and closing the pterygoid sinus ventrally. This sheet is undoubtedly homologous with that described above (p. 12) in the Odontoceti.

With regard to the lateral muscle mass the writers have little to add to the description provided by Carte & Macalister (1869). They state "the pterygoid muscle was small and flat ; it arose fleshy from the external surface of the pterygoid plate, which formed the outer wall of the posterior nares ; the muscle ran downwards and backwards, and was inserted into the internal border of the lower jaw near its angle, sending some of the posterior fibres to be inserted into the interarticular fibro-cartilage. This muscle was evidently the representative of the external pterygoid ; no muscle corresponding to the internal pterygoid was found." In a dissection of a foetal fin whale the present writers were similarly unable to distinguish positively the internal pterygoid, but a small slip of muscle inserted into the mesial aspect of the lower jaw, approximately at the level of the coronoid process, appeared to have its origin in the lower part of the temporal fossa near or on the pterygoid bone. Its position relative to the lateral pterygoid suggested that it might be the internal pterygoid muscle.

The arrangement of the muscles in the naso-pharyngeal mass is precisely as in the Odontoceti except that the muscles are not enclosed within the bony nares (see Text-fig. 14*b*). This is related to the fact that the pterygoid hamuli do not extend towards the middle line and are not enormously enlarged as in the Odontoceti, a true soft palate persisting. It will be seen, from Carte & Macalister's description of the deep fibres of the masseter muscle which follows, that this muscle agrees in position and attachments with that tentatively so identified in *D. delphis* (p. 19 *supra*). They state " The deeper set of fibres arose tendinous from the margin of the glenoid cavity, extending as far forward as the posterior edge of the orbit ; the fibres of this plane ran downwards and a little forwards, and were inserted into the base of the lower jaw about three inches in front of its angle, and occupied by its insertion about three inches of the outer surface of this bone."

VASCULAR SYSTEM

The modification from the conventional arrangement of soft structures at the skull base with the development of air sinuses is particularly well demonstrated by the distribution of the blood vessels in this region. Anatomists such as Murie, Boenninghaus, Carte & Macalister have, with justification, described the blood vessels only in very general terms, because the ramifications of the finer branches are exceedingly complex and form extensive retia mirabilia which are associated with the air spaces. In order to relate their investigations with those of previous authors the present writers examined the vascular systems of five species of odontocete. Use was made of the recently developed polyester resins in order to obviate the necessity of making very laborious and less satisfactory dissections. The arterial and venous systems were injected with coloured plastic through the common carotid artery and jugular vein respectively. Freshly killed animals being unavailable, use was made of stranded specimens, the venous system of which naturally contained varying amounts of congealed blood. As a consequence the injection of this system was in some instances not complete, but sufficient information has been obtained by considering the injected specimens together to build up a composite impression. This impression is possible because inspection of the preparations of the heads of the five species injected, namely *Phocaena phocoena*, *Grampus griseus* (Text-fig. 7), *Tursiops truncatus* (Text-fig. 8), *Globicephala melaena* (frontispiece and Text-fig. 9) and *Lagenorhynchus albirostris* (Text-fig. 10) showed that the vascular system as a whole was very similar in each.

The general impression of the vascular system in the region of the base of the skull is of an elaborate plexus of vessels investing the whole of the air sac system, and apparently entirely subservient to the proper functioning of the latter. It is well known that the blood supply to the brain of cetaceans is by way of spinal meningeal arteries which are greatly increased in calibre and, correspondingly, the internal carotid is known to be reduced and apparently atrophied.

ARTERIAL SUPPLY

The external carotid (ACE) (Text-fig. 8) divides in the neighbourhood of the tympanic bulla into an external and internal maxillary artery, the former of these being irrelevant to the subject of this paper. The internal maxillary (AMI, Text-figs. 7, 8, 9, 10) can be referred to under the three sub-divisions recognized in terrestrial mammals.

The first part forms a sinuous curve and is enveloped in the superior portion of the intra-mandibular fatty tissue (IMFB); laterally it gives off the mandibular artery (AM) (Text-figs. 7, 8, 9) which is distributed to the ramus of the lower jaw.

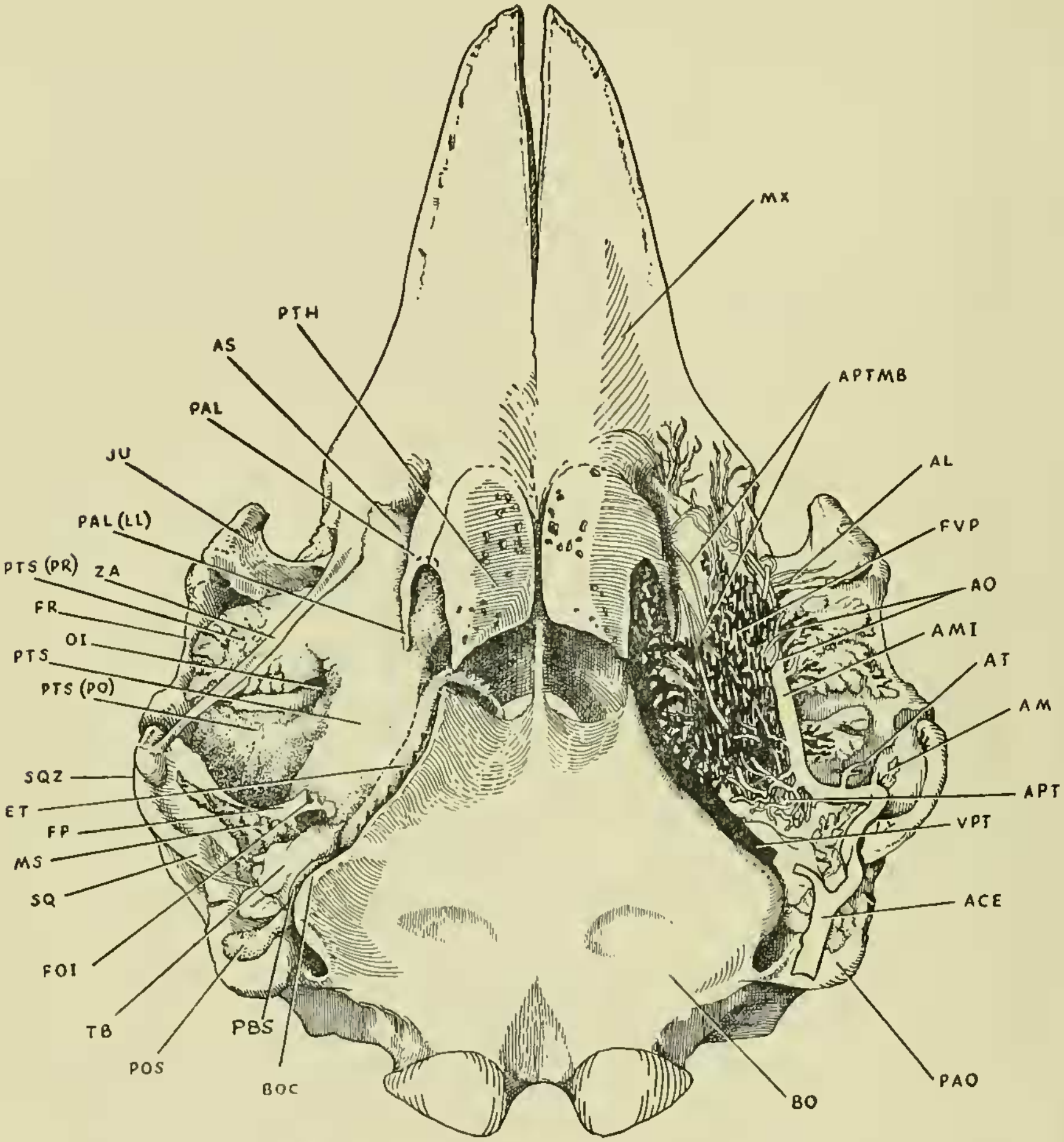

FIG. 7. *Grampus griseus.* Ventral aspect of the head showing distribution of air sinuses, arteries and veins.

Further forward it gives off, mesially, pterygoid arteries (APT) and laterally the deep temporal (AT) (Text-figs. 7, 8). The pterygoid arteries form a rich plexus of vessels which is distributed to the submucosa of the air sacs as well as to the external pterygoid and tensor and levator palati muscles. The plexus communicates

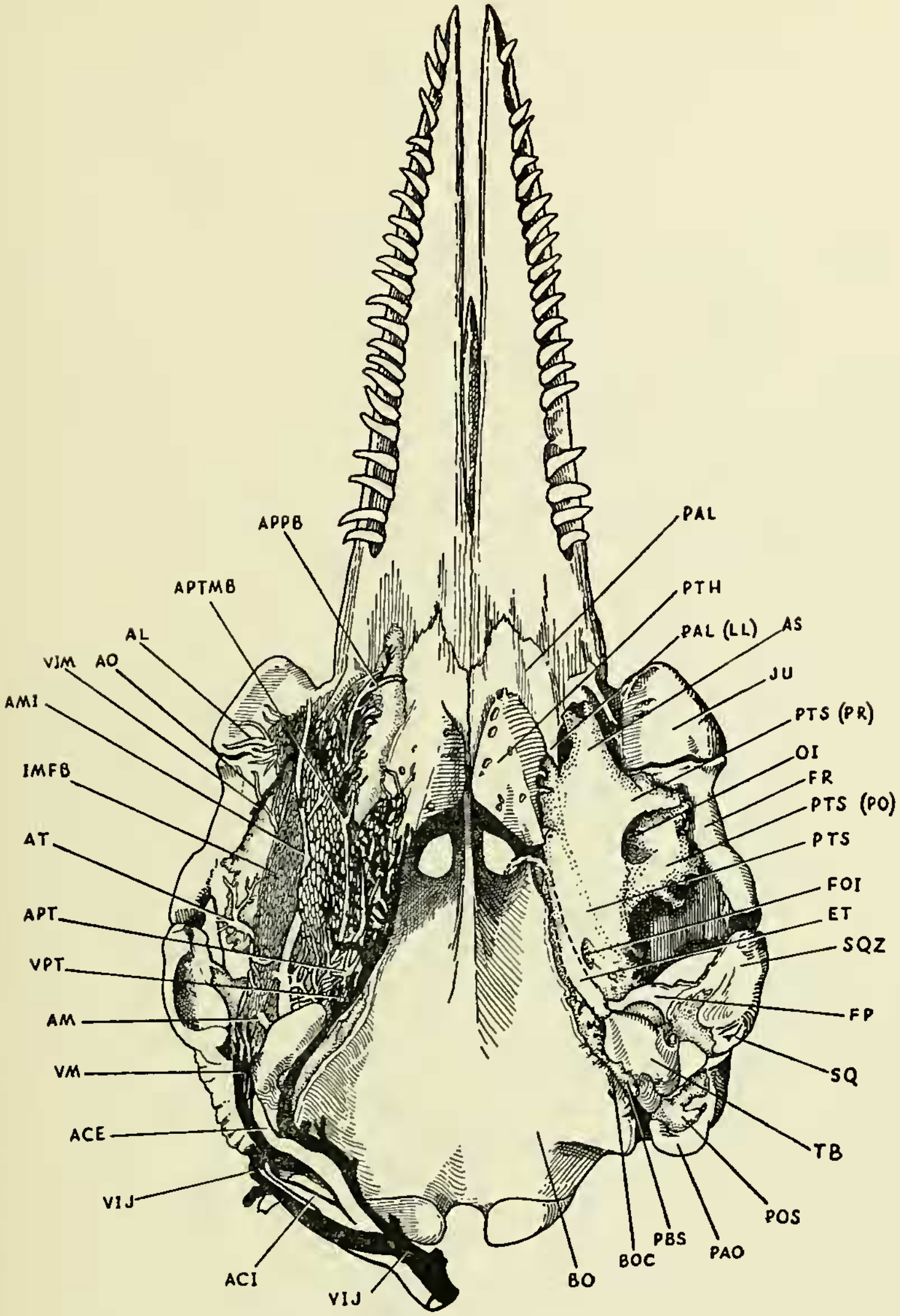

FIG. 8. *Tursiops truncatus*. Ventral aspect of the head showing distribution of air sinuses, arteries and veins.

with the vascular envelope of the air sac system in the position of the angle formed by the tensor palati and lateral pterygoid muscles. The arteries supplying the internal pterygoid muscle (Text-figs. 7, 8, 9, 10, APTMB), although originating in approximately the same position as those supplying the external pterygoid, extend forward on a course approximately parallel with that of the parent (internal maxillary) vessel in conformity with the forward displacement of the internal pterygoid muscle (see p. 18).

In terrestrial mammals the middle meningeal artery is a conspicuous branch of the first portion of the internal maxillary, and anastomoses with the internal carotid. In at least one of the injected specimens evidence of an intra-cranial blood supply from this source has been established ; and it cannot be assumed that this artery has atrophied, notwithstanding the apparent atrophy of the internal carotid and the proliferation of the spinal meningeal supply.

The second part is not enclosed within any alisphenoid canal and indeed it is displaced from the lateral wall of the cranium by the whole width of the pterygoid air sinus. The vessels (AO and AL) stemming from this portion of the internal maxillary go to supply the orbital muscles, the lachrymal gland and upper eyelid (Text-figs. 7, 8, 9) ; their distribution is not relevant to the present paper but it may be noted that a considerable extent of main vessel separates the origins of the orbital and lachrymal branches.

The third part commences immediately anteriorly to the lachrymal branch (AL) of the Second Part (Text-fig. 9). It immediately turns mesially and dorsally to pass through the infra-orbital foramen. Before doing so it gives off vessels, which penetrate the palatine base (Text-figs. 8, 9, APPB) presumably to supply the palato-pharyngeal muscle mass, and the roof of the mouth. Another branch ramifies on the ventro-lateral surface of the rostrum (Text-figs. 7, 9). The maxillary artery passes forward within the rostrum after giving off branches to the nasal cavity and the musculature of the blowhole. It is interesting to note that, as in the orbital region where the cranial foramina are crowded together, in the preorbital region the infra-orbital, spheno-palatine and posterior palatine foramina are all in juxtaposition.

VENOUS DRAINAGE

The venous drainage of the base of the skull is extremely complex and anastomoses freely with that of the cranial cavity. It is mainly characterized by the development of an extensive fibro-venous plexus which lines the whole of the lateral and mesial walls of the air sinuses. In spite of the profusion of retia, however, certain conventional features of the venous drainage can be recognized.

Internal maxillary vein. This vein (Text-fig. 8, VIM) can be said to commence at the posterior extremity of the zygomatic arch and pass forward parallel with the latter as far as the posterior margin of the jugal. It then passes over the dorsal edge of the ramus of the mandible and runs posteriorly in company with the artery (AMI) of the same name. In the temporal region it merges with the massive venous plexus of the intra-mandibular fatty body (IMFB), and is joined by the deep temporal vein.

Mandibular vein. Boenninghaus' identification of the intra-mandibular fatty body with the bone marrow of the lower jaw seems to be justified. A full description of its situation and extensions is given on p. 13. The venous plexus which ramifies extensively in the fatty body ultimately drains into a large vessel which can be recognized as the mandibular vein (Text-figs. 8, 9, 10, VM). The plexus consists primarily of a network of vessels of small calibre, the walls of which are extremely

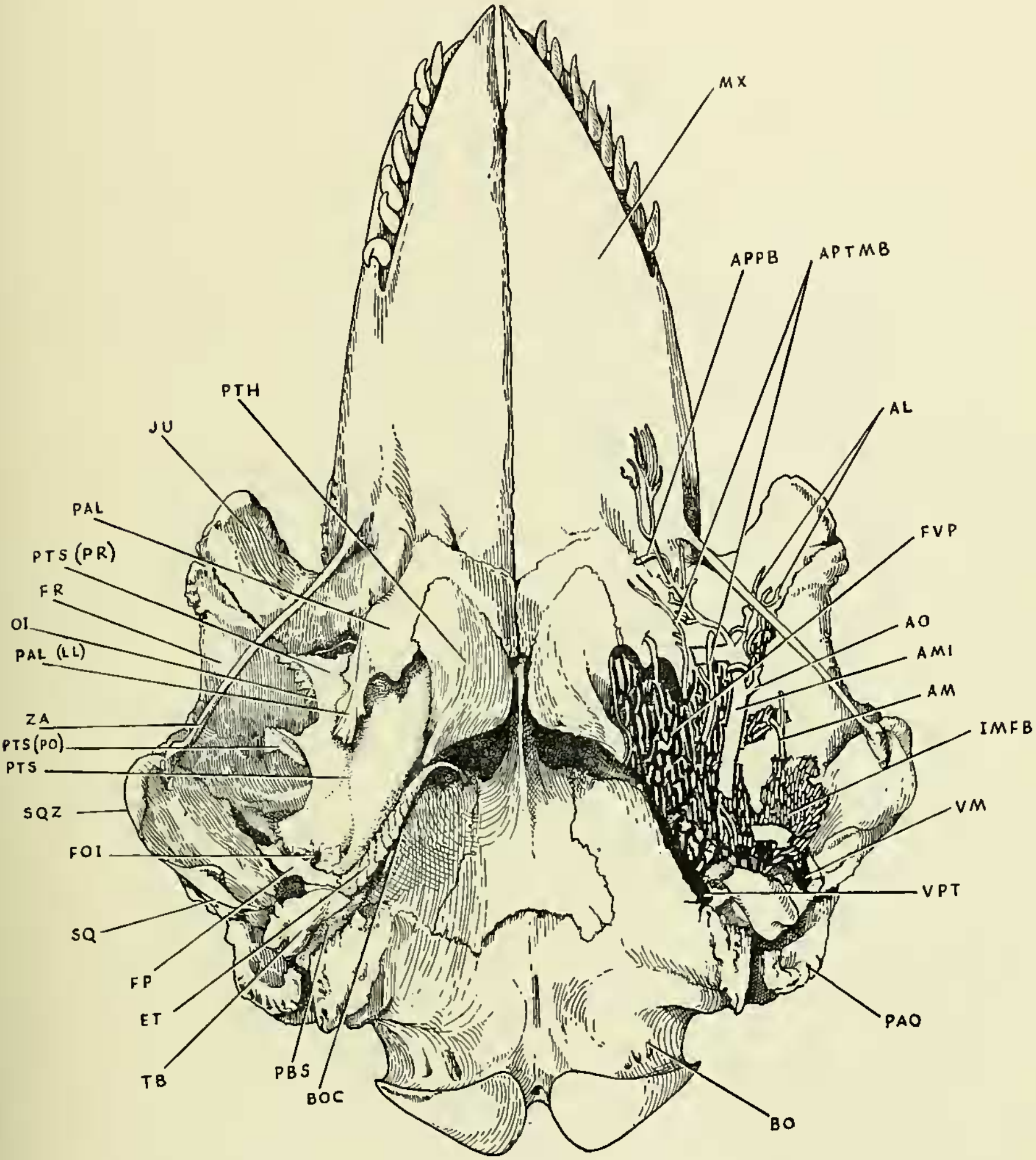

FIG. 9. *Globicephala melaena.* Ventral aspect of the head showing distribution of air sinuses, arteries and veins.

thin and intimately associated with the adipose tissue of the marrow. Boenninghaus points out the tendency of the fatty body to hypertrophy beyond the natural boundaries of the mandible, and it is a significant fact that among the toothed cetaceans, even those with a reduced number of teeth, for example *Grampus griseus*,

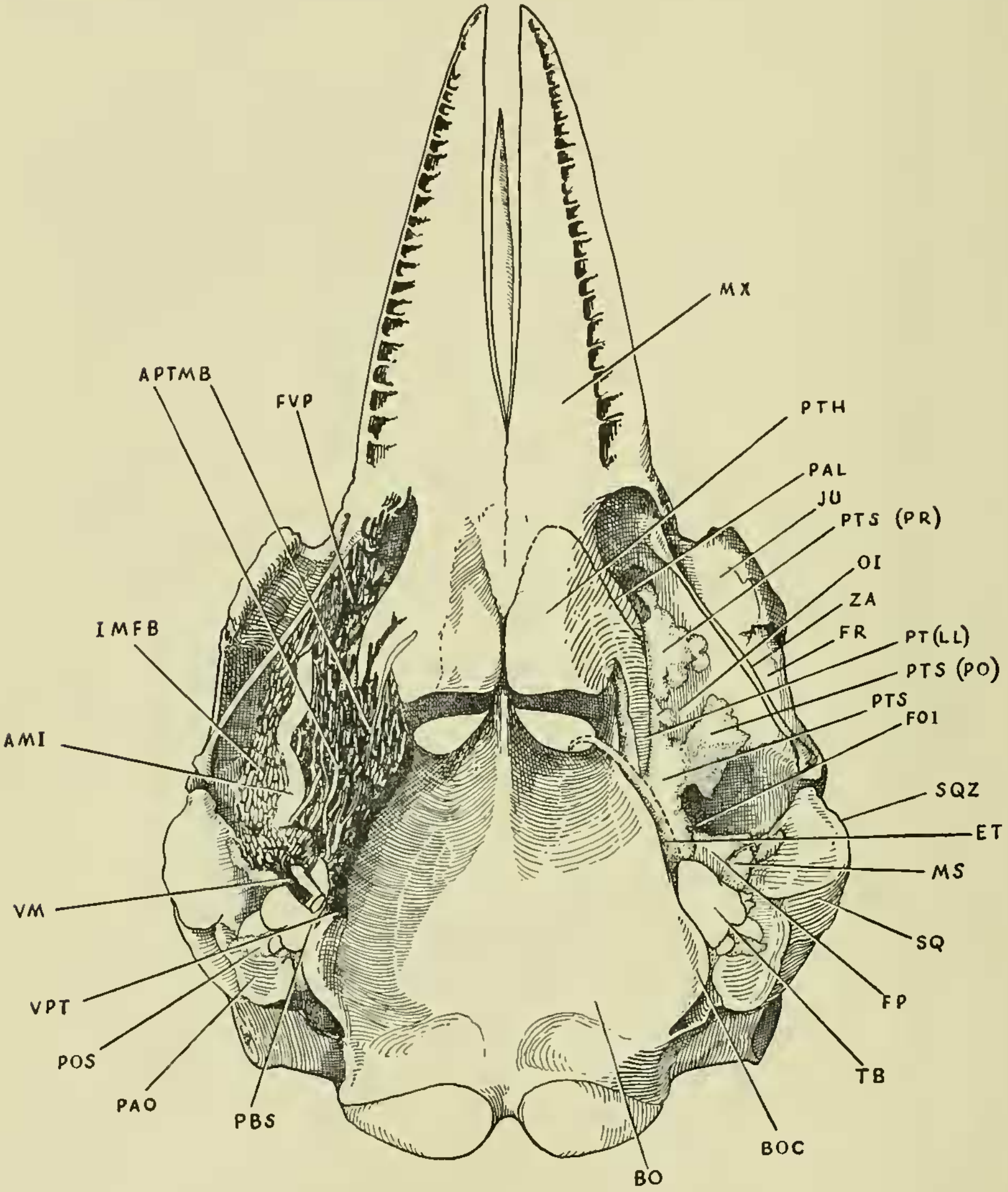

FIG. 10. *Lagenorhynchus albirostris.* Ventral aspect of the head showing distribution of air sinuses, arteries and veins.

have a greatly enlarged fatty body. The large size of the mandibular vein can be correlated with that of the large plexus it drains. It continues posteriorly beyond the postero-lateral border of the skull to join the internal jugular (VIJ).

Internal jugular vein. Like the internal carotid artery the internal jugular vein (Text-fig. 8) is short, sharply tapered and presumably reduced in function. It emerges from the paroccipital notch and accompanies the internal carotid artery posteriorly.

Pterygoid vein. Unlike that of terrestrial mammals the pterygoid vein (Text-, figs. 7, 8, 9, 10, VPT) in the Cetacea is not limited to the drainage of the pterygoidea. It is continuous with the great fibro-venous plexus of the air sacs so that its ramifications are co-extensive with the distribution of the sacs themselves. Thus there are portions of this plexus to be found in the post-orbital, orbital and pre-orbital regions of the head and in some species, e.g. *Delphinus delphis*, the plexus extends towards the tip of the rostrum. On the mesial aspect of the cranial portions of the air sac system the fibro-venous plexus communicates freely with extensions from the intracranial venous system, through the optic foramen, and by way of the cavernous, superior and inferior petrosal sinuses. As a result of the displacement of the tympano-periotic from participation in the wall of the cranium, the petrosal and cavernous sinuses are divested of their bony cranial protection and are anastomosed with the fibro-venous plexus (but see *Caperea* pp. 77–79). In the terrestrial mammals the internal carotid artery passes through the cavernous sinus within the cranial cavity. In the Cetacea it passes through the so-called cavernous tissue body within the tympanic cavity. It seems therefore that the problematical cavernous tissue body or spongy mass of Beauregard in the cetacean ear is the homologue of the cavernous sinus of terrestrial mammals. At the angle made by the tensor palati and lateral pterygoid muscles, the lateral portion of the fibro-venous plexus anastomoses extensively with the plexus of the intra-mandibular fatty body. The pterygoid vein passes posteriorly along the ventral margin of the basioccipital crest (BOC) and, according to Boenninghaus, at the level of the tympanic bulla (TB) is joined by small tributaries from the inferior petrosal sinus. Still further posteriorly it unites with the mandibular and internal jugular veins.

The schematic representation of the venous system described by Boenninghaus and reproduced in Text-fig. 2 agrees in the main with the arrangement found in the more recently injected specimens figured in the present paper. There are, however, certain modifications which are embodied in the diagram. Thus the vessel labelled " internal jugular " (6) is shown with a relatively wide lumen, whereas the injected specimens show that it is very attenuated at its cranial end (see Text-fig. 8). The vessel labelled " external jugular " (15) lies on the mesial side of the mandible and is more properly designated as the mandibular vein. As previously stated it is embedded in the plexus of the intra-mandibular fatty body. The vessel labelled " ramus bulbi venosi ad jugularem externam " (14) in the injected specimens consists of a mass of small vessels connecting the vascular plexus of the fatty tissue body to the " corpus fibro-cavernosum pterygoideum " (10) i.e. the fibro-venous plexus of the air sacs. No vessel corresponding to the " ramus bulbi-venosi ad jugularem internam " (13) could be found unless it be the deep temporal vein in which case it is not in direct communication with the fibro-venous plexus, since it drains the temporal muscle.

At the points of attachment of the pterygoid muscles to the walls of the air sacs. the vessels of the fibro-venous plexus are much smaller than those in areas where no muscles are attached.

No detailed dissection was made of the nervous system in the region involving the air sacs, but it might be expected that since the air sac system covers the ventro-lateral aspect of part of the cranium the air sacs would be penetrated by the cranial nerves in this region. However, the paths of the nerves concerned are restricted to three exits, that associated with the optic infundibulum, that of the infundibulum of the foramen ovale and that of the "cranial hiatus" in the vicinity of the periotic.

CONTENTS OF THE AIR SACS AND HISTOLOGY

Foam

With reference to the contents of the pterygoid fossa, Brazier Howell (1930) writes "in freshly killed specimens this is entirely filled with a coarse foam of albuminous, rather than greasy texture. Whether this is so in living specimens cannot be demonstrated, but presumably it is, and the foam may have some function in determining the quality of sound reception."

One of us (P.E.P.) examined the pterygoid sinuses of approximately fifty pilot whales stranded at Dunbar (1950) and found that each one contained a similar type of foam.

Mr. D. E. Sergeant of the Newfoundland Fisheries Research Station, who had been asked to look out for this phenomenon, also noted its occurrence in a *Globicephala melaena* only 1½ hrs. after death.

Dr. R. M. Laws, National Institute of Oceanography, to whom a similar request had been made, reported that in no whale examined for this purpose was the foam lacking.

Dr. Robert Clarke of the same Institute, while at the Azores in 1955 examined a number of Sperm Whales in which foam was found to fill the pterygoid air sacs.

Histology

If the surface of the wall of the air sac is examined with the naked eye it is seen to be of a light brown colour and matt texture. This texture is the macroscopic expression of the presence of the openings of innumerable, minute ducts closely adjacent to one another with a separating, membranous network, the trabeculae of which are ca. 0·025 mm wide. Pl. 2, fig. A, shows a section cut in the plane of the surface of the mucous membrane. The ducts (DMU) are fairly uniform in size, their openings of a roughly oval shape and measuring approximately 0·2 mm at their widest diameter. In the thick part of the same section each duct is filled by a layer of inwardly projecting columnar cells (ECO), mucus and foreign particles. The longitudinal section (Pl. 2, fig. B) of the pterygoid sac lateral wall shows that these ducts communicate with an elaborate system of mucous glands (GMU) some simple, some racemose, some deeper than others. The glands are lined by a thick layer of columnar epithelium with goblet cells (Pl. 2, fig. C, GOC). The free surface of the interglandular areas of the mucous membrane is covered by ciliated epithelium (ECI). The whole glandular area is extremely vascular being equipped with an intricate network of capillaries and larger vessels.

The mucous membrane (MUM) is supported by a thick layer of fibrous tissue (Pl. 3, fig. A, TF) with here and there small clusters of fat cells (Pl. 3, fig. C, CF). The fibrous layer may also contain elastic tissue. Disposed at random throughout the tissue are circular spaces of small size, each bounded by a fine layer of brown, unstainable substance (Pl. 3, fig. C, FG), which presumably represent fat globules. A number of larger irregularly shaped spaces (Pl. 3, fig. B, LS) contain a filling of translucent, emulsoid texture (Pl. 3, fig. D).

Deep to the fibrous layer is an open network of large venous spaces (FVP) with interspersed arteries (A), and connected by strands of fibrous tissue (TF) and patches of fatty tissue (FT) (Pl. 3, fig. A). The boundaries of the venous spaces appear to be composed of the interlaced fibrous strands, no well-defined endothelium being present.

Another fibrous layer TF lies deep to the vascular plexus, attached to which can be seen many striped muscle fibres (MFS) (Pl. 3, fig. A) parallel with and closely adherent to the last named fibrous layer. In Plate 4, fig. A which is at right angles to the previous one a much larger area of this striped muscle (MFS) can be seen in transverse section, the peripheral regions of the individual muscle bundles being separated by fasciae originating from the fibrous layer (TF). The muscle involved is the external pterygoid.

The mucous membrane lining the mesial wall of the air sinus is identical in structure with that of the lateral wall. The photomicrograph of the sections (Pl. 3, fig. B) shows the membrane and its underlying structures. The crypts are rather more racemose than those of the lateral wall and, as in the latter, the sub-mucous layer is highly vascular, the cut ends of the vessels being seen in the sections. The circular and irregularly shaped spaces are also present. Below the mucous membrane, as in the lateral section, is a continuous layer of fibro-elastic tissue. Deep to this is a reticulation of the fibrous tissue containing very large venous spaces (FVP) with here and there arteries. This fibro-venous plexus is continuous with the haversian system of the mesial lamina of the pterygoid bone which is not represented in the sections.

In Fraser & Purves 1954 it is stated that the fibro-venous plexus referred to in the two previous sections was supplied by an arterial plexus which emerges from the internal maxillary artery immediately anterior to the tympanic bulla. The plexus is partially drained by an intricate plexus of small veins which penetrates the fibrous covering of the sinus at the angle formed by the lateral pterygoid and tensor palati muscles. This plexus is very dense and ramifies throughout the mass of fatty tissue which lies on the mesial aspect of the lower jaw. The section (Pl. 4, fig. B) is through the lateral wall of the air sac in this region. It is composed of mucous membrane (MUM) which as in the previous sections is provided with racemose crypts. The sub-mucous fibrous tissue (TF) contains considerable aggregations of elastic fibres arranged in sinuous folds. There are also numerous arterial capillaries

(A) and lymphatics. Deeper is a network of fibrovenous spaces (FVP) containing many large and small arterioles shown in transverse section. In places the fibrous interstices of the venous plexus are replaced by fat. Further laterally the fibrovenous plexus is continuous with a system of smaller venioles which penetrate a mass of adipose tissue, i.e. the fatty body of the lower jaw. The walls of these venioles are extremely thin.

Pl. 4, fig. C is a section from the intra-mandibular fatty body on the mesial aspect of the lower jaw showing reticulations of large venous spaces (VN). Open fat cells and lymph ducts are present. The section is lined at one side by a thin layer of fibrous tissue (TF)—mandibular periosteum (see p. 13 *supra*). It is interesting to compare this section with one taken from the fat layer on the lateral aspect of the lower jaw. In this section Pl. 4, fig. D the large venous spaces are absent, although normal arteries and veins are represented. The whole mass of tissue is streaked by parallel patches of striped muscle (MFS).

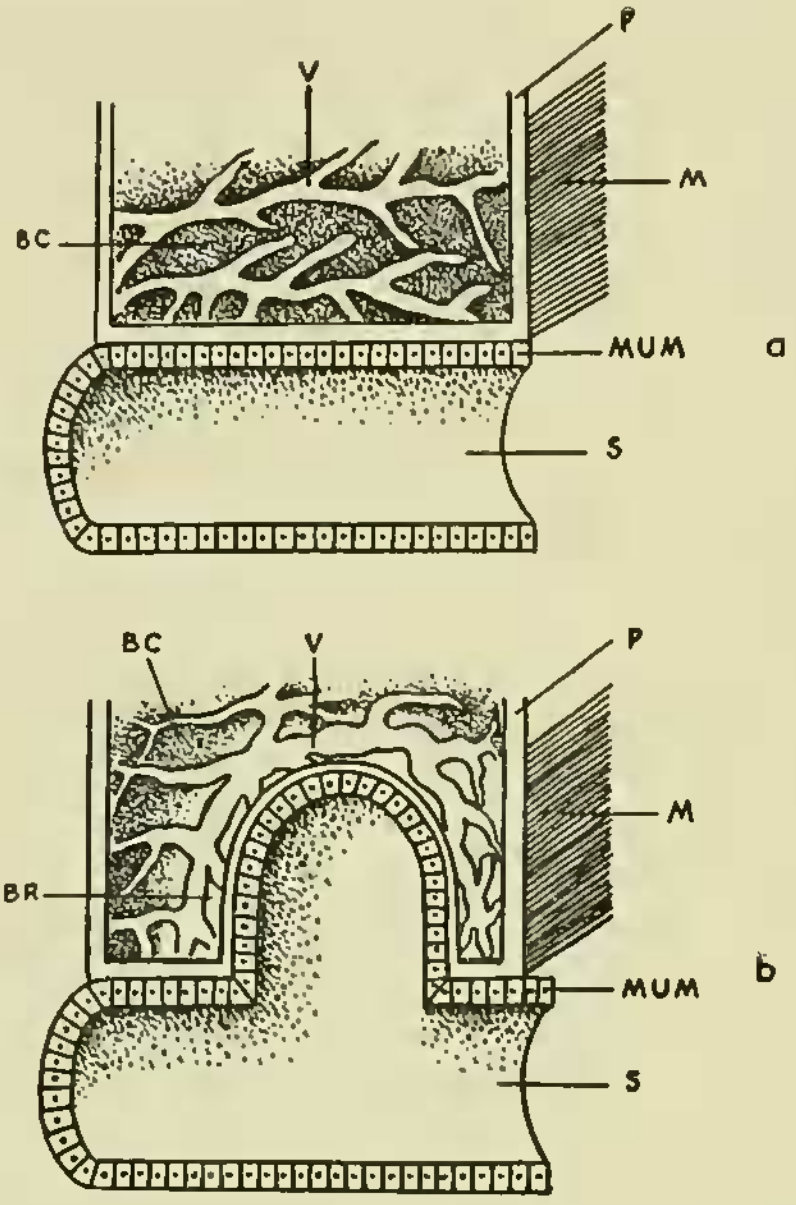

FIG. 11. Diagram to show formation of air sacs and fibro-venous plexus.

From these descriptions it can be seen that the lateral wall of the air sac is composed of four main layers :

1. Surface mucous membrane.
2. Thick layer of fibrous tissue.
3. Open plexus of veins and arteries.
4. A second band of fibrous tissue.

The foregoing histological description applies to the wall of the air sac however extensive the latter may be, so that the fibrous tissue sheet and vascular network mentioned by Boenninghaus reaches beyond the limits defined by him. It allows conclusions about its origin to be drawn. It will be seen in the next chapter that the sinus system is derived from a great extension of the limits of the pterygoid bone, and it is clear that the tissue sheet and vascular system are derived from the periosteum and osteo-vascular system of that bone in the manner shown in Text-fig. 11. Starting with a sinus (S) adjacent to a bone, which can be assumed to be the pterygoid (Text-fig. 11*a*) the principal features are a vascular system (V) in a bony matrix (BC) covered by a layer of periosteum (P), with, external to this again, the mucous membrane (MUM) which contributes the lining of an incipient air sinus system (S). A number of striped muscular fibres (M) are inserted into the lateral wall of the bone. In Text-fig. 11*b* an invagination of the pterygoid bone has commenced, with resorption of the calcified element (BC) of the bone. Laterally, where resorption has proceeded as far as the lateral aspect of the bone, a vascular system remains between two sheets of periosteum, the mesial component of which is lined by mucous membrane, and the lateral supporting the previously mentioned muscle fibres (M). Mesially in the sinus, resorption (BR) of the calcified element has not proceeded to the mesial limit of the bone so that the component parts of the wall of the sinus consist of a vascular network which is continuous with that of the bone, and covered laterally by a single sheet of periosteum and a layer of mucous membrane. The extent to which this process has developed in various cetaceans can be judged from the next chapter.

OSTEOLOGY

There are some features of the cetacean skull to which very little reference has been made in the relevant literature. As a preliminary to a description of these features in the various forms of cetacean it will be necessary to draw attention to basic aspects of the skull. Various descriptions exist of the more or less elongated rostrum, the overlapping extension of the maxillaries above or below the frontal, the elevation and enormous extension of the supra-occipital with the partial or complete exclusion of the frontal and parietal bones from the external surface of the cranium, the diminutive size of the nasal bones and the associated change in direction of the nasal passages from a horizontal to a dorso-ventral situation. The features which concern this paper however are to be found on the ventral aspect of the skull. They are :

1. The ventral displacement of the tympano-periotic bones and their dissociation from the adjacent bones of the cranium.
2. The presence of a falciform process of the squamosal.
3. The basioccipital crests which form a longitudinal arcade for the accommodation of the larynx and naso-pharyngeal muscle complex.
4. The disproportionate enlargement of the pterygoid with overriding of and intrusion into the palatine.

5. The splitting of the pterygoid, and sometimes of the alisphenoid and squamosal also, into lateral and mesial laminae, connected to a greater or lesser extent by superior and inferior laminae.

6. The excavation of the zygomatic process of the squamosal to form the tympano-squamosal recess.

In the descriptions of the skulls which follow, the osteological features will be discussed in the foregoing numerical order and the specimens will be considered in the following sequence—the Mysticeti including the Balaenopteridae, Balaenidae and Eschrichtidae ; and the Odontoceti including the Ziphioidea, Physcteroidea, Platanistoidea, Monodontoidea, Delphinoidea.

MYSTICETI

BALAENOPTERIDAE

In the Mysticeti the arrangement of the bones in the region under discussion in the present paper are described and figured by Lillie (1910) who says " The Cetacea have a remarkable depression on the base of the cranium on each side of the median line (Lillie's fig. 71). In *Balaenoptera* these depressions are bounded posteriorly by the projecting edge of the exoccipital, externally by the base of the zygomatic process of the squamosal, on the inner side behind by the prominent edge of the basioccipital. The anterior portion of the inner side of this depression and the front of the recess are bounded by the pterygoid and alisphenoid bones which are fused together ; the latter also form the roof of the anterior half of the depression. Thus the anterior portion of the cavity is bounded on three sides by the pterygoid and externally by the squamosal, and is known as the pterygoid fossa. In this recess the united tympanic and periotic bones lie."

Ridewood (1922) gives an extensive account of the pterygoid region of *Megaptera* and *Balaenoptera* in which he points out that Lillie's interpretation of the pterygoid fossa as being components of the pterygoid and alisphenoid was wrong, and that he confused it with the pterygoid fossa in man. In the latter the " lateral pterygoid plate " is the descending wing of the alisphenoid. Ridewood is in agreement with Van Kampen (1905) that the pterygoid fossa in mysticetes is contained within the pterygoid bone alone. This also is the interpretation accepted by the present writers and is substantiated by the evidence obtained from the Odontoceti.

The Mysticeti differ from the Odontoceti in that the tympano-periotic is not completely extruded from the cranial wall—thus there is no cranial hiatus. The pyramidal pro-otic portion projects into a cavity in the squamosal bone ; the dorsal surface of the otic portion is a component of the ventral wall of the cranium ; the opisthotic part forms a long thin extension which is the fused mastoid part of the periotic and tympanic. It lies in a deep groove between the exoccipital and the squamosal, its anterior face forming part of the boundary of the meatal groove.

Ridewood's (1922) description of the falciform process of *Megaptera* summarizes the condition found in Balaenopteridae generally (see Pl. 7, FP). He says " The front of the squamous portion (of the squamosal) is prolonged forward, inward and slightly downward as the bifid pterygoid process, the upper part of which overlaps the upper part of the pterygoid bone near, but behind and below the ala temporalis; the lower part of the fork, the processus falciformis, overlaps, i.e. lies external to the part of the pterygoid that forms the external boundary of the pterygoid fossa (or sinus). Between the two parts of the pterygoid just mentioned is a broad notch opening backward, which, in conjunction with the notch in the squamosal bone immediately above the processus falciformis, constitutes the foramen ovale ". (see Pl. 7, FO). Later he states " It is unusual in mammals for the squamosal to extend so far forward as to reach the pterygoid; the whales are exceptional in this respect as they also are in having the foramen ovale in the form of a cleft between the squamosal and the pterygoid." It should be pointed out however that this cleft represents the external opening of the foramen ovale and communicates with a bony infundibulum as will be described in the Odontoceti. The cranial aperture of the infundibulum is formed by a notch in the alisphenoid, again as in the Odontoceti and emphasized in the Physeteridae.

The basioccipital crests (BOC), as shown in *Balaenoptera acutorostrata* (Pl. 7), are low and stout in comparison with the skull as a whole and with the condition found in the Odontoceti. They are insignificant in size. The paroccipital processes (PAO) on the other hand are very prominent and greatly extended laterally. The mesial part of the anterior margin of the process forms the posterior wall of a laterally directed groove, which is bounded anteriorly by the recessed posterior face of the mastoid process of the tympano-periotic (MAS).

In none of the Mysticeti does the pterygoid attain the proportions observed in odontocetes. The mesial (PT (ML)), superior (PT (SL)) and lateral laminae (PT (LL)) of the bone (see p. 34 *supra*) are complete, bounding the pterygoid fossa already referred to. The bony bridge which the lateral lamina of the pterygoid makes between the squamosal (SQ) and the palatine (PAL) is intact, so that the lateral wing of the alisphenoid is concealed except for a small part of its distal extremity in the temporal fossa. There is no extension of the pterygoid beyond the orbital region as in the Odontoceti.

The pterygoid hamuli (PTH) are very small, widely separated and not excavated. Because of this condition the palatine bones form an extensive part of the palate. They are long, broad laminae which posteriorly partly overlap the pterygoid.

There is no evidence of the presence of a tympano-squamosal recess (see p. 9 *supra*).

The extent to which the pterygoid process of the squamosal overlaps the pterygoid bone varies in different balaenopterids (Text-fig. 12 *a–e*). In *B. physalus* and *B. acutorostrata* a broad width of pterygoid separates the pterygoid process of the squamosal from the palatine. This width is progressively narrowed by the extension of the pterygoid process of the squamosal, in the order *B. borealis*, *Megaptera novaeangliae*, *B. brydei*, to *B. musculus* in which the process makes broad contact with the posterior margin of the palatine, so that in this last species the pterygoid is divided into two areas respectively ventral and lateral. It is interesting to note that the contact between squamosal and palatine achieved in *Balaenoptera musculus* is also to be seen in the odontocete *Pseudorca crassidens*.

BALAENIDAE. This family is represented by the two genera *Caperea* and *Balaena*.

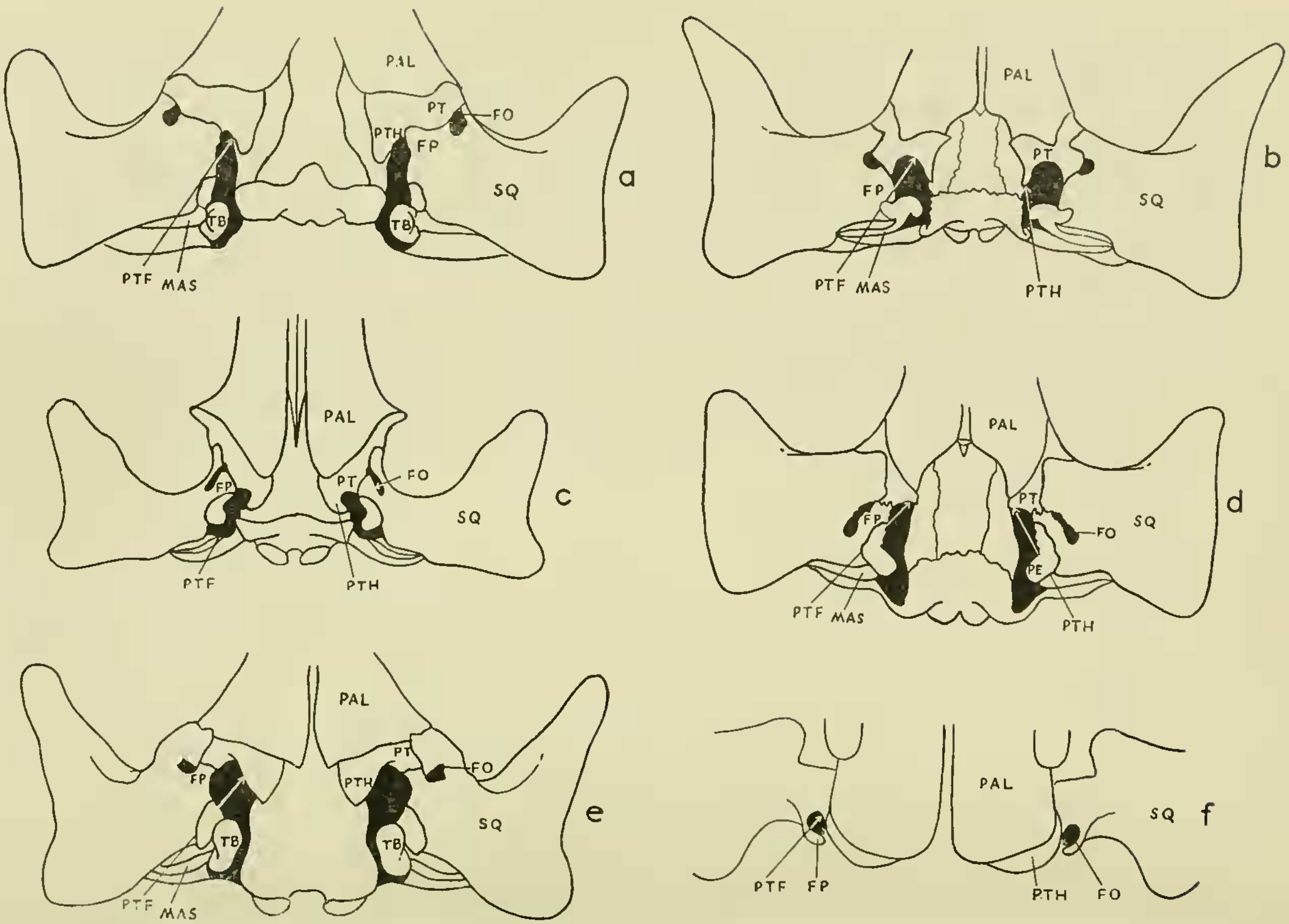

FIG. 12. Diagrams to show relationship of the pterygoid to adjacent bones in various mysticetes.
a. *Balaenoptera physalus*. b. *B. borealis*. c. *M. novaeangliae*. d. *B. brydei*. e. *B. musculus*. f. *Balaena mysticetus*.

In respect of the parts under discussion in the present paper it shows the least degree of specialization. Referring to *Caperea marginata* first (Pl. 5 and 6), the skull as a whole shows more primitive features than any other mysticete. Neither the orbital process of the frontal nor the zygomatic process of the squamosal is very greatly extended laterally, the bony narial passages are elongated and there is a well-defined cribriform plate. The pterygoid hamuli (PTH) are inconspicuous and are separated from each other by nearly the total width of the choanae. The channel for the Eustachian tube from the tympanic cavity to the choanae is not merely a notch in the pterygoid but a deep antero-mesially-directed bony groove on the ventral aspect of the latter bone.

The tympano-periotic bones (TB and PE) are not entirely excluded from the wall of the cranium, a portion of the superior face of the periotic participating in the formation of the cranial cavity. The tympanic bulla is disproportionately large compared with the periotic and is itself relatively much larger than that found in any other mysticete. It is flattened ventrally to conform with the general level of adjacent bones and constitutes an appreciable part of the base of the skull in this region.

The mastoid processes of the tympanic and periotic are fused together, the relatively massive combined process extending to the lateral limit of the skull where it forms a roughly oval facet of considerable area between the basioccipital and squamosal. The mastoid process, although inserted between the bones just mentioned, is freely movable in the macerated skull.

With Ridewood's description of the falciform process of *Megaptera* in mind (see p. 34 *supra*) it should be noted that in *Caperea* the pterygoid process of the squamosal is not bifid and only that part of it corresponding to the falciform process (FP) is developed to any extent. It does not appreciably overlap the pterygoid bone except posteriorly and does not approximate to the external opening of the infundibulum of the foramen ovale (FO). This infundibulum is formed by a transverse, dorsally-directed bifurcation, the two branches of which meet dorsal to the infundibulum.

The basioccipital crests (BOC) are robust and unexcavated and approximate very closely to, but are not, as in terrestrial mammals, in contact with the mesial face of the bulla (see p. 77). The paroccipital process on each side is bounded mesially by a conspicuous semicircular notch which is much larger than, but corresponds in position with, the channel which conducts the 9th, 10th and 11th nerves as well as the internal carotid artery and the internal jugular vein. It communicates with a wide postero-lateral extension of the cranial cavity superior to the periotic. The paroccipital process is recessed on its anterior face to form the posterior limiting wall of an infundibulum, the anterior wall of which is provided by the posterior face of the mastoid process (MAS).

As in cetaceans, generally, the pterygoid bone of *Caperea* is split into a mesial (PT (ML)) and a lateral lamina (PT (LL)) but in addition, superior (PT (SL)) and inferior (PT (IL)) laminae are present so that the cavity so formed is only open posteriorly. The limited distention of the pterygoid sinus is indicated by (*a*) the antero-posterior width of the falciform process (FP), (*b*) the position of the mandibular branch of the 5th nerve (NM) which is anterior to the sinus of the pterygoid (see Text-fig. 15*b*).

It will be recalled that in *Balaenoptera* the infundibulum of the 5th nerve passes above, and posterior to the anterior limit of this sinus.

The pterygoid hamuli (PTH), in addition to being but poorly developed and widely separated, are quite remote from the excavated part of the pterygoids.

The pterygoid (PT) and palatine (PAL) bones meet in a simple edge-to-edge suture, there being no over-lapping of the pterygoid by the palatine as in the Balaenopteridae, and of the palatine by the pterygoid as in the Odontoceti.

There is a deep fissure between the glenoid process and the pterygoid which is comparable in position with the tympano-squamosal recess of odontocetes, but its association, as in odontocetes, with the system of tympanic air spaces seems unlikely. It evidently appears to be related to the close proximity of the elongated glenoid process with the distended lateral lamina of the pterygoid.

The members of the genus *Balaena* although, generally speaking, not as specialized as the Balaenopteridae, still show a considerable advance on the conditions found in *Caperea*. Both the orbital process of the frontal and the zygomatic process of the squamosal are greatly extended laterally. The paroccipital process shows less lateral extension than in the Balaenopteridae. The hard palate is extended posteriorly, the palatine bones being squamous over the pterygoid hamuli to an extent that the latter are sometimes completely hidden in the ventral view of the skull (Text-fig. 12*f*). (The Balaenidae in this condition thus demonstrate exactly the reverse of the condition found in *Platanista* in which the greatly extended pterygoids completely cover the palatines). The hamuli themselves are better developed than in *Caperea*. Their greatly flattened ventral surfaces are in apposition to the overlying palatine bones and the posterior portions of their mesial borders extend towards the middle line.

The tympano-periotic bones are withdrawn in a ventral direction from the cranial cavity, being separated from the latter by a long, narrow, antero-mesially directed infundibulum (Text-fig. 13*c*). The combined tympanic and periotic pars mastoidea is more attenuated than in *Caperea* but considerably shorter than in any of the Balaenopterids, this being associated with the state of development of the paroccipital process. It bears a facet which is a component part of the external surface in this region. The pyramidal pro-otic portion of the periotic is widely exposed and not partly overlapped by the squamosal as in the Balaenopteridae. The tympanic bullae are relatively large and are flattened dorso-ventrally as in *Caperea*. As in the latter their ventral faces form an important portion of the postero-ventral surface of the skull. Their mesial borders approximate closely to the lateral margins of the basioccipital crests.

The pterygoid process of the squamosal is bifid as in the Balaenopteridae but is directed postero-ventrally instead of antero-ventrally as in the latter family. The process overlaps the pterygoid and bifurcates round the external aperture of the foramen ovale forming posteriorly a well defined falciform process (Text-fig. 12*f*, FP). The infundibulum of the foramen ovale (FO) is incomplete posteriorly since the superior lamina of the pterygoid bone is not extended posteriorly as in the Balaenopteridae.

The basioccipital crests are very stout and roughly pyramidal in shape, and are overriden to some extent anteriorly by squamous extensions of the otherwise equally robust mesial laminae of the pterygoids. Each paroccipital process, as previously stated, is relatively short. At the mesial end of its antero-ventral surface is a short, elongated, oval concavity which is in juxtaposition with a similar concavity on the postero-dorsal face of the " pars mastoidea " of the tympano-periotic.

The pterygoid bones, as in other cetaceans, are split into mesial and lateral laminae to form the so-called pterygoid fossa. The two laminae are continuous ventrally and anteriorly, but the superior lamina is deficient posteriorly so that part of the alisphenoid adjacent to the path of the mandibular branch of the fifth nerve is visible in the roof of the pterygoid fossa. The orbital portions of the pterygoid bones are for the most part concealed by a dorso-lateral extension of the palatine. A small slip of the pterygoid can, however, be seen adjacent to the alisphenoid-squamosal suture. The pterygoid hamuli, already described, are not excavated.

The squamosal has an even wider contact with the palatine than in *Balaenoptera musculus* (Text-fig. 12*f*). Between the pterygoid process of the squamosal and the glenoid process (the latter of which is greatly extended ventrally) is a deep concavity which is in the position of the tympano-squamosal recess of the Odontoceti but it is not to be considered homologous with the latter.

ESCHRICHTIDAE. In *Eschrichtius*, as in other cetaceans, the tympano-periotic bone is dissociated from the remainder of the skull and its relation to the cranial cavity is as in *Balaenoptera*. The thin, laminate mastoid process is inserted between the squamosal and basioccipital and extends to the lateral limit of the latter bone. The falciform process is slender and more attenuated than in *Balaenoptera*, resembling in this respect *Balaena*, but it is directed antero-ventrally as in *Balaenoptera*. The infundibulum of the mandibular branch of the 5th nerve is open to the tympanic cavity and occupies the same position as in *Balaena*.

The basioccipital crests are not very prominent but extremely robust with little excavation of their lateral faces. As in *Balaena* the paroccipital notch is very wide, and a smooth area in its proximity suggests excavation of the bone in this region.

The laminae of the pterygoid are complete but the superior lamina does not extend posteriorly under the 5th nerve infundibulum as it does in *Balaenoptera*. The pterygoid fossa does not extend anteriorly as far as in *Balaenoptera* but the pterygoid hamuli are similar in shape to those of the latter species, being unexcavated and not dorso-ventrally compressed as in *Balaena*. The amount of backward extension of the palatine bones in *Eschrichtius* is midway between *Balaenoptera* and *Balaena*.

It will thus be seen that *Eschrichtius* occupies an intermediate position between *Balaena* and *Balaenoptera* as far as the pterygoid sinus system is concerned.

ODONTOCETI

ZIPHIOIDEA

The following species of ziphioid whale have been examined—*Hyperoodon ampullatus, Berardius arnuxi, Berardius bairdi, Ziphius cavirostris, Mesoplodon bidens* (Pls. 8–12). Two general features emerge from the examination, the first being the distinctive difference between the Ziphioids and the Delphinids of the regions under discussion in this paper, the second being the general homogeneity and smoothness of structure of this region in all the ziphioids, there being little or no evidence of progressive changes between individual species.

The tympano-periotic bones of the Ziphioids are excluded from the wall of the cranial cavity, but unlike that of delphinids the mastoid process of the tympanic (MAS) is relatively larger and interdigitates with the pars mastoidea of the squamosal. This interdigitation has been described by many authors as an actual fusion of the bones concerned but in no specimen examined by the present writers has fusion been observed ; in the macerated skull, whatever the age of the animal concerned, the mastoid process of the tympanic is always freely moveable. In very young specimens there is a cranial hiatus dorsal to the periotic but this is soon occluded by extensions of the bones adjacent to the hiatus.

The falciform process (FP) is invariably in the form of a stout spine curving round the anterior margin of the tympanic bulla (TB) and in close approximation to the latter. The process in *Ziphius cavirostris* is distinctive in being stouter, more robust and more flattened meso-laterally than in the remainder of the species examined.

A considerable portion of the proximal part of the infundibulum of the foramen ovale (FO) is present as a lamelliform shelf forming the ventral wall of the channel.

The basioccipital crests (BOC) are massive and show no cavitation of their lateral aspect. The interval between the tympanic bulla and crest is very narrow. The peribullary space as a whole is extremely restricted, and there is none of the excavation round the dorsal margin of the foramen ovale which occurs in the Delphinoidea. The paroccipital processes are massive, unexcavated tubercles. The extensive interdigitation of the mastoid process of the periotic with the paroccipital process is probably associated with the absence of excavation of the anterior face of the latter.

The pterygoid bones are conspicuously large, their length being about one third that of the skull. The general form of the pterygoids is such as to suggest a fundamental difference in the process of modification of these bones in the Ziphioidea from that of all other cetaceans in the disproportionate development of the hamulus (PTH). It will be seen below that in *Platanista* each pterygoid bone is split longitudinally, and more or less equally, into a mesial and a lateral lamina, and that the process of modification from this simple form throughout the series of skulls described, consists of a gradual distention and elaboration of the inter-laminar space, together with the formation of a superior lamina.

In the absence of intermediate stages between the primitive form of pterygoid and the more or less uniform resultant form found in recent ziphioids, the writers' interpretation of the mode of formation of the pterygoid bones is as follows. There appears to have been an initial splitting of the pterygoids, but thereafter this has progressed very asymmetrically, so that the mesial lamina is enormously enlarged whilst the lateral lamina is relatively inconspicuous and compressed ventro-dorsally, and is horizontally instead of vertically disposed. In this condition it overlaps the alisphenoid (ALS), orbitosphenoid (OS) and part of the palatine (PAL). The result of the great exaggeration of the mesial lamina is that the pterygoid hamulus (PTH) is disproportionately enlarged and distended posteriorly and anteriorly. The great fossa on the lateral aspect of the pterygoid bone can be said to be made up almost entirely of the hamular part of the bone, the posterior tip of which is extended backwards to the level of the anterior margin of the basioccipital crest, emphasizing the acuity of the pterygoid notch. Anteriorly the pterygoid bone extends forward over the palatine to make contact with the maxilla (MX) thus dividing the palatine into mesial and lateral portions. In this region the lateral and dorsal parts of the pterygoid are frequently of extreme thinness and in places the bone as such has altogether disappeared, exposing the underlying palatine in macerated specimens (see Pl. 9). The asymmetrical evolution of the pterygoid fossa probably accounts for the greater robustness of the hamuli as compared with those of the delphinoids. In the specimens of *Berardius bairdi* and *B. arnuxi* examined, that part of the pterygoid overlying the alisphenoid is also rarified so that part of the ventral surface of the latter bone is exposed.

The tympano-squamosal recess (TSQR) is of the form found generally in other odontocetes but its boundaries are not as well defined. It consists of a posterior portion which occupies the region behind the glenoid fossa and an anterior extension which lies mesial to the latter fossa and along the anterior margin of the zygomatic process of the squamosal.

PHYSETEROIDEA

In *Kogia* (Pl. 16) as in the ziphioid whales the tympano-periotic bones are excluded from the wall of the cranial cavity, and the mastoid process of the periotic (MAS) is much larger than in the delphinoids. The tympano-periotic bones are apparently disproportionately small, but the mastoid process of the periotic is relatively much larger than in the ziphioids and does not interdigitate with the pars mastoidea of the squamosal. It is a stout, roughly pyramidal tubercle of which the apex points towards, and is attached to, the periotic, and of which the base forms its external aspect. On its squamosal face the bone is marked by a series of deep, radiating channels which appear to be connected with the peculiar cancellated structure of the bone. Its paroccipital aspect forms a smooth, triangular facet. There are no marks on the squamosal nor on the paroccipital process which would suggest a close articulation. On the contrary, the mastoid process appears to lie quite loosely between the bones adjacent to it. When the pars mastoidea of the periotic is dissociated from the latter it is extremely light in weight, is translucent and floats in water as if pneumatized. The mamillated appearance of the external surface of the bone is extremely reminiscent of that of the pneumatized squamosal of other mammals (e.g. adult gorilla). It may also be noted that in the ziphioids generally, as well as in *Kogia*, the bone in the mastoid region has a peculiar, crevassed appearance quite distinct from the bone adjacent to it.

There appears to be no trace of a falciform process, the articulation of the squamosal (SQ) with the alisphenoid (ALS) being more like that found in terrestrial mammals. The foramen ovale (FO) is also in the position typical of terrestrial mammals, that is, within the alisphenoid bone, and there is no trace of a bony infundibulum such as is found in most of the delphinids.

The basioccipital crests (BOC) are stout and prominent, and the paroccipital processes are very large and their concavities of a size commensurate with that of the massive mastoid processes of the periotic.

The pterygoid bones are very greatly enlarged, their length being between a half and two-thirds that of the skull. The constitution of the pterygoid bone is interpretable in terms comparable with those used in connection with the ziphioids, that is to say the splitting of the pterygoid plate appears to have taken place asymmetrically, the mesial lamina (PT (ML)) being greatly enlarged. The ventro-dorsally compressed superior lamina (PT (SL)) is represented only by a short shelf of bone extending laterally below the orbito-sphenoid. It will be recalled that in the ziphioids the greater part of the pterygoid distention was in the hamular region. The reverse is the case in *Kogia*, the hamulus (PTH) being relatively insignificant and not at all distended, whilst the mesial lamina is grossly enlarged and extended posteriorly, partially to override the basioccipital crest. The effect of this on the position of the foramen ovale is discussed in the section below dealing with *Physeter*. Anteriorly the pterygoids are extended as squamations which make contact with the maxillae (MX) and divide the palatines (PAL) into mesial and lateral areas.

The greater part of the ventral surface of the orbital process of the frontals (FR), as well as the preorbital portions of the maxillae have a characteristic smoothness.

The tympano-squamosal recess is poorly developed, consisting of a single lobe which lies along the posterior border of the zygomatic process of the squamosal and terminates at the mesial limit of the ill-defined glenoid fossa.

Flower (1868) remarks on the small size of the tympano-periotic bones of *Physeter catodon*. He goes on to draw attention to the development of a large mass of curiously laminated bone which he says extends from the posterior and outer end of the tympanic, close to its attachment to the periotic, and thicker at its distal than at its proximal end. He states that it is composed of a large number of distinct, thin plates held together only by their common attachment to the tympanic. The present writers have been able to distinguish only two such plates which they regard as the tympanic and periotic elements of the mastoid process. This condition can be homologized with that found in the Delphinioidea, in which, to quote Flower himself : " This process resembles in its relations the mastoid of ordinary mammals, but in young cetaceans it may be seen to be composed of two nearly equal parts, in close apposition with each other, the inferior being derived from the tympanic and the superior from the periotic so that the latter alone can represent the pars mastoidea of other mammals." As Flower says, referring again to the Sperm Whale : " The whole mass partly overlaps and embraces the hinder edge of the squamosal and partly fits into a groove between the latter and the exoccipital." He goes on " It evidently corresponds to the strong tenon-like process of corresponding situation and function in the Whalebone Whales". " The contiguous edge of the squamosal has a laminated character, the ridges and grooves on its surface exactly fitting those of the appendage of the tympanic " [i.e. tympano-periotic].

In the skull of a female sperm whale examined, the mastoid process is not firmly wedged, but freely movable between the bones adjacent to it. The ventral edge of the process is strongly involuted so as to form a bony canal for the external meatus.

The tympano-periotic bones are excluded from the wall of the cranium and in the specimen examined, no trace of the cranial hiatus remains.

The falciform process is moderately well developed, in this respect differing from *Kogia*. The foramen ovale is displaced anteriorly from the process by a considerable distance, a feature to which reference will be made below, and in which *Physeter* and *Kogia* differ from all other cetaceans.

The basioccipital crests are massive tuberosities and are very short antero-posteriorly. The paroccipital processes are relatively small and the ventral margin of the lateral border is strongly involuted to form an infundibulum, the inner end of which is continued in a groove giving access to the peribullary space. As in *Kogia* the pterygoid bones are relatively large and appear to have undergone the same process of asymmetrical splitting observed in the ziphioids. The lateral lamina is extremely compressed ventro-dorsally and squamated over the alisphenoid, orbitosphenoid and frontal bones. The distention of the pterygoid hamulus is slightly greater than in *Kogia* but this part is relatively insignificant as compared with the mesial lamina. The lateral lamina is extended ventrally and posteriorly so that it overrides and partially envelops the basioccipital bone. By the same process the pterygoid notch is deepened but diminished in size. This process of extension posteriorly seems to have involved the posterior margin of the alisphenoid bone.

In the foetal specimen of this species the foramen ovale is situated at the end of a conspicuous longitudinal notch in the posterior margin of the alisphenoid. In the adult specimen the foramen ovale is still more anteriorly situated, and even although it appears to penetrate the lateral wing of the alisphenoid, its true relationship is with the closed up, re-entrant portion of the posterior margin of the latter bone, as in the above-mentioned foetal specimen and in cetaceans generally. The longitudinal notch in the posterior border of the alisphenoid is clearly visible in adult specimens of *Kogia*.

The pterygoid bones are not squamated over the palatines to the same extent as in *Kogia*, the latter bones not being divided into mesial and lateral areas. The whole of the base of the cranium external to the pterygoids shows extensive squamation and rarification of the bones involved.

The glenoid fossa is ill-defined, to say the least, so that it is impossible to delineate the boundaries of the tympano-squamosal recess, but most of the ventral aspect of the zygomatic process of the squamosal is of a characteristic smoothness and has its antero-mesial margin squamated over the alisphenoid.

PLATANISTOIDEA (Pls. 17–23)

Contrary to the view of Hyrtl (1845), repeated by Yamada (1955), the tympano-periotic of *Platanista* (Pls. 17, 18) is not fused to adjacent elements of the cranium in any of the specimens in the British Museum collections, and the series includes old as well as juvenile skulls. The mastoid process (MAS) of the periotic is intimately interdigitated with the squamosal so that after maceration the tympano-periotic remains *in situ* but is freely movable in its interlocked position. The combined elements are displaced ventrally and somewhat laterally from the cranial cavity and the hiatus in the cranial cavity thus formed is partially filled by osteosclerosis of the squamosal, parietal and occipital.

The falciform process (FP) is a stout, bony plate which passes antero-ventrally round the posterior border of the foramen ovale (FO,) almost covering over the alisphenoid and making contact with the posterior border of the lateral lamina (PT (LL)) of the pterygoid bone. There is thus a complete bony bridge extending from the maxilla (MX) to the squamosal (SQ).

The basioccipital crests (BOC), although not very prominent, are stout in structure and on their lateral (tympano-periotic) aspect are profusely cavitated in a manner reminiscent of the mastoid region of terrestrial mammals. Posteriorly to the crests the paroccipital processes (PAO) are deeply excavated by narrow, dorsally-directed concavities.

The palatines are completely obliterated from view by the forward extension of the laminae of the pterygoids. External to the basioccipital arcade, the anterior portion of the squamosal, the alisphenoid and pterygoid bones are split into two distinct laminae with an interval between which is crossed by bony trabeculae and is continuous with the tympanic cavity. The passage of the mandibular branch of the trigeminal nerve through the foramen ovale traverses the inter-laminar space in the form of a bony tube. There is reason to believe that the inter-laminar space (ILS) communicates with another similar inter-laminar space occupying the whole of the mesial aspect of the massive maxillary crests (MXC) which characterize the gangetic Dolphin.

In all the British Museum specimens of *Platanista* except that shown in Pl. 18 the hamular processes of the pterygoids (PTH) are missing and skulls are generally depicted without them. Pl. 18 shows that well-defined processes are present in the juvenile and that they meet in the middle line. They are excavated like the remainder of the pterygoid bones and the ventral surfaces show extensive fenestration. It seems likely that the processes persist in the adult but that they are usually lost in maceration.

In the posterior, proximal part of the zygomatic process of the squamosal there is a ventrally situated, deep, triangular recess the posterior angle of which is adjacent to, and confluent with, the petro-tympanic fissure, the tympano-squamosal recess (TSQR). The ventral angle occupies the mesial aspect of the glenoid process which is deeply excavated. The lateral borders of this recess are strongly involuted. The position and extent of the recess and its contiguity with the petro-tympanic fissure recall the pneumatic extension of the tympanic cavity of *Macropus* as described by Owen (*Anat. of Vert.* Vol. II, p. 341).

In the specimen of *Stenodelphis* figured (Pl. 19), the tympano-periotic is missing but its absence serves to demonstrate the process of exclusion from the cranial cavity already referred to in *Platanista*. The large hiatus (CRH) in the cranial wall can be seen to be partially filled in by osteosclerotic extensions of the alisphenoid (ALS) and parietal (PAR) bones.

As in *Platanista*, the falciform process (FP) is wide, overlaps the alisphenoid and anteriorly makes contact with the posterior border of the pterygoid bone.

The downward extension of the basioccipital crests (BOC) is more emphasized than in *Platanista*. The bone substance does not show the characteristic cavitation seen in *Platanista* except in the region of the paroccipital processes (PAO) which are excavated in a manner comparable with that in the last named genus.

The pterygoid bones do not quite cover the palatine bones (Pl. 19, PAL) but laterally they have an anterior extension below the orbit as far as the jugal (PT and JU). Anteriorly to the tympanic cavity the interlaminar space of the pterygoids is more distended than that of *Platanista*. The bony connection between the lateral and mesial openings of the foramen ovale (FO) is deficient ventrally and laterally. The lateral lamina of the pterygoid (PT (LL)) shows extensive fenestration and antero-laterally the interlaminar space continues into the mesial end of the orbit. The two pterygoid hamuli (PTH) are distended meso-laterally but unlike those of *Platanista* their mesial borders are not in contact but form a wide angle. Anteriorly the dorsal and ventral extensions of each pterygoid are separated by a wide, plate-like process of the maxillary bone (MX).

The orbital extension of the pterygoid bone is of great significance in the interpretation of the distribution of the air sacs in other cetaceans.

The tympano-squamosal recess (TSQR) in the vicinity of the glenoid fossa is more extensive in *Stenodelphis* than in *Platanista*. It can be associated morphologically with the latter by regarding the anterior angle as being much extended anteriorly along the mesial border of the zygomatic process of the squamosal (SQZ). In its course this part of the recess curves round, and in part overlies, the glenoid fossa. Its anterior extremity is situated slightly anterior to the notch formed by the junction of the zygomatic process with the lateral wall of the cranium.

In the genus *Inia* resorbtion of the bones under discussion has proceeded to such an extent that interpretation of their arrangement has had to be arrived at with reference to X-ray photographs of the air sinuses. In Pl. 21 the tympano-periotic is wanting but its absence permits to be seen the same process of exclusion of the ear-bones from cranial contact that was observed in the previously described genus. The osteosclerotic parts of the squamosal, parietal and basioccipital can be seen in the figure forming the anterior margin of the cranial hiatus (CRH).

The falciform process (FP) is reduced to a low, acutely-ridged eminence extending posteriorly from the squamoso-alisphenoidal suture.

At the anterior border of the foramen ovale (FO) an acutely-pointed, laterally-directed process represents the remaining vestige of the bony tube[1] which in *Platanista* connects the cranial and external apertures of the foramen.

The basioccipital crests (BOC) are moderately prominent but rather thin and plate-like. This condition in *Inia* may be interpreted as being due to the merging of numerous cavities like those observed in this region in *Platanista*. The same explanation would account for the deep, re-entrant angle that the plane of the crest makes with the portion of the basioccipital in the vicinity of the tympano-periotic.

Of the hollow which occupied the paroccipital process (PAO) of *Platanista* and *Stenodelphis* only the posterior boundary remains in *Inia*. The anterior and mesial

---

[1] In the succeeding references to the bony tube it should be noted that in the plates the presence of its osseous remnants is usually obscured by the falciform process.

delimitations have completely disappeared so that the cavity persists only as part of the peribullary space.

The condition of the pterygoid bone can best be interpreted by regarding it in relation to that found in *Platanista* and *Stenodelphis.* In *Inia* the whole of the lateral and superior laminae of the pterygoid has disappeared so that the great wing of the alisphenoid (ALS), which in the other two genera was hidden by the pterygoid, is completely exposed. In the posterior narial region the pterygoid is reduced so that only the mesial lamina (PT (ML)) of the pterygoid hamulus remains, except at the posterior border where fenestrated vestiges of the inferior lamina (PT(IL)) still persist. As a result of the extensive resorption of the mesial lamina, the lateral aspect of the palatine (PAL) is largely exposed, and posteriorly to the palatine a wide lacuna gives entrance to the nares. Because of the reduction of the pterygoid bone there is no osseous evidence of its extension into the orbital region as in *Stenodelphis* but radiographs (see p. 70) show that the air sacs primarily associated with the pterygoid protrude into the orbital region (see Pl. 22). As in *Stenodelphis* there is a posteriorly projecting, but in this genus much fenestrated, maxillary plate. This plate was considered by Flower (1889) to be a portion of the palatine fused anteriorly to the maxilla, but the lateral suture between the palatine and the maxillary plate is situated in the deep fossa formed between the aforementioned plate and the palatine. It should be noted that in the post-orbital region of the majority of the specimens of *Inia* examined, the maxillary is exposed to view on its ventral aspect owing to resorption of the frontal (FR).

The greater wing of the sphenoid, part of the parietal and the greater part of the ventral aspect of the frontal present a smooth, polished appearance. It will be demonstrated later that this smoothness is associated with the proximity of the bones to air sacs.

The tympano-squamosal recess (TSQR) is much shallower than in the other two River Dolphins. The anterior angle extends as far as the border of the squamo-cranial notch but does not extend along the mesial margin of the zygomatic process (SQZ) as in *Stenodelphis.* The borders of the recess are not strongly involuted as in the other two genera.

In the only available specimen of *Lipotes* (Pl. 23) the tympano-periotic bones are *in situ* so that the hiatus and the recesses in the paroccipital process cannot be seen, but the general impression which is possible suggests considerable separation of the tympano-periotic bones from the adjacent bones of the skull.

The falciform process has completely disappeared as has also the bony infundibulum of the foramen ovale (FO.) The foramen ovale in this species appears to form a discrete perforation of the alisphenoid but is in fact a re-entrant of that bone, the distal borders being in close apposition in a manner comparable with the condition found in *Physeter* and *Kogia.*

The basioccipital crests (BOC) are more prominent than in *Inia,* but as in the latter are rather thin and plate-like.

The condition of the pterygoids is similar to that in *Inia* but the hamuli (PTH) do not project posteriorly to the same extent as in that species. On the other hand the postero-lateral borders of the pterygoids extend ventrally beyond those of the basioccipital crests so that a deep notch is formed in the crest at the point of junction of the two bones. The lateral lamina is almost as completely resorbed as in *Inia* and the mesial lamina (PT(ML)) is absent anterior to its junction with the posterior edge of the palatine (PAL.) There is no trace of the superior or lateral lamina in the orbital and post-orbital regions and the great wing of the alisphenoid (ALS) is completely exposed. The post-orbital process of the frontal is greatly widened as compared with *Inia* and its ventral surface is smooth as in that genus.

The development of the tympano-squamosal recess (TSQR) shows a considerable advance on *Inia*, its anterior process projecting halfway along the mesial border of the zygomatic process of the squamosal (SQ).

MONODONTOIDEA

Except in the lesser prominence of the falciform process *Monodon monoceros* shows a less advanced state of resorption of the bones associated with the air sinuses than *Delphinapterus* and therefore will be dealt with first.

In the figure of the skull of an adult *Monodon* (Pl. 13) it will be seen that the tympano-periotic bones are missing, but the figure of that of a very young specimen (Pl. 14) shows the position which they occupy and how their ventral surfaces are level with the basioccipital crest (BOC). It will be noted that the mastoid process (MAS) is completely dissociated from the adjacent bones of the skull. In the juvenile specimen there is a wide hiatus in the cranial cavity above the tympano-periotic bone but in the adult (Pl. 13) this has been largely filled in by extensions from the squamosal, parietal and alisphenoid.

The falciform process (FP) is a low, rather stout tubercle (Pl. 13). Of the bony tube of the foramen ovale (FO) which transmits the mandibular branch of the trigeminal nerve the anterior, dorsal and ventral walls of its mesial portion remain, *Monodon* in this respect being unlike *Inia* in which only a very small, spike-like portion of the wall persists (see p. 46 *supra*).

The basioccipital crests are more prominent and the laryngeal arcade between them more heightened than in the River Dolphins. The crests themselves are stouter and show a condition of excavation of their lateral aspect similar to that of *Stenodelphis*. The excavation of the paroccipital process (PAO) consists of a saucer-like depression with an anterior communication into the peribullary space ; there is no evidence of a ventral closing wall as in *Platanista*.

The space between the mesial (PT (ML)) and lateral laminae (PT (LL)) of the pterygoid, which involves palatine and alisphenoid bones, is considerably more distended than in any of the River Dolphins. Posteriorly the superior lamina (PT (SL)) of the pterygoid has disappeared exposing to view most of the greater wing of the alisphenoid, as in *Inia*. In this respect the posterior region of the pterygoid shows a more advanced state of resorption than that of the anterior region. The pterygoid hamuli (PTH) are only slightly excavated and their mesial borders are widely separated anteriorly and approximately but not touching posteriorly.

The lateral laminae of the alisphenoid, pterygoid and palatine on each side, form a bony bridge extending posteriorly from the anterior border of the orbital process of the frontal to the squamosal. The greater part of the ventral portions of these laminae has disappeared leaving a wide, gaping, irregular concavity on the ventrolateral aspect of the skull.

The overgrowth of the palatines by the pterygoids is less conspicuous than in the River Dolphins, large areas of the palatine bones being visible on the ventral aspect of the skull.

The tympano-squamosal recess (tsqr) is wide by comparison with that of any of the River Dolphins. Its anterior border is ill-defined, its mesial and lateral borders slightly involuted.

In the figured specimen (Pl. 15) of the skull of *Delphinapterus leucas* the tympano-periotic bone is wanting, showing the dissociation of these bones from the adjacent bones of the skull. The cranial hiatus (crh) is seen in the figure as are the osteo-sclerotic extensions of the basioccipital (bo), parietal (par), alisphenoid (als) and squamosal (sq). An examination of a number of skulls of adult specimens shows that the hiatus eventually becomes almost entirely obliterated by such extensions.

The falciform process (fp) is much more prominent in this species than in *Delphinapterus* and bears, on its mesial surface proximally, a residual part of the wall of the bony tube of the foramen ovale. Remnants of the mesial part of this tube are also found in the same relative position and in the same form as in *Monodon*.

The basioccipital crests (boc) are robust and prominent. The paroccipital excavations like those of *Monodon* are open ventrally to expose a shallow depression communicating anteriorly with the peribullary space.

As in *Mondon*, the posterior portion of the superior lamina (pt (sl)) of the pterygoid has disappeared exposing a part of the alisphenoid (als) ; the state of development of the anterior portion is also very similar to the condition found in *Monodon*, there being no lateral extension of the pterygoid inter-laminar space in the orbital region. The pterygoid hamuli (pth) are more excavated and the juvenile specimen figured shows considerable fenestration of their ventral surfaces.

Of the bony bridge, which in *Monodon* extends posteriorly from the anterior border of the supra-orbital process of the frontal to the squamosal, very little remains. The alisphenoidal portion of this lateral lamina is wanting. The pterygoid portion (pt (ll)) is fragmentary and irregularly bordered, with a slender extension posteriorly to the squamosal. Its anterior border is separated from the lateral lamina of the palatine (pal (ll)) by a short gap. The lateral concavities in the ventral aspect of the skull are thus still delineated mesially by the basioccipital ridges and laterally by the above-mentioned bony bridges. It should be noted that the anterior end of the concavities excavate the palatine bones to a greater extent than in *Monodon*. The pterygoids do not override the palatines anteriorly but make deep invaginations into the posterior borders of the latter. The hamuli are similar to those of *Monodon*, being separated mesially from each other, their mesial borders being wider apart anteriorly than posteriorly.

As in *Mondon* the tympano-squamosal recess is shallow and ill-defined, with almost no involution of any of the borders.

DELPHINOIDEA

PHOCAENIDAE (Pls. 26, 27, 28). The tympano-periotic in the specimen of *Phocaena phocoena* figured (Pl. 26) is missing, being dissociated from the remainder of the skull. The cranial hiatus (CRH) dorsal to the ear bones is partly filled by osteosclerotic extensions of the basioccipital (BO) and parietal (PAR).

The falciform process (FP) is reduced to a low, rounded, ventro-mesially projecting, thin blade. Of the bony tube of the foramen ovale (FO) only a minute fragment of the mesial portion remains and the foramen itself is very much enlarged.

The basioccipital crests (BOC) are very prominent but very thin, being fenestrated in the region mesial to the peribullary space. Posteriorly and mesially to the tympanic bulla the edge of the crest is strongly involuted so that it forms a partial floor to the peribullâry space. The paroccipital processes are deeply excavated on the anterior face and bear a shallow depression on their antero-ventral aspect.

The whole of the superior lamina of the pterygoid has disappeared so that the wing of the alisphenoid (ALS) and the ventral face of the orbito-sphenoid (OS) are exposed. The mesial lamina (PT(ML)) and the sphenoid wing form a deep, trough-like fossa anterior to the peribullary space. The lateral lamina of the pterygoid (PT (LL)) remains as a narrow, perforated, irregularly-edged strip of bone connected anteriorly to the palatine and posteriorly to the alisphenoid (Pl. 26).

Although no bony remnants of an orbital distention of the pterygoid bone remain, it is known that an extension of the air sinus system passes dorsally and posteriorly into a deep cavity, the walls of which are formed by the anterior face of the frontal and the ventral face of the maxillary bones (MX). A great part of the mesial wall of this cavity is formed by a portion of the mesial lamina of the pterygoid.

The pterygoid hamuli (PTH) are more extensively excavated than in the Monodontidae and are frequently fenestrated on their ventral surface. The hamuli are widely separated, with their mesial borders divergent caudally.

The tympano-squamosal recess is extended laterally in front of the glenoid fossa. Its lateral border is involuted.

The arrangement of the bones under discussion in *Neomeris phocaenoides* (Pl. 28) is essentially as in *Phocaena phocoena* with, however, some noteworthy differences. The basioccipital crests (BOC) are more robust but not so strongly involuted in the region of the tympanic bulla. The fossae formed by the mesial lamina of the pterygoid (PT (ML)) and the greater wing of the sphenoid, and that on the anterior face of the cranium, are enlarged. The bony bridge formed by the lateral lamina of the alisphenoid, which is reduced to a minute promontory, extends anteriorly to the postero-dorsal angle of the pterygoid bone.

DELPHINIDAE (Pls. 29–35). *Pseudorca crassidens*, so far as the region of the skull under consideration is concerned, shows the most primitive arrangement existing in any of the Delphinidae. In the plates (Pls. 29, 30) the tympano-periotic is missing so that the great extent to which the cranial hiatus has been obliterated by secondary osteosclerosis is well-demonstrated; only the foramina for the transmission of blood vessels and nerves persist.

The falciform process (FP) is a broad, irregularly-outlined, robust plate the posterior margin of which, proximally, follows the contour of the tympanic bulla situated immediately behind it. The bony tube which transmits the mandibular branch of the fifth nerve is represented by spicular, bony elements involving the pterygoid and alisphenoid. They extend from the cranial wall obliquely and caudally to make contact with the inner aspect of the falciform process.

The basioccipital crests (BOC) are very stout and extensively cavitated on their lateral aspect. They are not very prominent so that the laryngeal arcade is correspondingly shallow as compared with that of other Delphinids. The depressions on the ventral aspect of the paroccipital processes (PAO) are rather ill-defined.

Pseudorca crassidens shares with *Balaenoptera musculus* the distinction from other forms of having the falciform process in contact with the posterior border of the palatine. Thus there is a continuous bony bridge, as in certain species previously described, but it is deficient in bony elements of the pterygoid and alisphenoid, the lateral bony lamina consisting solely of extensions of the palatine (PAL (LL)) and squamosal (SQ). A considerable portion of the superior lamina of the pterygoid (PT(SL)) is still present but it does not cover the alisphenoid to any great extent. Laterally the ventral border of the mesial lamina of the pterygoid (PT(ML)) is deeply excavated by numerous, and for the most part longitudinally-directed, indentations which continue for a distance into the posterior nares. At their terminus there originates a posteriorly directed bony groove which lies along the mesial aspect of the ventral border of the pterygoid. As in the River Dolphins, notably *Stenodelphis*, there is an extension of the pterygoid above the plate of the palatine which has a distinct horizontal, laterally-directed flexure in this area. This orbital extension is much better defined and more strongly developed than that of the River Dolphins, and, owing to the presence of a large optic nerve, is divided into two distinct lobes, the one passing round the anterior margin of the optic foramen, the other posterior to the foramen. In the amount of osseous content remaining in the prepared skull there is considerable individual variation within the species. In the specimen shown in Plate 29, the inferior, mesial and lateral laminae of the orbital extension of the pterygoid are complete, so that the inter-laminar space is enclosed in an unperforated bony case, whereas in the specimen shown in Pl. 30, the bony laminae are so rarified that only a cage-like remnant persists.

On the palatal surface the palatine bones (PAL) are widely exposed, but their posterior face is deeply invaginated by the forward extension of the cavity of the pterygoid hamuli (PTH). The hamuli are strongly excavated and their mesial borders are in close apposition in the middle line.

The tympano-squamosal recess (TSQR) is wide, shallow and ill-defined, but its anterior extension reaches almost to the anterior tip of the zygomatic process.

The tympano-periotic bones are absent in the specimen of *Orcinus orca* figured (Pl. 31). The cranial hiatus (CRH) shows dimensions consonant with the juvenile condition of the skull, there being little osteosclerosis of the marginal bones.

The falciform process (FP) is more attenuated than in *Pseudorca*, being a sickle-shaped, narrow plate with irregularly pointed extremity. The bony tube of the foramen ovale (FO) is represented by a small flange projecting from the cranial wall. On the mesial face of the falciform process there is a small tuberosity which apparently represents the last vestige of the distal end of the tube.

The basioccipital crests are moderately thin and prominent, with a small amount of cavitation of their lateral aspect. The depressions of the paroccipital processes (PAO) like those of *Pseudorca* are rather ill-defined.

The lateral lamina and the greater part of the superior lamina of the pterygoid bone, except in the hamular region, have disappeared. A large area of the alisphenoid (ALS) is exposed. A small portion of the superior lamina (PT (SL)) persists, covering the mesial end of the ventral face of the orbito-sphenoid and a small part of the adjacent alisphenoid. The mesial lamina (PT (ML)), as in *Pseudorca,* is scored by a number of longitudinal grooves on the ventral margin; they are not however, as conspicuous as in *Pseudorca crassidens*. As in *Pseudorca* there is an extension of the pterygoid (PT) into the pre-orbital region although it is more resorbed than in that species. It extends anteriorly from the mesial lamina of the pterygoid as a small, recurved, finely fenestrated plate of bone which lies alongside the lateral face of the palatine. A feature, which is distinctive of *Orcinus*, is that the fossa which gives access to the maxillary foramen is very much enlarged relative to that of other dolphins. It is confluent with the pre-orbital smoothed area. Parts of the jugal and maxilla lateral to the pre-orbital smoothed area have a flattened squamous appearance above the position of the eye. In the position occupied by the post-orbital extension of the pterygoid in *Pseudorca* there is in *Orca* a shallow depression on the ventral surface of the frontal, in which the bone is of a smoother texture than that which surrounds it. The smooth area in the preorbital region is considerably larger than the area occupied by the preorbital extension of the pterygoid in *Pseudorca.* The significance of these features is referred to on p. 96.

The pterygoid hamuli (PTH) are moderately excavated, their ventral aspects being fenestrated (this latter condition is usually associated with juvenile specimens) and their mesial borders are in contact in the middle line. The palatine bones (PAL) are extensively exposed ventrally and laterally and their posterior faces are very strongly invaginated.

The tympano-squamosal recess is wide and well defined ; its anterior extremity extends about halfway along the mesial border of the zygomatic process of the squamosal. The antero-mesial margin is involuted.

In the specimen of *Orcaella* figured (Pl. 32) the tympanic bulla and periotic are absent and the infilling of the cranial hiatus (CRH) is composed of an osteosclerotic extension of the parietal.

The falciform process (FP) is slender, curved and ventrally projecting. A very small laterally-projecting spine on the ventral margin of the foramen ovale (FO) represents the last remnant of the bony tube of the fifth nerve mandibular branch.

The basioccipital crests (BOC) are thinner than those of *Orcinus*. The paroccipital processes (PAO) are marked by shallow excavations of the anterior face.

Posteriorly not a vestige remains either of the superior or of the lateral lamina of the pterygoid, nor is there a trace of the lateral lamina of the alisphenoid. The greater wing of the sphenoid (ALS) and most of the orbito-sphenoid (OS) are exposed, and a large hiatus is present in the region of the optic canal (OF). There is a small remnant of the orbital extension ot the pterygoid in the form of a narrow shelf (PT(SL)) and a slender, curved spine extending laterally from the mesial lamina of the pterygoid (PT (ML)) along the anterior border of the orbito-sphenoid. In this position the palatine bone shows a conspicuous, horizontal, laterally-directed flexure (PAL (LL)). As in *Orcinus* there are two smoothed depressions in the ventral surface of the frontal corresponding in position to the pre- and post-orbital extensions of the pterygoid noted in *Pseudorca*. The anterior depression is much larger than the posterior and communicates with a cavity which lies between the frontal and maxillary bones on the front of the cranium. There is also a small, smoothed area on the proximal end of the maxilla. In the relative extent of the smoothed areas *Orcaella* resembles *Orcinus*.

The pterygoid hamuli (PTH) are excavated but not inflated and their mesial borders are widely separated.

In *Orcaella* the anterior prolongation of the tympano-squamosal recess (TSQR) extends almost to the anterior limit of the zygomatic process of the squamosal.

In the *Globicephala melaena* skull figured (Pl. 33) the tympano-periotic bones are lacking. The cranial hiatus (CRH) is very largely occluded so that only the foramina of the nerves remain. The falciform process (FP) is a truncated, irregular plate, which bears no trace of the bony tube of the foramen ovale (FO) on its mesial aspect. A small flange on the alisphenoid (ALS) represents the proximal end of this tube.

The basioccipital crests (BOC) are moderately stout and shallowly cavitated on their lateral aspect.

The depressions on the paroccipital processes (PAO) are separated only by a very low ridge from the peribullary space.

The lateral lamina of the pterygoid is completely wanting, but a small remnant of the lateral lamina of the alisphenoid remains in the form of a low, ventrally projecting ridge at the lateral extremity. Of the superior lamina of the pterygoid the greater part of the posterior portion is wanting, exposing the wing of the alisphenoid (ALS). Anteriorly however there is a fairly wide plate of the lamina (PT (SL)) underlying the orbitosphenoid (OS). No bony vestige remains of the pre-orbital extension of the pterygoid, but the whole of this region is deeply recessed and is partially lined by a squamous extension of the palatine bone (PAL), the remainder of the recess involving the maxilla (MX). An extension of the recess passes dorsally and posteriorly, between the frontal and the maxilla. The two smoothed depressions on the ventral aspect of the frontal bones which were observed in *Orcinus* and *Orcaella* are also present in *Globicephala* but there is an enlargement of the posterior depression corresponding with the enlargement of the anterior one, so that both are equal in area. To this extent *Globicephala* differs from the other two genera just mentioned, in which the posterior depression is relatively insignificant.

The pterygoid hamuli (PTH) are entirely excavated and very widely dilated, and in juvenile specimens there is fenestration of the ventral aspect. The mesial borders of the two hamuli are in contact. Anteriorly the palatine bones are not extensively overgrown by the pterygoids and the invagination of their posterior face is only moderate.

The tympano-squamosal recess (TSQR) extends to the anterior tip of the zygomatic process of the squamosal, as in *Orcinus*.

The tympano-periotic bones are dissociated from the skull of the specimen of *Feresa intermedia* figured (Pl. 35) and the cranial hiatus (CRH) is partially obliterated by extensions from the bones adjacent to it. The margins of the peribullary sinus are deeply involuted, particularly in the anterior region. Here the wing of the sphenoid is divided horizontally into two laminae by an extension of the peribullary space.

The falciform process (FP) is broken but the remaining basal part suggests that it consisted of a small hamate plate of bone. The fracture is such that it is impossible to state whether any remnant of the distal end of the bony tube of the foramen ovale remains. The proximal end of the tube is well-defined.

The basioccipital crests (BOC) are slender but quite prominent, and involuted laterally on their ventral margin. The depression in the paroccipital process (PAO) is moderately defined.

No vestige of the lateral and superior laminae of the pterygoid bone remains except for a small shelf of the superior lamina (PT (SL)) below the orbitosphenoid (OS). In both the specimens available there is secondary cavitation of the alisphenoid (ALS) and frontal (FR). Of the pre-orbital extension of the pterygoid only part of the mesial lamina remains and the pre-orbital region generally is recessed as in *Globicephala melaena*, the recess being partially lined by a squamous extension of the palatine bone. The recess between the frontal and maxillary is moderately well developed on the right side but not so evident on the left. The two pre-orbital recesses of each side are markedly asymmetrical, that on the right being much larger than the other. The smoothed, post-orbital recesses are larger in area in relation to the preorbital than in *Globicephala*.

The pterygoid hamuli (PTH) are widely dilated, and they are extensively fenestrated on their ventral aspect. As their posterior extremities are missing it is impossible to state whether the pterygoids meet in the middle line, but it seems likely that they do. The palatine bones (PAL) are not extensively overgrown by the pterygoids but their posterior faces, as well as those of the maxillae, are deeply invaginated by an intercalation of the pterygoid cavity.

The tympano-squamosal recess (TSQR) is relatively extensive, its anterior extremity spreading out and occupying the whole of the ventral surface of the anterior apophysis of the zygomatic process of the squamosal.

Cephalorhynchus heavisidei and *C. commersoni* are sufficiently alike to be considered together. In the figured specimen of *C. heavisidei* (Pl. 36) the tympano-periotic bone is dissociated from the skull so that the very large cranial hiatus (CRH) is exposed. The falciform process (FP) is a wide, bifurcated bone with no trace of the infundibulum of the mandibular branch of the 5th nerve on its mesial aspect. A short length of the mesial portion of the infundibulum protrudes from the wing of the sphenoid bone partially surrounding the foramen ovale (FO).

The basioccipital crests (BOC) are thin, partially excavated and moderately involuted. There is a small recess on the ventral face of each of the paroccipital processes (PAO). The pterygoid plate and hamuli are wanting but from observation of a complete specimen of *C. commersoni* no trace of the superior or lateral laminae of the pterygoid remains.

The bony orbital extensions of the pterygoid are absent and a very deep pre-orbital recess passes between frontal and maxilla. The post-orbital recess on the ventral aspect of the frontal is almost contiguous with the pre-orbital recess and has a posteriorly projecting extension under the post-orbital processs of the frontal (FR (PO)). In this respect, and in the degree of excavation of the pterygoid hamuli, together with the separation of the hamuli, *Cephalorhynchus* compares with *Phocaena*.

The tympano-squamosal recess (TSQR) is limited in area, extending only halfway along the mesial border of the zygomatic process of the squamosal—another respect in which it bears some resemblance to *Phocaena*.

The skull of *Lagenorhynchus albirostris* examined but not figured, lacks the tympano-periotic bone and, as in *Pseudorca crassidens*, the cranial hiatus is filled by secondary bone except for the foramina. The falciform process is a wide, irregularly-shaped, thin plate with a slender, ventrally directed spine which makes contact with the anterior extremity of the bulla. The remnants of the bony tube of the foramen ovale consist of a few postero-laterally directed spicules as in *Pseudorca crassidens*.

The basioccipital crests are thin, plate-like, very prominent ridges. The depressions of the paroccipital processes are shallow.

In Pl. 37 which shows the anterior portion of a cranium, the bony bridge of the lateral lamina consists of elements of the alisphenoid (ALS), pterygoid (PT (LL)) and palatine (PAL (LL)). The pterygoid element, which is much fenestrated, is sutured anteriorly to the lateral corner of the hamular part of the same bone (PTH), in addition to being in contact with the palatine. Although there is no contact between the lateral pterygoid element, and either the superior (PT (SL)) or mesial portions (PT (ML)), its identity as part of the pterygoid bone can be deduced by reference to the condition of the lateral lamina in *Monodon*, in which the lateral portion is joined to the superior portion by small, extremely thin, bony connections. As in previously described species there is, in *Lagenorhynchus albirostris*, an extension of the pterygoid bone into the orbital and pre-orbital regions, but the greater part of its lateral lamina has disappeared. Of the superior lamina of the pterygoid, only that part which underlies the orbito-sphenoid remains.

The pre- and post-orbital depressions on the ventral surface of the frontal are relatively smaller than in *Cephalorhynchus*. *L. albirostris* compares with that genus in having an extension of the post-orbital depression passing posteriorly under the post-orbital process of the frontal.

The pterygoid hamuli are deeply excavated, and elongated, each showing a sharp keel ventrally, a feature which characterizes most of the specialized delphinids. The mesial borders of the hamuli meet in the middle line.

The tympano-squamosal recess (TSQR) is a deep, crescent-shaped fossa bordering the postero-mesial margin of the glenoid fossa. Its anterior extension reaches to about half way along the anterior border of the zygomatic process. The lateral margin is strongly involuted.

Before proceeding with a description of the ventral region of the skull of *Lagenorhynchus acutus*, it should be noted here that the precedence of order in the descriptions has been decided by the extent to which the lateral lamina is evident. The presence or absence of this bony bridge in the prepared specimens is dependent upon the degree of attachment of the bridge elements to the squamosal and palatine. The absence of the component bridge elements does not imply that such elements do not exist, and indeed it has been observed that small fragments of the bridge are sometimes present in the fibrous connective tissue and are usually lost in the process of maceration. The presence of such unconnected ossicles is an indication of greater specialization in the evolution of the air sinuses than is the case when a connected bony bridge persists.

In the figured skull of *L. acutus* (Pl. 39) the tympano-periotic bones are absent, and the partial obliteration of the cranial hiatus (CRH) is illustrated. In this species the cavity occupied by the peribullary sinus is well defined and its borders involuted. The greater extent of this involution, as compared with that present in this region in *L. albirostris*, indicates that, as far as the evolution of the peribullary space is concerned *L. acutus* is in an earlier phase than *L. albirostris*.

The falciform process (FP) is a robust, digitiform plate making contact on its inner face with the bony tube of the foramen ovale (FO). The bony tube is nearly entire in this species and is a conspicuous lateral projection of the cranial wall.

The basioccipital crests are thin, prominent and involuted. The ventral depressions of the paroccipital processes (PAO) are very shallow but the processes themselves are deeply cavitated dorsally, the cavities being confluent with those of the peribullary spaces.

Whether or not any portions of the bony bridge of the lateral lamina are present in the living animal has not been ascertained but the state of resorption of the superior lamina indicates that if such remnants are present they will be very small. The superior lamina is restricted to a narrow strip bordering the mesial margin of the orbito-sphenoid (OS). The alisphenoid (ALS) is completely exposed. The extension of the pterygoid bone into the pre-orbital region is strongly reminiscent of the condition found in the specimen of *Pseudorca* shown in Pl. 30. It consists, on the right side, of a pointed, laterally projecting loop of bone (see Pl. 39) on the left side it forms a small, flat, oblique, fenestrated projection. There is a slight lateral flexure of the palatine bone (PAL (LL)) adjacent to it.

The pterygoid hamuli (PTH) are completely excavated and their mesial margins meet in the middle line. The excavation of the hamuli anteriorly does not produce a corresponding invagination of the posterior wall of the palatines as in some species already described. On the palatal surface of the skull the palatine bones (PAL) are exposed to a moderately conspicuous extent.

The pre- and post-orbital smoothed areas on the ventral surface of the frontal are like those of *L. albirostris*.

The tympano-squamosal recess (TSQR) is small and its margins strongly involuted like those of the peribullary space. Its anterior limit extends only a short distance along the anterior margin of the zygomatic process.

In the *Lagenorhynchus obscurus* specimen figured (Pl. 40) the tympano-periotic bones are missing and the cranial hiatus (CRH) is wide and conspicuous, although its original extent is reduced by secondary growth of bone from the alisphenoid and parietal. As in the previous species, there is involution of the border of the peribullary space but not to the same extent.

The falciform process (FP) is a small, roughly triangular plate. Of the bony tube of the foramen ovale (FO) only a small portion of its cranial end remains.

The basioccipital crests (BOC) are extremely thin and delicate. The depressions on the paroccipital processes (PAO) are more conspicuous than in *L. acutus*, and there is a slight excavation of the anterior face of the processes themselves.

No part of the lateral lamina of the pterygoid and alisphenoid remains, and of the superior lamina (PT (SL)) only a small plate extends under the orbito-sphenoid. On the right side, this plate has a small, lateral, strap-like projection (see Pl. 40 (PT)). Of the orbito-pre-orbital bony extension of the pterygoid, only a minute, anteriorly projecting spicule remains, but the pre-orbital regions of the lateral face of the palatine and maxillary are strongly recessed, the bone in this area being of the characteristic smoothness associated with proximity to air sacs.

The pre-orbital depressions on the ventral face of the frontal are conspicuously larger than those of *L. albirostris* or *L. acutus*, and give indication of coalescence with the post-orbital smoothed areas. The latter are comparable in extent to those of the species just mentioned.

The pterygoid hamuli (PTH) are completely excavated, their mesial borders being parallel proximally but strongly divergent distally. The excavation of the hamuli does not involve invagination of the posterior face of the palatines (PAL), and the latter are themselves moderately conspicuous on the palatal aspect of the skull.

The tympano-squamosal recess (TSQR) on each side is conspicuous, its margin involuted, the anterior extremity extending as far as the anterior end of the zygomatic process of the squamosal. This extension is obscured in Pl. 40 by the glenoid fossa.

In the figured skull (Pl. 41) of *Grampus griseus* the tympano-periotic bones are missing and the cranial hiatus is obliterated by secondary bone, except for the foramina of the auditory nerve and the foramen lacerum posterius.

The falciform process (FP) is narrow and irregularly outlined. On its mesial face it bears a small shelf of bone which sutures with the distal end of the bony tube of the foramen ovale, thus the ventral wall of this tube is complete. Between the mesial face of the falciform process and the lateral edge of the bony tube of the foramen ovale (i.e. alisphenoid) a small, irregularly triangular piece of bone is inserted. This is the last vestige of the lateral lamina of the pterygoid bone in this region.

The basioccipital crests (BOC) are moderately stout and not cavitated.

The depressions on the paroccipital processes (PAO) merge anteriorly with the peribullary space.

Apart from the portion of lateral lamina of the pterygoid bone mentioned above, no other trace remains. Of the superior lamina (PT (SL)) the part underlying the alisphenoid is wanting, but beneath the orbito-sphenoid (OS) is a wide, plate-like remnant which extends in places beyond the lateral border of the orbito-sphenoid and bears on its anterior border a small, laterally directed process. Of the pre-orbital bony extension of the pterygoid only portions of the mesial lamina remain, but in this region a wide recess excavates deeply into the lateral face of the palatine (PAL) bone and passes postero-dorsally above the pre-orbital margin of the frontal in a manner similar to that found in *Phocaena phocoena*.

The pre- and post-orbital smoothed areas on the ventral surface of the frontal

(FR) are very extensive and indicate coalescence with one another. The post-orbital extension is widely spread on the postero-ventral face of the frontal. The pre-orbital area extends anteriorly onto the posterior end of the ventral face of the maxilla.

The pterygoid hamuli (PTH) are deeply excavated and dilated, with their ventral aspect frequently considerably fenestrated. In the specimen figured, the palatine bone, on the palatal surface, is partially obscured by the overgrowth of the pterygoid bone, but in the range of specimens available for inspection there is considerable variation in the extent to which the palatine on each side is overgrown by the pterygoid bone. The anterior face of the palatine is deeply invaginated by the forward extension of the cavity of the pterygoid hamulus. The mesial borders of the hamuli meet in the middle line.

The tympano-squamosal recesses (TSQR) are extensive but ill-defined anteriorly.

In the figured specimen of *Tursiops truncatus* the tympano-periotic bones are missing. Pl. 43 shows the cranial hiatus (CRH) largely occluded by secondary bone so that only the well-defined foramina of the appropriate nerves persist.

The falciform process (FP) is of the shape implied by the name given to this portion of the squamosal. No remnants remain of the distal end of the bony tube of the foramen ovale (FO), but a small tuberosity on the alisphenoid (ALS) representing the vestige of this tube is sometimes present proximally.

The basioccipital crests (BOC) are moderately prominent and robust, the posterior portions being slightly involuted. The paroccipital processes (PAO) are excavated anteriorly and ventrally.

The whole of the lateral lamina and the greater part of the superior lamina of the pterygoid have disappeared so that the wing of the alisphenoid (ALS) is widely exposed. Anteriorly a very small remnant of the superior lamina (PT (SL)) overlaps the orbito-sphenoid (OS). The orbito-preorbital extension of the pterygoid bone is represented only by a small portion of the mesial lamina. A small lateral flexure of the palatine (PAL (LL)) in the preorbital region is shown in Pl. 43.

The pre- and post-orbital smoothed areas are very similar to those of *Grampus griseus*, thus there is evidence of coalescence of the two areas lateral to the optic foramen (OF), and of an extension of the post-orbital area onto the postero-ventral face of the frontal (FR (PO)). *Tursiops* differs from *Grampus* in that the pre-orbital extension of the smoothed area on the posterior end of the ventral surface of the maxilla (MX) is longer and much more conspicuous.

The pterygoid hamuli (PTH) are completely excavated but the inter-laminar space is very restricted by the close approximation of the laminae. The ventral surfaces of the lateral laminae are flattened but strongly keeled, their mesial borders meeting in the middle line.

The palatine bones (PAL) are extensively exposed anteriorly and laterally to the pterygoid hamuli and there is little or no excavation of their posterior face by extensions of the hamular cavities.

The tympano-squamosal recess (TSQR) is well-defined; mesially the boundary is involuted, while the forward extension ends little more than half way along the zygomatic process.

The specimen of *Stenella euphrosyne* figured (Pl. 45) shows the tympano-periotic bones (TB) glued approximately in their natural position. It will be seen that the peribullary space separates the ear-bones from the basioccipital crest (BOC) and the paroccipital process (PAO). The ear bones have been glued by the " mastoid process " to the exoccipital bones (EXO) giving an appearance of contiguity with these which is artificial. In the natural state the process is separated from the adjacent bones by a fibrous ligament.

The falciform process (FP) is long and slender and its close relation to the tympanic bulla is well shown in the figure. Of the bony tube of the foramen ovale (FO) only a small vestige of the proximal part remains.

The basioccipital crests (BOC) are very slender and laminate and the paroccipitals (PAO) much reduced in thickness, being deeply excavated on their anterior faces.

The lateral and superior laminae of the pterygoid bones have almost entirely disappeared exposing considerable areas of the alisphenoid (ALS) and orbito-sphenoid (OS) bones. A narrow, irregular desquamation of the superior lamina (PT (SL)) occupies the mesial margin of the orbito-sphenoid. Of the pre-orbital extension of the pterygoid only a portion of the mesial lamina is present. A conspicuous upwardly and backwardly projecting recess in this region is bounded by the maxilla (MX) and the frontal (FR).

The distribution of the pre-orbital and post-orbital smoothed areas is very similar to that of *Tursiops truncatus*, but there is in addition a deep fossa lateral to the orbito-sphenoid which excavates the ventral surface of the orbital process of the frontal, producing a stout ridge of bone along the anterior margin of the frontal in this region. The pre-orbital recess is very deeply excavated and as in *Tursiops* there is an anteriorly attenuating fossa on the hinder end of the ventral surface of the maxilla. It may be noted that *Lagenorhynchus obscurus* shows the above mentioned features although less conspicuously.

The pterygoid hamuli (PTH) are completely excavated and slightly dilated; their ventral laminae is of a transluscent thinness. The internal walls of the hamular space are reinforced by trabeculae. The palatal aspect of each hamulus is bluntly keeled and the two hamuli approximate closely to each other in the middle line.

The palatal bones (PAL) are extensively exposed anteriorly and laterally to the pterygoid, but are deeply invaginated on their posterior faces by forward extension of the pterygoid cavities.

The tympano-squamosal recess (TSQR) is clearly delineated, its margin being for the most part strongly involuted.

In the adult skull of *Delphinus delphis*, examined but not figured, the tympano-periotic bones were missing and the cranial hiatus was partially occluded by secondary extensions of adjacent bones. The falciform process was comparable with that of *Stenella euphrosyne* and, as in the latter species, there was only a small remnant of the proximal end of the bony tube of the foramen ovale. The basioccipital crests were slender, laminate and very similar to those of *Stenella euphrosyne*.

The paroccipital processes were stouter and not so strongly excavated on their anterior face as in the latter species. They showed the characteristic depression on the ventral face which has been noted in some of the previously described species.

The lateral and superior laminae of the pterygoid had entirely disappeared, and, in the preorbital region, only the mesial lamina remained. In the distribution of the pre-orbital and post-orbital smoothed areas *Delphinus delphis* differs from *Stenella*, only in the maxillary region. Here, a conspicuous, deep, elongated fossa extends on the ventral aspect of the maxilla, diminishing in depth towards its termination near the anterior extremity of the rostrum.

The confluent aperture of the optic foramen, foramen rotundum and sphenoidal fissure was very much enlarged by resorption of the boundary margins of the orbito-sphenoid and alisphenoid.

The pterygoid hamuli were completely excavated and trabeculated as in *Stenella euphrosyne*. The posterior margins of the lateral laminae were extensively resorbed and the keeled ventral surfaces were fenestrated. The hamuli were in close apposition to each other in the middle line.

The juvenile specimen figured (Pl. 46) is in the main similar to the adult but with the following differences. There is a small remnant of the superior lamina of the pterygoid (PT (SL)) covering the mesial part of the orbito-sphenoid (OS). Of the orbital extension of the pterygoid, considerable portions of the superior and mesial laminae remain, and a delicate bridge of bone between these represents the last vestige of the lateral lamina (PT (LL)). Although in this respect the juvenile appears to be more primitive than the adult, the fenestration of the hamular laminae is of much greater extent than in the adult.

The palatine bones (PAL) are extensively exposed anteriorly and laterally to the pterygoid hamuli (PTH), and are quite strongly invaginated on their posterior face by forward extension of the hamular cavities.

The tympano-squamosal recesses (TSQR) are sharply defined but their borders are not strongly involuted as in *Stenella*.

STENIDAE. In the figured specimen (Pl. 24) of *Steno bredanensis* the tympano-periotic bones are wanting and the widely open cranial hiatus (CRH) is plainly visible. The falciform process (FP) forms a broad, spatulate extension of the squamosal (SQ). It is nearly contiguous with cancellated remnants of the bony tube of the foramen ovale (FO).

The basioccipital crests (BOC) are prominent, although slender and plate-like, and the paroccipital processes (PAO) show little excavation of their anterior or ventral faces.

The lateral lamina of the pterygoid bone is wanting except in the hamular region. The superior lamina (PT (SL)) remains as a broad, irregularly bounded plate which partly covers the lateral wing of the alisphenoid (ALS) and posterior portions of the orbitosphenoid (OS).

Of the orbito- pre-orbital extension of the pterygoid, only the mesial lamina remains, but there is a remnant of the lateral flexure of the palatine bone (PAL (LL)) in this region. The pre-orbital and post-orbital smoothed areas indicate coalescence lateral to the optic foramen, with the production of a wide, shallow fossa bounded anteriorly and posteriorly by two smoothed ridges of bone. In comparison with this fossa, the post-orbital extension of the smoothed area below the post-orbital process of the frontal (FR (PO)) is reduced in area. The pre-orbital smoothed area is extended onto the maxilla as in *Tursiops* and *Stenella*.

The pterygoid hamuli (PTH) are deeply excavated, strongly keeled ventrally and their mesial borders meet in the middle line. The palatine bones (PAL) are not extensively covered externally by the pterygoids but their posterior faces are invaginated by forward extension of the pterygoids.

The tympano-squamosal recess (TSQR) is clearly defined, the mesial and anterior margins of the glenoid cavity being slightly involuted. The anterior extension of the recess reaches the anterior limit of the zygomatic process of the squamosal.

The figured specimen of *Sousa plumbea* lacks the tympano-periotic bones (Pl. 25). The cranial hiatus (CRH) is exposed and there is little or no infilling of it by adjacent bones.

The falciform process (FP) is a broad lamina, having a thickening on its mesial aspect with a remnant of the distal end of the bony tube of the foramen ovale (FO). Considerable vestiges of the proximal end of this tube extend laterally from the alisphenoid (ALS).

The basioccipital crests (BOC) are prominent and stout as compared with those of *Steno bredanensis*, their mesial aspect not being excavated to any great extent. The paroccipital processes (PAO) on the other hand are slender, being excavated both anteriorly and ventrally.

The lateral and superior laminae of the pterygoid have entirely disappeared on the left side, but on the right side of the specimen figured a minute vestige of the lateral lamina persists, loosely articulated with the anterior face of the bony tube of the foramen ovale. The lateral aspect of the bony wall of the posterior nares is deeply recessed, the recess being formed dorsally by the ali- and orbito-sphenoid (ALS and OS) and ventrally by a strong involution of the mesial lamina of the pterygoid (PT (ML)).

No trace of the bony orbital extension of the pterygoid remains but there is a very deep recess extending dorsally and posteriorly between the anterior face of the frontal (FR) and the ventral surface of the maxilla (MX). As in *Inia geoffrensis* there is marked resorption of the ventral aspect of the post-orbital process of the frontal so that the maxilla is partially exposed in this region.

Apart from the feature just mentioned the distribution of pre-orbital and post-orbital smoothed areas is comparable with that of *Steno*, *Tursiops* and *Stenella*.

The pterygoid hamuli (PTH) are much fenestrated and a great part of the outer laminae has disappeared. The hamuli are deeply excavated ; numerous trabeculae extend from the inner to the outer lamina between the fenestrations.

The hamuli do not meet in the middle line and their outer surfaces are rounded rather than keeled.

The palatines (PAL) are widely visible and their posterior faces are interpenetrated by trabeculated extensions of the pterygoid hamuli.

The tympano-squamosal recess (TSQR) is very well defined, its margins being involuted both mesially and laterally. Its forward extension terminates some distance short of the anterior end of the zygomatic process of the squamosal.

A skull of *Lissodelphis borealis* became available[1] after the main work contained in this contribution had been completed. Distinctive features of the skull justify inclusion of a description at this late stage.

---

[1] By courtesy of Dr. Carl L. Hubbs, Scripps Institution of Oceanography, La Jolla, California.

The tympano-periotic bones are wanting and the cranial hiatus is partially closed. The falciform process is broad basally but extends into a much narrower, irregularly outlined, distal portion. The bony infundibulum of the foramen ovale is of sphenoidal composition only and is prominent.

The basioccipital crests are prominent, slender and plate-like. The paroccipital processes on the other hand are comparatively robust in ventral aspect. The anterior face of each of these processes is excavated by a distinctive cavity with an involuted margin.

The lateral lamina of the pterygoid bone is absent, but the smoothed areas of the skull base as a whole are characterized by their limited lateral extension. Thus the lateral wing of the sphenoid is short, and the smoothed area ends before reaching the spheno-parietal suture. The superior lamina persists as a narrow shelf in the pre-orbital region.

Whilst there is evidence of fusion of the pre- and post-orbital smoothed areas above the optic infundibulum there is practically no extension of the post-orbital lobe under the post-orbital process of the frontal. The pre-orbital smoothed area is extended onto the maxilla as in *Tursiops* and *Stenella*.

The pterygoid hamuli are deeply excavated, strongly keeled ventrally and their mesial borders meet in the middle line. They do not completely cover the palatine bones ventrally.

The tympano-squamosal recess is clearly defined, and the anterior extension of the recess reaches the anterior limit of the zygomatic process of the squamosal.

DISTRIBUTION OF AIR SPACES

The preceding account of the osteological features of the ventral aspect of the cetacean skull was undertaken on the assumption that the form of the various bones and the distribution of smoothed areas was associated with the state of development of the air sinuses connected with the tympanic cavity, and that these sinuses occupied the space between mesial and lateral laminae of bones such as the pterygoid, alisphenoid and palatine.

In most of the skulls examined the greater part of the lateral and superior laminae of these bones was absent, but it has been assumed throughout the account that at some stage in the evolution of the air sinuses the whole of all four laminae (see pp. 33–34) was present. In order to support this hypothesis it was decided to examine the distribution of the air sinuses in detail.

In most cases examination of the distribution of the air spaces involved injection of the latter with a polyester resin, and complete destruction of the soft parts by bacteriological maceration. By this method it was possible to obtain a three dimensional cast of the entire system of air spaces.

ODONTOCETI

In the examination of the River Dolphins the scarcity of material prohibited the destruction of any of the soft parts, so the sinuses of single specimens of *Stenodelphis* and *Inia* were injected with iodized oil and radiographed.

It is unfortunate that no specimen of *Platanista* was available, since this is the only species in which the lateral laminae of pterygoid, alisphenoid and squamosal are complete.

In *Stenodelphis* the greater part of these laminae is present, though much perforated, and it is this species which demonstrates most clearly the close association between the distribution of the air sinuses and the various extensions of the pterygoid bone. In addition, the sinus distribution in *Stenodelphis* provides a guide to the interpretation of sinus formation in species in which no trace of a lateral lamina can be found, and provides strong evidence that such a lamina may have been present at an earlier stage in the evolution of these species.

STENODELPHIS BLAINVILLEI

Pl. 20 is a dorso-ventral radiograph of the head of *Stenodelphis* after injection of the air sinuses with iodized oil. The opaque area shows the distribution of the air space in the horizontal plane and its five main components have been indicated by the names originally applied to the air sacs by Beauregard (*vide supra*). From the point of view of the evolution of these air spaces it is preferable to refer to them as sinuses.

The posterior sinus.

This can be seen as a small, opaque promontory occupying the position of the cavity in the paroccipital process. On the left side the sinus is incompletely filled with the injection medium so that the concavity of the paroccipital process is partly visible as a small, rounded transparent area.

The peribullary sinus

The shadow of the tympanic bulla is completely obliterated by a conspicuous, opaque area in the tympanic region. This opaque area marks the position of the peribullary sinus and demonstrates the extent to which the tympano-periotic bones are surrounded by the sinus. Most of the ventral region of this opaque area is the shadow-graph of that part of the peribullary sinus which lies dorsal to the tympanic bulla separating the latter from the bones of the cranium.

The pterygoid sinus

The name " pterygoid sac " was applied by Beauregard only to that part of the air sinus system which occupies the pterygoid hamuli, the remainder of the system anterior to the tympanic cavity being designated the anterior sinus. As, however, it can be shown that nearly the whole of the anterior air sinus system is associated with the extensions of the pterygoid bone previously described, the authors have found it necessary to include all but the most anterior extremities of the air sinus system in the description of the pterygoid sinus. In the radiograph this sinus is represented by the two conspicuous, wing-like, opaque areas which lie anterior to the tympanic region—as well as by a triangular projection which marks the position of one of the pterygoid hamuli. It will be noted that the opacity extends and partially fills the orbital and pre-orbital parts of the skull—occupying areas normally filled by the optic muscles. In this region there are numerous, irregular, semi-transparent patches. Comparing the distribution of opaque areas with the description and figures of the osteological characters in this area, it will be seen that the pterygoid sinus is almost exactly delineated by the boundaries of the pterygoid bone with all its distentions. The external surface of the sinus is almost completely covered by the thin, lateral lamina of pterygoid bone, although the latter is much perforated, and in the orbital region trabeculated and ruptured by a number of large fenestrations. The small, irregular, semi-transparent patches in the radiograph serve to indicate the cavitation of bone in this region.

Laterally the pterygoid sinus extends as far as the spheno-parietal suture, covering over the greater part of the lateral wing of the alisphenoid.

The anterior sinus

Throughout the descriptions which follow, the name anterior sinus will be applied only to parts of the air sinus system which extend further forward than the most anterior limits of the pterygoid bone. In *Stenodelphis* it is evident that no anterior sinus is present, and that, although the pterygoid lamina is fenestrated in the preorbital region, there has been little further extension of the sinus system.

The middle sinus

The radiograph shows a small, triangular, opaque protrusion extending antero-laterally from the general opacity of the peribullary sinus. This protrusion coincides with the position of the tympano-squamosal recess and marks the position of the middle sinus. Its concavity is shown by the semi-transparent streak along its central axis. Although obscured by the peribullary sinus, the point of emergence of this sinus from the tympanic bulla lies immediately dorsal to the tympanic membrane. It was this factor which led Beauregard to homologize it with the " glove finger " of the Mysticeti. This matter is discussed in Part I of Hearing in Cetaceans, Fraser & Purves (1955).

Inia geoffrensis

Pl. 22 is the dorso-ventral radiograph of the head of *Inia geoffrensis*—the air sinuses of the right side having been injected with iodized oil. The left side is not injected so that the relationship of the air spaces to the various osteological features can be seen.

The posterior sinus

This was the sinus through which the injection was made and its outline is partly obscured by the spillover of the injection medium. It can be seen as a small, reniform, opaque area occupying the position of the paroccipital process, the latter being distinctly outlined on the left side.

The peribullary sinus

The shadow of the tympano-periotic bones is shown on the left side—and from the right side of the radiograph it will be seen that the peribullary sinus completely surrounds this bone. As in the previously described species, the centre of the mass represents the air space between the periotic and the skull and coincides with the position of the cranial hiatus.

The pterygoid sinus

Passing forward from the tympanic region, two narrow, opaque areas can be seen lying along the mesial and lateral aspects of the basi-occipital crest. The mesial opacity demonstrates the form and direction of the Eustachian tube. The tube is widely dilated at its emergence from the tympanic bulla but is compressed mesolaterally as it proceeds forward in the direction of the choanae. The lateral opacity marks the beginning of the pterygoid sinus, and at a short distance forward from the tympanic region it widens laterally to form an irregular, opaque patch covering the area of the wing of the sphenoid bone. Anterior to this patch the opacity increases in dimension and divides eventually into three distinct lobes. The lateral lobe passes forward into the pre-orbital, orbital and post-orbital regions, the last extension continuing dorsally and posteriorly along ventral surface of the post-orbital process of the frontal. The mesial lobe invades the triangular concavity of the pterygoid hamulus.

The anterior sinus

The remaining lobe of the pterygoid sinus extends beyond the orbital and hamular lobes and penetrates the bony rostrum, passing forward inside this part of the skull for a short distance. As this extension is clearly beyond the limits of the bony part of the pterygoid it has been designated the *anterior sinus*.

With the exception of the anterior sinus none of the above-mentioned air spaces is covered laterally by a bony lamina—in this respect differing markedly from the condition found in *Stenodelphis*. Reference to the description of the osteological features on p. 45 shows that the disappearance of the lateral and superior laminae of the pterygoid hamuli, as well as the resorption of the ventral surface of the post-orbital process of the frontal, has occurred in close correlation with the extension and distension of the pterygoid sinus. The continuation of the anterior sinus between the bones of the rostrum is of interest in connection with the condition of this sinus in *Delphinus delphis* (see p. 70).

The middle sinus

The rounded concavity of the tympano-squamosal recess has not been filled with the injection medium, but on the basis of the evidence from *Stenodelphis* and other species hereafter to be described, it is very probable that the recess marks the position of the middle sinus.

PHOCAENA PHOCOENA

The air spaces of the specimen figured on Pl. 27 have been filled with polyester resin and the soft parts removed.

The posterior sinus

A small portion of this sinus can be seen protruding from the posterior aperture of the tympanic bulla. The sinus is not completely filled and would normally occupy the ventral concavity of the paroccipital process. Its normal outline has been indicated on Pl. 27 by a dotted line.

The peribullary sinus

Parts of the peribullary sinus can be seen lying between the tympanic bulla and the basioccipital crests but the greater part is concealed by the tympano-periotic. The latter bone is completely separated from the cranium on its superior aspect by an extension of the peribullary sinus. In the specimen figured, the deep cavity lying anterior to the periotic and postero-ventral to the falciform process is partly filled by a cavernous venous plexus.

The pterygoid sinus

The main mass of the Eustachian tube and the pterygoid sinus can be seen emerging from the anterior aperture of the tympanic bulla. That part which lies along the ventral edge of the mesial lamina of the pterygoid represents the lumen of the Eustachian tube though its outline is not clearly shown. The remaining mass passes forward round the ventral and anterior margins of the foramen ovale, partly covering the alisphenoid and extending into the orbital and pre-orbital regions of the skull and the pterygoid hamuli. On the exterior face of the mass can be seen small fragments of bone which represent respectively the remaining vestiges of the lateral laminae of the pterygoid and alisphenoid. (In *Platanista* these laminae form a continuous sheet of bone reaching from the pterygoid hamulus to the falciform process (see p. 44)). In the post-orbital region a small extension of the pterygoid sinus passes backwards over the alisphenoid, and dorsally and posteriorly under the post-orbital processes of the frontal bones in a manner similar to the condition found in *Inia geoffrensis*. As in the latter species, the surface of the bone is frequently resorbed in this area. Anteriorly the pterygoid sinus passes under the lateral lamina of the palatine bone and invades the pre-orbital concavity, a small lobe of the sinus passing ventrally for a short distance. The pre-orbital part of the pterygoid sinus gives off a diverticulum which passes upwards between the anterior aspect of the frontal and the ventral face of the maxilla.

The anterior sinus

There is no evidence of an extension of the pterygoid sinus beyond the pre-orbital region.

The middle sinus

This sinus has not been completely filled but its proximal position can be seen at its emergence from the aperture above the annulus of the tympanic bulla. The portion of the sinus figured occupies part of the tympano-squamosal recess and in its fully inflated state would occupy the whole of this recess.

LAGENORHYNCHUS ALBIROSTRIS

Pl. 38 shows the cast of the air spaces of left side of a skull of *Lagenorhynchus albirostris*.

The posterior sinus

Only a small portion of the posterior sinus can be seen protruding from the posterior aperture of the tympanic bulla, but the ventral recess on the paroccipital process, into which this sinus protrudes, can be seen in the figure. A dotted line indicates the normal limit of the sinus in its distended state.

The peribullary sinus

The ventral border of the peribullary sinus is visible between the mesial aspect of the tympanic bulla and the lateral aspect of the basioccipital crest. Between the periotic and the falciform process there is a fibro-venous plexus as in *Phocaena*. Close examination of the plexus shows that it contains, between the ramifications of the veins, a reticulate mass of minute, bony trabeculae, the significance of which will be understood when considering the progress of development of the peribullary sinus (see p. 79).

The pterygoid sinus

This sinus emerges from the bulla as a diverticulum of the Eustachian tube, and as the latter has not been injected, its relationship to the sinus has been indicated in Pl. 38. Anterior to the bulla the sinus passes round the ventral margin of the falciform process and the ventral and anterior margins of the foramen ovale. It continues along the lateral aspect of the mesial lamina of the pterygoid and enters the post-orbital, orbital and pre-orbital regions as well as the pterygoid hamuli. In the pterygoid region a considerable vestige of the lateral lamina of the pterygoid bones remains. In the specimen figured the vestige is limited in its backward extension to a point about 1 cm anterior to the falciform process but in most of the specimens examined the bony bridge is more complete although very much fenestrated. Pl. 37 shows the condition of this lamina (PT(LL)) in the majority of individuals examined. It should be noted that the alisphenoid is only partly covered by the sinus.

It has been emphasized that in *Phocaena phocoena* and in this species the posterior part of the pterygoid sinus passes ventral to the foramen ovale and round and above the ventral tip of the falciform process. Posterior to the dorsal and proximal parts of the latter process, the ventral concavity of the cranium is filled by a fibro-venous plexus and the alisphenoid is partly visible. These features are of importance in considering the progressive enlargement of the air spaces and will be referred to in the description of other species.

In the orbital region the pterygoid sinus passes over the ventral aspect of the orbito-sphenoid, being more laterally extended than this bone and forming the proximal part of the ventral floor of the orbit. The wide infundibulum for the optic and oculomotor nerves can be seen in the figure and it will be noted that its dorsal wall is formed by the ventral wall of the orbital process of the frontal. Posterior and anterior to this infundibulum are the post-orbital and pre-orbital extensions of the pterygoid sinus. The post-orbital extension is much more limited posteriorly than in *Inia* and *Phocaena* and has, instead of the long attenuated diverticulum which in the latter two species lies under the post-orbital process of the frontal, a small, half-oval protrusion. The pre-orbital extension is also more limited than in *Phocaena* and is confined to the deep concavity which surrounds the pre-orbital foramen. There is no anterior sinus.

The middle sinus

This has been well injected and shows the typical form which the sinus takes, with few variations, in nearly every species of cetacean. The air space is exactly delineated by the tympano-squamosal recess and its lateral margin lies in the deep groove formed by the involuted margin of the glenoid fossa.

GLOBICEPHALA MELAENA

The posterior sinus

No part of the posterior sinus has been injected but its position in the saucer-like depression in the paroccipital process is marked by a dotted line (Pl. 34).

The peribullary sinus

A part of the peribullary sinus lies between the tympanic bulla and the basioccipital crest and shows the irregular, rugose form of its ventral edge. The significance of this irregular outline, which is very conspicuous in some other species, e.g. *Tursiops* (Pl. 44), may be seen by comparing it with the condition of the bone of the lateral aspect of the basioccipital crest in the primitive cetacean *Platanista* (Pl. 17). In the latter species the basioccipital crests are stout and the lateral aspect of the bone shows extensive cavitations and a minutely cancellated structure. The proximity of this finely cancellated bone to the peribullary spaces in *Platanista* suggests that the bone and air spaces are intimately connected and that the cancellation is due to resorption of bone with the progressive enlargement of the sinus. The thinness of the basioccipital crest and the rugose surface of the air sinus cast in *Globicephala* indicate that the peribullary sinus in the more specialized odontocetes has been developed at the expense of the osseous content of the basioccipital crest (see p. 80). A forward extension of the peribullary sinus can be seen occupying the deep cavity anterior to the periotic and should be compared with the fibro-venous plexus which is found in this area in *Phocaena phocoena* and *Lagenorhynchus albirostris*.

The pterygoid sinus

The relationship between the pterygoid sinus and the Eustachian tube is well shown in Pl. 34. Both structures emerge from the involucral anterior fissure of the tympanic bulla but diverge just anterior to the tip of the falciform process. The connection between the lumen of the Eustachian tube and the pterygoid sinus has been fully described by Beauregard (see p. 8). From Pl. 34 it will be seen that the Eustachian tube lies ventral to the pterygoid sinus and lateral to the basioccipital crest until it reaches the posterior margin of the choanae, thereafter passing by way of the deep notch in the pterygoid bone along the lateral wall of the posterior nares. The ventral aspect of the internal cast of this tube shown in the figure is marked by a series of obliquely-disposed, deep fissures which mark the position of those valvular folds in the lining walls of the Eustachian tube which have been fully described by Anderson, Beauregard, Boenninghaus and others. Anterior to the bulla the pterygoid sinus passes, as in the previously described species, along the mesial aspect of the ventral part of the falciform process, and round the ventral and anterior margins of the foramen ovale. Thereafter the sinus expands conspicuously and completely fills the angle formed by the mesial lamina of the pterygoid bone and the external ventral wall of the cranium. In this species the alisphenoid bone is completely covered and the pterygoid hamuli widely dilated. There are no vestiges of the lateral lamina of the pterygoid on the external face of the sinus. Close examination of this external face reveals that it is marked by very numerous, minute indentations and folds, the significance of which will be understood in relation with the histology of the sacs. As in *Lagenorhynchus* the hamuli are completely filled.

Further forward the arrangement of the sinus is very similar to that in *Lagenorhynchus albirostris*. As in the latter species, there are three distinct portions in this region; (1) a post-orbital lobe which lies along the posterior margin of the optic infundibulum but which does not, as in all the previously described species, give off a dorsally directed diverticulum under the ventral face of the post-orbital process of the frontal ; (2) an orbital part which covers the orbito-sphenoid and forms the ventral closing wall of the optic infundibulum ; (3) a pre-orbital lobe which fills the concavity round the pre-orbital foramen and extends laterally a short distance along the anterior margin of the optic infundibulum. As in the previous species the dorsal wall of this infundibulum is formed by the frontal, a considerable portion of the latter bone being visible in Pl. 34 between the pre-orbital and post-orbital lobes of the pterygoid sinus. There is no anterior sinus.

The middle sinus

The middle sinus has not been injected but its position is marked by a dotted line in Pl. 34.

GRAMPUS GRISEUS

The posterior sinus

The position of this sinus, though not well injected, can be seen from Pl. 42. The sinus occupies the concavity on the antero-ventral aspect of the paroccipital process.

The peribullary sinus

This can be seen in Pl. 42 occupying the space between the mesial aspect of the tympanic bulla and the lateral aspect of the basioccipital crests, as well as the concavity behind the falciform process. The rugose character of its external borders should be noted.

The pterygoid sinus

As in previously described species, the pterygoid sinus emerges from the tympanic bulla in conjunction with the Eustachian tube. The latter is not shown in the plate since its internal cast was so delicate and flattened meso-laterally that it became detached before the photographs were taken. Sufficient of the narial part of the tube remained to indicate that its form and direction were similar to those of the Eustachian tube of other species and have been so indicated. The sinus widens abruptly in front of the falciform process, sweeps round the ventral and anterior margins of the foramen ovale and covers the whole of the alisphenoid. In the region of the foramen ovale there are numerous, posteriorly-directed, lobulated diverticulae which pass over the dorsal margin of the foramen and become contiguous with the anterior extremity of the peribullary sinus. As in *Globicephala*, the sinus is very expansive and fills the angle between the mesial lamina of the pterygoid and the external wall of the cranium. The pterygoid hamuli are entirely filled and even more widely dilated than in *Globicephala*. In respect of the orbital extensions of the sinus there are several major differences between the arrangement in this species and that in all the previously described specimens. The lateral extension of the sinus which covers the ventral aspect of the orbito-sphenoid is very much wider and more extensive than in *Globicephala* and forms a greater part of the floor of the orbit. The post-orbital lobe is also larger and has a wide diverticulum under the post-orbital process of the frontal. The pre-orbital lobe is equally developed and is not confined merely to the concavity which surrounds the pre-orbital foramen but continues laterally almost as far as the lateral limit of the frontal. In Pl. 42 a narrow strip of the frontal bone can be seen separating the post-orbital and pre-orbital lobes and forming the roof of the optic infundibulum, but in another injected specimen (not figured) the frontal bone is obliterated in this region by coalescence or close contiguity of the two lobes. In this manner the optic nerves and muscles have been completely surrounded in the latter specimen by a continuous band of air sinus. The extremities of all the lobes hitherto mentioned show the peculiar lobulated form which was noted on the diverticulae round the dorsal margin of the foramen ovale.

The anterior sinus

It will be seen from Pl. 42 that the pterygoid sinus not only fills the deep fossa on the lateral aspect of the palatine bone (see p. 57 and Pl. 41) but extends anteriorly under the maxilla for a short distance.

The middle sinus

The middle sinus is well shown in Pl. 42, partly filling the tympano-squamosal recess. It will be noted that it consists of two lobes, one of which is directed laterally round the posterior border of the glenoid fossa, and the other directed antero-laterally round the anterior margin of the same fossa and following the anterior border of the zygomatic process of the squamosal. The whole sinus is minutely lobulated at its external borders in a manner which is characteristic of many species of odontocetes.

Tursiops truncatus

The posterior sinus

The relationship of the posterior sinus to the tympanic bulla and the depression on the paroccipital process are well illustrated on Pl. 44, and the rugosity of the external surface should be compared with that of the bone in this area.

The peribullary sinus

This is shown at its ventral extremities, mesially, between the lateral aspect of the basioccipital crest and the mesial aspect of the tympanic bulla, and anteriorly behind the curved posterior border of the falciform process. As in other species. the surface is irregularly contoured.

The pterygoid sinus

This sinus emerges from the anterior aperture of the tympanic bulla in conjunction with the Eustachian tube, the proximal end of which is shown in the plate. Here again, owing to the laterally compressed state of the tube, its lumen has not been injected but its approximate direction has been indicated. The pterygoid sinus passes over the tip of the falciform process, round the ventral and anterior margins of the foramen ovale, spreading out laterally, ventrally and anteriorly, filling the angle between the mesial lamina of the pterygoid and the ventral aspect of the cranium, and completely covering the alisphenoid. As in Risso's Dolphin there are posteriorly directed diverticula passing round the superior margin of the foramen ovale so that the mandibular branch of the 5th nerve is entirely surrounded by air space. More anteriorly the arrangement is very similar to that in *Grampus griseus*, although the pterygoid hamuli are not as widely dilated as in the latter species. The orbital, pre-orbital and post-orbital lobes are all well developed, the orbital lobe covering the orbito-sphenoid and forming a conspicuous laterally projecting ventral boundary to the optic infundibulum. The pre-orbital and post-orbital lobes are well extended and the latter spreads dorsally under the post-orbital process of the frontal. As in one of the specimens of *Grampus* the two lobes are closely contiguous and partly coalesced proximally so that no part of the frontal bone is visible between them. The optic nerve, like the mandibular branch of the trigeminal, is thus entirely surrounded by an air cavity. The contiguous pre-orbital and post-orbital lobes extend almost to the lateral limit of the frontal bone and their extremities are deeply cavitated with small, irregular diverticula as in *Grampus*.

The anterior sinus

With respect to the anterior sinus, *Tursiops truncatus* shows a more advanced state of the development of the air spaces than any of the previously mentioned species. The extent of the sinus is not fully demonstrated by the injection in Pl. 44 but its prolongation beyond the pre-orbital foramen has been indicated. The deep recess on the ventral aspect of the maxilla marks the boundary of the sinus when fully distended.

The middle sinus

Pl. 44 shows the form of the middle sinus and its exact point of emergence from the tympanic bulla. It will be noted that it originates immediately dorsal to the tympanic annulus and the sigmoid process. The sinus consists of two lobes, one passing laterally round the posterior border of the glenoid fossa, and the other following the course of the anterior wing of the tympano-squamosal recess.

DELPHINUS DELPHIS

The arrangement of the air sinuses in this species was figured by Anthony and Coupin (1930), but not described in detail. A summary of Beauregard's description is given on p. 8.

The posterior sinus

This sinus is not fully injected but its contiguity with the depression on the paroccipital process is demonstrated in Pl. 47.

The peribullary sinus

The ventral limits of the peribullary sinus are indicated in Pl. 47 lying between the mesial aspect of the tympanic bulla and the basioccipital crests, and in the cavity behind the falciform process.

The pterygoid sinus

The relationship between the pterygoid sinus and the Eustachian tube is demonstrated. The latter widens considerably after its emergence from the bulla and continues forward along the ventro-lateral border of the mesial lamina of the pterygoid, becoming narrower and more compressed meso-laterally until it reaches the notch in the latter bone. Having passed through the notch, its lumen becomes very attenuated and passes dorsally along the mesial aspect of the lateral wall of the posterior nares for a short distance, thereafter turning at first mesially and then ventrally to open into the choanae. The cast is marked ventrally by a series of oblique grooves which indicate the position of the valvular folds in the mucous membrane of the tube, (see p. 6). The pterygoid sinus widens out in front of the bulla, its ventral border lying mesial to the Eustachian tube and its dorsal border passing round the ventral and anterior margins of the foramen ovale. The alisphenoid is completely covered and there is a posteriorly directed, lobulated diverticulum which passes round the dorsal border of the foramen ovale. The mandibular nerve is thus surrounded ventrally, anteriorly and dorsally by the pterygoid sinus and posteriorly by the peribullary sinus. The pterygoid hamulus is filled by a ventrally directed lobe of the sinus which passes over the lateral aspect of the

Eustachian tube near the latter's entry into the pterygoid notch. This arrangement is well shown in Pl. 34 which figures the pterygoid sinus of *Globicephala*. The orbital portion is fairly prominent, covers the orbito-sphenoid and forms the ventral boundary of the optic infundibulum. The pre-orbital and post-orbital lobes are well extended laterally and unite above the optic infundibulum to form its dorsal boundary. The optic nerve is therefore completely surrounded by an air space as was observed in *Tursiops truncatus* and in one member of the species *Grampus griseus*. The dorsally directed diverticulum which extends over the ventral aspect of the post-orbital process of the frontal is wide, though fairly short.

The anterior sinus

In the degree of development of the anterior sinus *Delphinus delphis* exceeds every other known species of cetacean, although there is evidence from its osteological features that the recently described species *Lagenodelphis hosei* closely approaches its position. The soft parts of the latter species were not available but it may be assumed that the arrangement of the sinus would approximate to that of *Delphinus*. The anterior sinus of *Delphinus* takes the form of a wide, elongated sac which fills in the whole pre-orbital region and projects forward, tapering gradually to occupy the deep groove in the maxilla, and continuing anteriorly in the adult for about two thirds of the length of the rostrum.

The middle sinus

A small part of the middle sinus can be seen in Pl. 47, protruding from the tympanic bulla, its shape in the fully distended state being indicated by a dotted line. It fills the tympano-squamosal recess.

MESOPLODON BIDENS

The air sinus system of *Mesoplodon bidens* has been described by Anthony & Coupin (1930) but as this description does not emphasize the striking differences between the arrangement of the sinuses in ziphioid whales generally on the one hand, and those of other odontocetes on the other, the authors have decided to review the structure in the light of these differences. Anthony & Coupin distinguish several lobes of the pterygoid sinus but as these are in no way homologous with those found in other odontocetes their names cannot be adopted in the present work.

The posterior sinus

This is relatively inconspicuous in Pl. 12 as the sinus is not fully injected. Nevertheless its extent is confined within the boundaries of a smooth area on the pars mastoidea of the tympano-periotic. There is no evidence of the saucer-like depression in the paroccipital process.

The peribullary sinus

In spite of the close contiguity of the tympanic bulla with the basioccipital crest the ventral edge of a laterally compressed lobe of the peribullary sinus can be seen on Pl. 12 interposed between the above mentioned bones. It should be noted that its outline is quite smooth and regular, showing none of the rugosities which were seen on the edge of the sinus in many of the Delphinidae. There is no extensive excavation of the anterior aspect of the paroccipital process, the latter being massive and of a simple, nodular form. The falciform process is in close apposition with the anterior border of the tympanic bulla so that no part of the peribullary sinus is seen between the two bones, and there appears to be little distension of the anterior parts of the sinus generally.

The pterygoid sinus

With regard to the form of the pterygoid sinus *Mesoplodon bidens* differs from all the cetaceans hitherto described. It emerges with the Eustachian tube from the anterior end of the tympanic bulla and passes round the ventral and anterior borders of the foramen ovale. The superior margin of the latter foramen is not surrounded by the sinus, its wall being formed by the ventral surface of the alisphenoid bone. This posterior part of the sinus lies against the mesial lamina of the pterygoid bone and is insignificant in extent compared with the same region in the previously described species. Anteriorly, the sinus expands to form a single, great, bulbous lobe which is homologous solely with that part of the sinus which in the cetaceans already described passes ventrally to fill the pterygoid hamulus. Mesially, it is in relation to the great fossa on the lateral aspect of the conspicuously enlarged hamuli. Dorsally, it is in relation to the long narrow shelf of the pterygoid bones which stretches from the pre-orbital region to the tympanic (see p. 40). There are no traces of a lamina of bone on its exterior face and the latter is quite smooth and regular in contour, showing none of the minute lobulations which are to be found on the surface of the sinuses in all the other described species. The significance of this smoothness of contour is discussed on p. 40. There are no pre-orbital nor post-orbital lobes of the sinus nor any extension of the latter above the narrow lateral ridge of the pterygoid bone. The optic infundibulum is formed entirely of bone, its ventral aspect being bounded by part of the lateral ridge of the pterygoid and its dorsal aspect by the frontal; it is therefore true to say that none of the cranial nerves is completely surrounded by an air space, as in some of the other odontocetes.

As previously stated, there is no pre-orbital lobe of the pterygoid and therefore no anterior sinus. The pre-orbital foramen is bounded only by its associated bones.

The middle sinus

This is similar in shape to that of the other odontocete species. It emerges from the tympanic bulla above the tympanic annulus and invades the tympano-squamosal recess. Its two lobes pass respectively posteriorly and anteriorly to the glenoid fossa.

MYSTICETI

BALAENOPTERA ACUTOROSTRATA

The arrangement of the air sinus system was fully described by Beauregard (1894) but for convenience of comparison with that of the Odontoceti his account is repeated below. He states—" In order to give an account of the tympanic cavity and its annexes we made an injection of wax—through the external orifice of the Eustachian tube. After solidification we sawed through the tympanic bulla horizontally and took off the whole of the lower wall. The passage of the Eustachian tube—very nearly rectilinear and directed backwards and outwards passes between the angle formed by the inferior border of the sphenoid and the digitiform process of the pterygoid. It intrudes thereafter into the vast pterygoid sinus. This sinus is therefore to be considered an enlargement of the posterior extremity of the Eustachian tube. The communicating orifice of this canal is provided with a valve, formed by a tongue of membrane hanging from the upper wall and, in the neighbourhood of the orifice, the dense fibrous tissue which covers the lower surface of the cranium and closes the sinus ventrally, is thrown into numerous folds and pockets, which we found filled with injection and are therefore continuous with the Eustachian tube. The injection filled at the same time the vast pterygoid sinus and the tympanic cavity proper. These two cavities are in communication by the anterior orifice of the bulla, or rather by the anterior extremity of the long opening situated between the two lips of the bulla. The relationship between the pterygoid sinus and the Eustachian tube on the one hand and the latter with the tympanic cavity shows that this sinus should be regarded as the homologue of the anterior sinus which we have described in the dolphins." The present writers find it more convenient to regard the whole of this structure as the pterygoid sinus since it is entirely delineated by the pterygoid bones (see p. 8). Beauregard goes on to describe how the injection passed into three other cavities.

" *No.* 2. A large cavity which corresponds with the whole of the upper and inner surfaces of the bulla but does not lie underneath it. We refer to it under the name Peribullary Sinus.

" *No.* 3. A small diverticulum situated at the posterior extremity of the bulla in the groove formed by the lower lateral border of the occipital. It is therefore a Posterior Sinus."

No. 4. The fourth sinus described by Beauregard is the conical diverticulum known as the " glove finger " which he homologized with the middle sinus of the Odontoceti. The author bases his identification on the fact that the glove finger protrudes from the tympanic annulus which in the Odontoceti appears to be divided into two segments, the upper segment forming the boundary of the proximal end of the middle sinus. It should be pointed out, however, that the glove finger is covered exteriorly by epidermis whereas the middle sinus of the Odontoceti is covered externally by periosteal tissue. Fraser & Purves (1945) demonstrated the similarity between the glove finger and the non-fibrous portion of the tympanic " membrane " of the Odontoceti, the two structures being homologized with the pars flaccida of the tympanic membrane of terrestrial mammals. The division of the tympanic annulus into two segments is peculiar to the Odontoceti and it must be assumed that the upper segment from which the middle sinus protrudes has been produced by rupture of the dorso-lateral wall of the bulla. The present writers have been unable to find any structure in the Mysticeti comparable with the middle sinus and there is no recognizable tympano-squamosal recess (see p. 9).

In this and in the previous chapter, relationship has been demonstrated between the air sinus system and the contouring of the base of the skull in a number of cetaceans. The evidence is sufficiently conclusive to enable a reconstruction to be made of the air sinus systems of species which were not available in the flesh. It should be pointed out that the indications of the distribution of air sinuses shown in Pls. 5–47, with the exception of those in which there is the direct evidence of the plastic injection, have been determined by the distribution of the smoothed areas on the ventral surface of the skull and the evidence of partial disappearance of the bones themselves. The limits of the air sacs in all the plates are indicated by a broken line and the unossified regions by white stippling. The limitations imposed by representing in two dimensions that which is three dimensional should be borne in mind when studying the plates.

The evolution of air sinuses in the Cetacea generally is discussed in the following chapter in which simplified, schematic diagrams are used to illustrate their distribution. If comparison is made between these diagrams and the photographs of the air spaces it should be remembered that the latter are viewed obliquely, whilst the former are normal to the lateral and dorso-ventral aspects.

It is the writers' opinion that however limited or extensive the various components of the air sinuses may be, they represent a system, which in its early evolutionary stages was covered by bone, and that, whether or not the osseous content of the bone remains, the closing fibrous walls of the sacs are periosteal in origin.

The absence of the conventional maxillary, frontal and sphenoidal air sinuses in cetaceans, and the general distribution of air sacs in this order, appears to give some justification to Monro's (1785) homology (see p. 5) but the more likely explanation seems to be that if the normal mammalian sinuses were ever present in cetaceans their positions have been occupied by middle ear extension.

EVOLUTION OF THE AIR SACS

Before going on to a discussion of the function of the air sinuses and their importance in connection with the inter-relationships of the Cetacea it is necessary to consider the possible mode of evolution of the sinuses from the typical mammalian middle ear. The periotic portion of the tympano-periotic bones of terrestrial mammals forms a part of the cranial wall and is closely contiguous with adjacent cranial bones. Further, the tympanic cavity is simple and circumscribed and communicates directly with the narial cavity through the Eustachian tube. The kangaroo, bat, tapir, horse and hyrax are notable exceptions to this generalization. In the Cetacea the tympano-periotic bones are excluded and more or less distant from the cranial wall, and the tympanic cavity is extended into an elaborate system of sinuses.

The constitution of the air sac system, the dissociation of the tympano-periotic bones from the skull and the modifications of the skull itself are already present in the foetus and their genetical origin is obvious. Nevertheless, these modifications can be interpreted in terms of the mechanical effect of pressure and tension on bone. The natural condition of rarification of bones is so strikingly similar to the abnormal conditions found in bone subjected to excessive mechanical stresses, that some principle such as the so-called " Baldwin Effect " must be invoked to link the natural to the abnormal. It has been recognized for a long time that of all the tissues comprising the body of an animal, with the single exception of blood, bone is the most plastic, in the sense that it is the most subject to modification under mechanical stresses. According to Weinmann & Sicher (1947) who quote Wolff's Law of transformation of bone, the effect of increased pressure or tension on bone can be summarized as follows :

" 1. Increase of pressure beyond the limits of tolerance leads to destruction of bone by resorption.

" 2. Within the limits of tolerance an increase of the normal forces of pressure or tension leads to formation of new bone.

" Increased pressure in such instances acts upon a bony surface which is normally subjected to pressure and able to withstand it. Such areas are often characterized by a covering of avascular tissue. Increased traction in an area adapted to traction will also lead to acquisition of bone. *Even slight pressure will lead to resorption of bone if forces are applied to an area which is normally neutral, or under tension and consequently not able to withstand pressure. One characteristic of this adaptation may be the covering of the bony surface by vascularized periosteum.*"

The most violent changes in pressure in the middle ear experienced by a terrestrial mammal are expressible in terms of small fractions of an atmosphere. In aquatic mammals a diving depth of even a few feet can bring about a rapid increase of pressure and a depth of 30 ft. increases the pressure by one atmosphere. Cetaceans are known to dive to much greater depths than that represented by one atmosphere, and it is not surprising therefore that during the acquisition of an aquatic habit a chain of evolutionary adjustments has occurred to meet the effects of the stresses imposed.

If the distribution of the muscles as described above is compared with that of the air sacs, it will be seen that there is a close association of the lobes of the sinus system with that of the insertion of various important muscles. Thus the peribullary sinus is associated with the sterno-mastoid, the middle sinus with the masseter, the pterygoid sinus with the tensor palati and lateral pterygoid muscles, the post-orbital lobe with the temporal and orbital muscles, the pre-orbital lobe and the anterior sinus with the mesial pterygoid.

As previously stated, it is considered that the regions of insertion of these muscles were originally osseous in nature, as in *Platanista*. This points to an early situation where, after the formation of an inter-laminar air space there would be pressure beyond the normal on the inter-laminar face of bones such as the pterygoid with resulting resorption of bone on that face. The lateral lamina being thus reduced in thickness would be inadequate to withstand the normal tension of the muscle, unless, in accordance with Wolff's Law, new bone were formed on the external face. It is easy to see how by such a process of resorption internally and of deposition externally gradual dilation of the pterygoid bone would take place, which itself would produce tension parallel with the plane of the lamina. The condition in which the osseous content of the lamina is completely removed indicates an end point at which the pressure effect is always in excess of that of tension.

DISSOCIATION OF THE TYMPANO-PERIOTIC BONES FROM THE SKULL

The dissociation of the tympano-periotic bones from adjacent skull bones and the development of air sinuses are not of equal extent in all cetaceans. The process shows a gradation of stages involving the various genera in the Order. Text-fig. 13 gives schematic representations of the variations observed. In a terrestrial mammal, the tympano-periotic bones (TB and PE) are fused with the squamosal (SQ), and the mastoid process (MAS) is sutured with the paroccipital process (Text-fig. 13*a*). The periotic (PE) forms part of the wall of the cranial cavity but portions of it are separated from direct contact with the latter by the superior and inferior petrosal sinuses. No part of the tympanic cavity separates the periotic from cranial bones adjacent to it.

In *Caperea* (Text-fig. 13*b*) the greater part of the pars mastoidea (MAS) of the tympano-periotic is not fused but is loosely inserted between the squamosal and the basioccipital process. There is however a portion of the squamosal immediately anterior to the pars mastoidea, of a rugose and laminated appearance, very similar to that of the pars mastoidea itself. With the exception of the condition found in *Kogia* this characteristic region of bone is distinguishable to a greater or lesser extent in all the cetaceans examined. It is situated in the angle formed by the antero-lateral border of the paroccipital process and postero-lateral margin of the glenoid fossa. In *Platanista*, its anterior extent is indicated by a distinct but incomplete suture, and its posterior limit by what is commonly regarded as the squamo-paroccipital suture. In other cetaceans the anterior suture is not clearly defined although the region itself is distinguishable from the adjacent squamosal element. Since in the Mammalia generally the pars mastoidea intervenes between the zygomatic process of the squamosal and the paroccipital process, it is justifiable to regard the area of bone referred to above as a mastoid element.

The periotic of *Caperea* is in contact with the cranial cavity but is surrounded by a dorsal extension of the tympanic cavity. Another extension of the tympanic cavity is accommodated between the bulla and a raised portion of the basioccipital bone (the basioccipital crest (BOC)). Although no soft parts of *Caperea* were available for examination, the skull characteristics of the ear region (see p. 37) together with what has been observed in other mysticetes (see p. 74) indicate that the extensions of the tympanic cavity referred to above are occupied by the peribullary sinus. The postero-lateral extension of the cranial cavity (p. 29) can justifiably be regarded as occupied by the enlarged petrosal sinuses, which have become confluent as a consequence of the partial withdrawal of the periotic from the cranial wall.

In *Balaena* (Text-fig. 13*c*) the portion of the mastoid (MAS) which is fused with the squamosal (SQ) is very much greater than in *Caperea*. The base of the cranium of *Balaena* is greatly extended laterally, the paroccipital and zygomatic processes being enormous in comparison with those of *Caperea*. Correlated with this the unfused portion of the mastoid is also extended laterally and attenuated. The fused

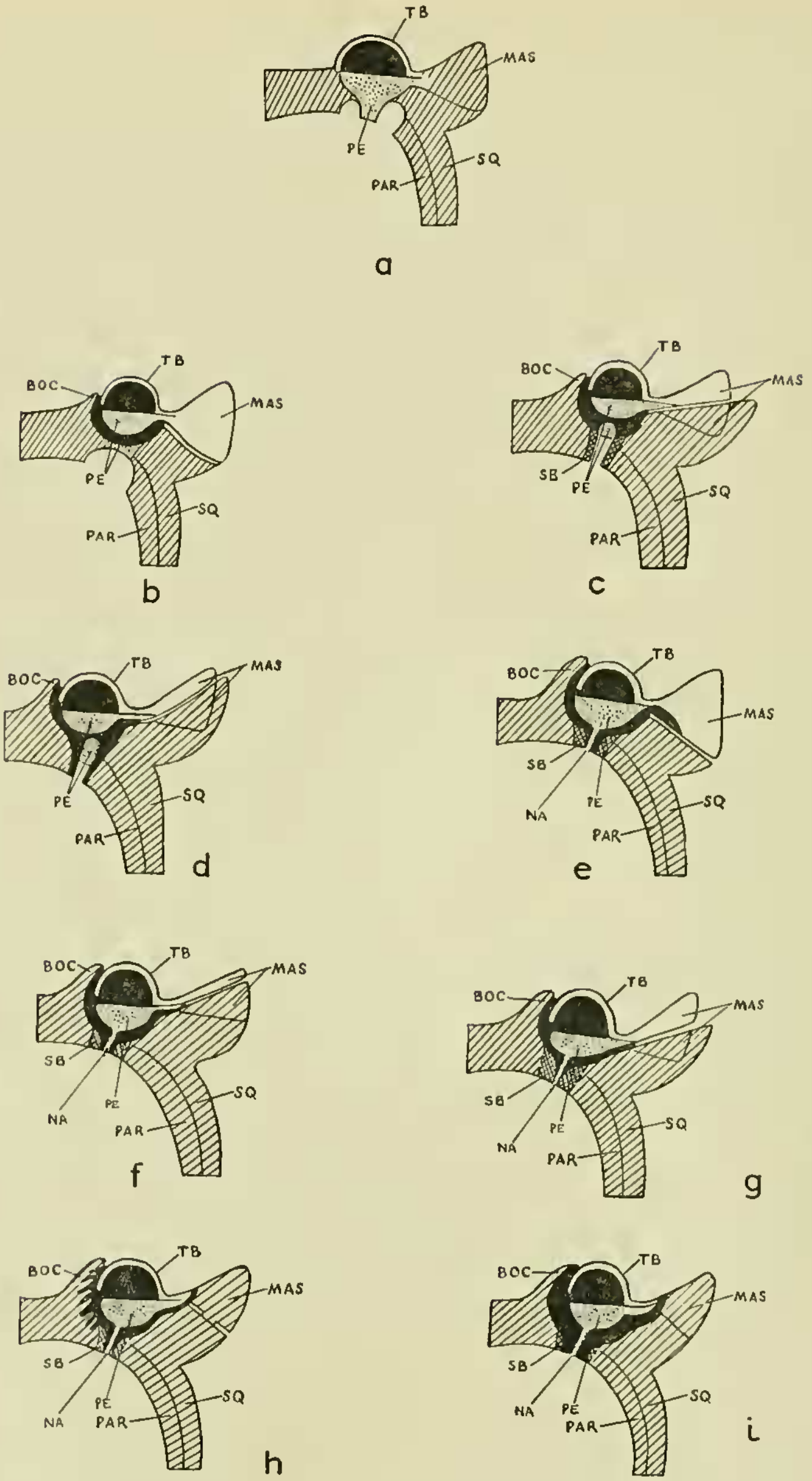

FIG. 13. Diagrams to show progressive dissociation of tympanoperiotic bones from adjacent bones of the skull in the Cetacea.

a. Terrestrial mammal. b. *Caperea*. c. *Balaena*. d. *Balaenoptera*. e. *Kogia*. f. *Physeter*. g. *Ziphioidea*. h. *Platanista*. *i*. Delphinoidea.

Note. The black areas indicate air space.

portion of the mastoid constitutes that which in *Caperea* is continuous with the periotic so that the unfused portion appears to be of tympanic association only.

The dissociation of the tympano-periotic from the bones of the cranium is increased by the further development of the peribullary sinus. The periotic, although not separated from the cranial cavity by the above sinus, is elongated dorso-ventrayll and situated at the external end of a long infundibulum (see *Caperea* above). The petrosal sinuses appear to be confined within the limits of this infundibulum. The latter is reduced in diameter by secondary growth of its boundary bones (SB). In association with the ventral extension of the peribullary sinus the basioccipital crest (BOC) is more prominent than in the previously described genus.

In *Balaenoptera* (Text-fig. 13*d*) the amount of the mastoid (MAS) fused with the squamosal (SQ) is even more extensive than in *Balaena*, the unfused portion being a long, spatulate extension of the tympanic (TB) with a much shorter extension of the periotic (PE) fused to its dorsal face. The periotic is still more elongated dorso-ventrally than in *Balaena* but its dorsal aspect is still a component of the cranial wall. The peribullary sinus envelops the periotic as far dorsally as the cranial cavity, and, from the osteological evidence, the vascular supply of the sinus is undoubtedly merged with the petrosal sinus (see p. 29). Laterally the peribullary sinus is insinuated as an extension between the periotic pars mastoidea and the squamosal. The basioccipital crest is more prominent than in *Balaena* and its lateral face is more obviously excavated than in the last named genus.

Turning to the Odontoceti, a similar series of progressive changes can be observed which, so far as the mastoid is concerned, is parallel to that of the Mysticeti, but in the development of the peribullary sinus goes much further. Considering the Physeteroidea, *Kogia* (Text-fig. 13*e*) resembles *Caperea* in that the greater part, if not the whole, of the triangular mastoid (MAS) is not fused to the squamosal (SQ). The apparent attachment of the mastoid exclusively to the tympanic bone is due to the erosion of the periotic pars mastoidea by the peribullary sinus. The peribullary sinus not only encircles the periotic but, extending onto its dorsal surface, intervenes between it and the cranial cavity. The dorsal surface of the periotic presents the smooth, rounded appearance which is characteristic of the Odontoceti. The peribullary sinus is greatly developed between the tympano-periotic (TB and PE) and the basioccipital crest (BOC) which is more prominent than in any of the Mysticeti. The vascular system of the peribullary sinus must be considered as confluent with the petrosal sinuses (see p. 29).

In *Physeter* (Text-fig. 13*f*) a considerable portion of the mastoid (MAS) is fused to the squamosal. The unfused portion is laminated (laminations not shown in figure). Only a small portion of the periotic pars mastoidea is unfused. The peribullary sinus, as in the Odontoceti generally, envelops the periotic, intervening between it and the cranial cavity. Its vascular system is confluent with that of the petrosal and cavernous sinuses. These do not lie entirely within the cranial cavity and indeed intrude into the bulla in the form of the enigmatic cavernous tissue body which contains the "degenerate" internal carotid artery (see p. 29).

In the Ziphiidae (Text-fig. 13*g*) *Berardius*, *Mesoplodon* and *Ziphius* resemble *Physeter* both with regard to the extent of the peribullary sinus, and consequently with regard to the degree of separation of the tympano-periotic (TB and PE) from the skull. Only *Hyperoodon* differs from the remaining ziphioids in the respect that the unfused portion of the mastoid is very much reduced in its dimensions.

In some respects *Platanista* (Text-fig. 13*h*) occupies an intermediate position between the physeterids and the delphinids. Nearly the whole of the mastoid (MAS) is fused to the squamosal (SQ) although the remains of a squamo-mastoid suture are clearly discernible. The unfused pars mastoidea of the tympano-periotic represents only a small portion of the whole mastoid and in its proportions is comparable with normal delphinid condition. The part of the peribullary sinus lying above the periotic is even more restricted than in the ziphioids. The proximity of the periotic to the squamosal has given rise to the erroneous impression (Hyrtl and Yamada) that the two elements were fused together. The basioccipital crest (BOC) is similar in its general form to that of the ziphioids but its lateral aspect is extensively pneumatized by extensions of the peribullary sinus. This condition is a precursor of that common in the delphiniids in which there is such an extension of the pneumatization with the merging of individual air cavities and the further attrition of bone that the basioccipital crest is reduced to a thin lamina. The vascular system of the peribullary sinus is confluent with the petrosal venous sinuses. Above and anterior to the periotic there is a considerable hiatus in the cranial wall, except in old specimens in which the hiatus is partially filled by secondary bone. In this respect *Platanista* resembles most of the Delphinidae. *Stenodelphis* and *Inia* show a condition of the mastoid resembling that of the delphinids.

Considering the delphinid genera (Text-fig. 13*i*), whilst there is variation in the degree of development of the peribullary sinus, in general it can be stated that they show a considerably more advanced evolution of this feature. Nearly the whole of the mastoid (MAS) is fused to the squamosal (SQ), the unfused tympano-periotic pars mastoidea being reduced to a small, pointed process frequently separated from the fixed portion by an appreciable distance.

The ramifications of the peribullary sinus are so extensive that bones adjacent to it are deeply excavated. The periotic (PE) is separated from the cranial cavity by a considerable depth of pneumatic sinus.

The basioccipital is generally deeply excavated on its lateral face and thinly laminar in form, but variations are found between the rather coarse pneumatized crests of *Pseudorca* and the extremely thin and sometimes fenestrated crests of *Delphinus*.

The blood vascular system of the peribullary sinus is intimately mingled with those of the petrosal and cavernous sinuses of the cranium. A wide hiatus remains in the cranium above the periotic until advanced age when secondary bone partially blocks up the hole.

THE INVASION OF THE PTERYGOID BONE BY THE MIDDLE EAR CAVITY

With few exceptions in terrestrial mammals, the pterygoid bone (PT) (Text-fig. 14*a*) in the strict sense consists of a vertical plate of small or moderate size in relation to the alisphenoid (ALS) with which it is sometimes fused and from which it

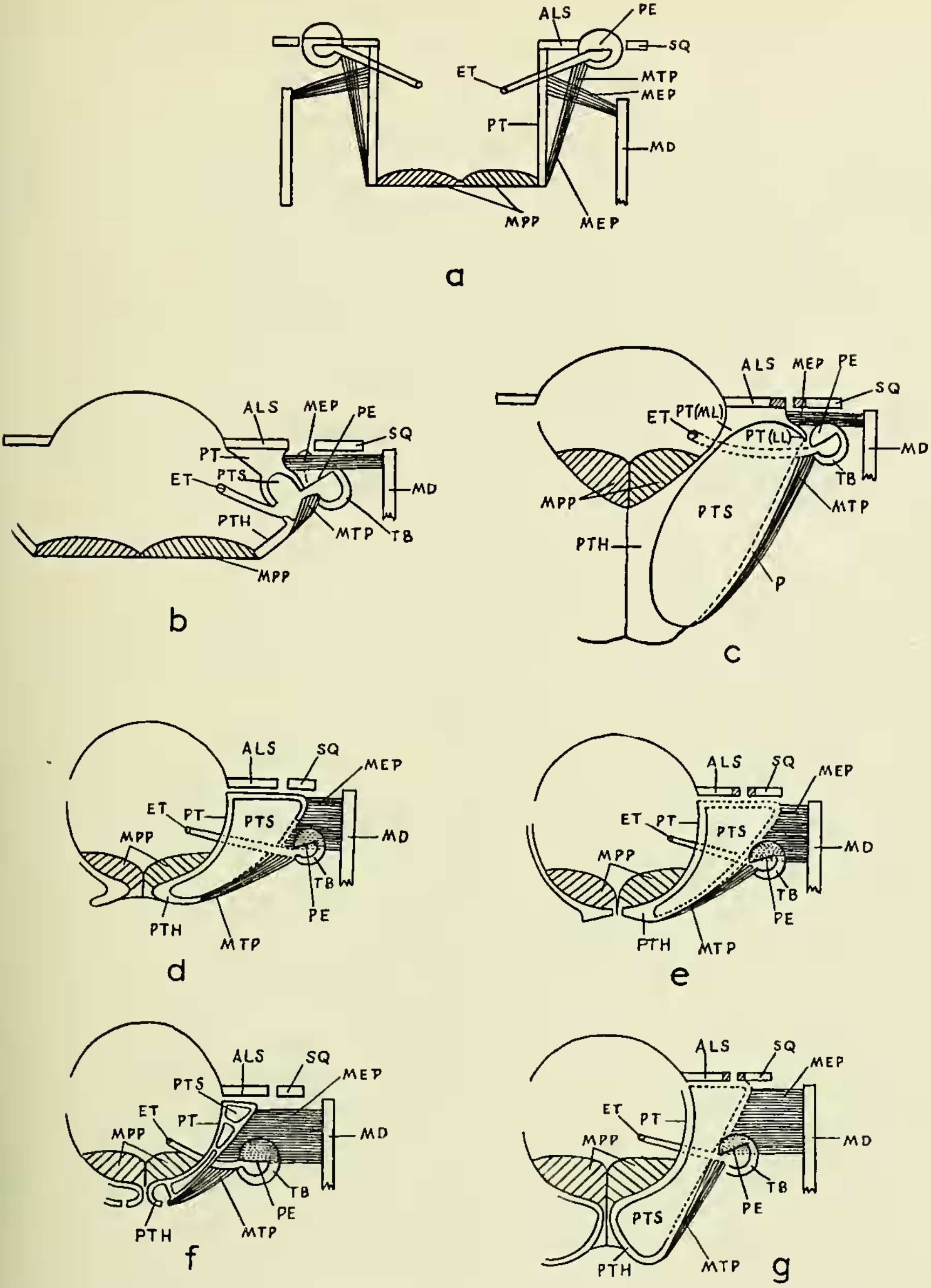

FIG. 14. Diagrams of the pterygoid region to show invasion of the pterygoid plate by the pterygoid sinus.

a. Terrestrial mammal. *b.* Mysticeti. *c.* Ziphioidea. *d.* Monodontidae. *e.* Physteridae. f. *Platanista.* *g.* Delphinidae.

projects ventrally. The pterygoid muscles (MEP) originate on the lateral face of the pterygoid bone and are inserted on the lower jaw, to which they pass in a slightly oblique ventral direction. The tensor palati (MTP) muscle originates on the lateral aspect of the cartilage of the Eustachian tube, passes ventrally over the pterygoid hamulus whence it spreads out into a delicate aponeurosis which merges with that of its fellow on the other side. The pharyngeal muscle mass (MPP), including the levator palati, is inserted into the superior surface of the aponeurosis and together with the latter forms the soft palate. The tympano-periotic bones (PE) fused with, and forming part of the cranium, lie dorsal to the pterygoid muscles.

The pterygoid bones (PT) of the Mysticeti (Text-fig. 14*b*) are not laminar but exceedingly thickened laterally to such an extent that the alisphenoid (ALS) is obliterated from view in the ventral aspect. The tympano-periotic (TB, PE) has become displaced ventrally, is not fused with the adjacent cranial bones and has almost completely lost participation in the formation of the cranial wall. In its position it has come to lie ventral to the level of the pterygoid muscles (MEP). An extension of the middle ear cavity invades the pterygoid bone, excavating a rounded fossa (PTS) in the latter, the cavity of which communicates with the Eustachian tube (ET).

Correlated with the ventral displacement of the bulla the tensor palati muscle (MTP) is considerably shortened dorso-ventrally.

The soft palate, although reduced antero-posteriorly as compared with that of most terrestrial mammals, is relatively much wider than in the latter. The antero-posterior reduction is due to the posterior extension of the palatine bones, a process which reaches its maximum in the genus *Balaena*.

The Ziphiidae (Text-fig. 14*c*) are characterized by the great enlargement of the hamular processes of the pterygoids (PTH). The superior portion of the pterygoid bone is again greatly thickened laterally so as to cover over the ventral aspect of the alisphenoid (ALS). The extensive excavations of the pterygoid hamulus by the diverticulum from the Eustachian tube (ET) has not resulted in a symmetrical splitting of the pterygoid plate (PT). Thus whereas the medial lamina (PT (ML)) persists as a thick, bony wall, the lateral wall (PT (LL)), so far as its osseous content is concerned, is reduced to a low, ventrally directed ridge at the dorso-lateral margin of the excavation. The soft, lateral closing membrane of the excavation is the persisting periosteum (P) of the lateral lamina, the greater portion of this lateral wall of the hamulus having entirely lost its ossification. The great distension of the hamular process has resulted in displacement and modification of the muscles in its neighbourhood. Thus the external pterygoid muscle (MEP) is greatly flattened dorso-ventrally and originates above the ventrally directed ridge already referred to. The tensor palati muscle (MTP), ensheathing the lateral closing membrane of the air sac, is expanded correspondingly. The pterygoid hamuli are in close apposition in the median plane so that there is no soft palate. The palatine aponeurosis is divided by the thickness of the combined hamuli, consequently in the posterior part of the nasal channel the pharyngeal muscles (MPP) lie within the posterior nares.

The tympano-periotic bones (TB, PE), as in the Mysticeti, are displaced ventrally so that they lie below the level of the pterygoid muscle, and the modification in the form of the periotic is such that it takes no part in the composition of the cranial wall.

The mode of excavation of the pterygoid in the Delphinapteridae (Text-fig. 14*d*) shows a remarkable similarity to that of the Physeteridae (*vide infra*) in that the pterygoid hamuli (PTH) remain for the most part unexcavated and of small size. The osseous portions of the superior and lateral laminae persist to a greater extent than in the Physeteridae, since there is an osseous portion of the superior lamina below the orbito-sphenoid uniting the medial lamina with the diminished lateral lamina. As in the Physeteridae the position of the pterygoid hamulus in relation to the proximal end of the Eustachian tube is such that the main direction of the tensor palati muscle (MTP) is more horizontal than vertical.

The interpretation of the condition of the pterygoid in the Physeteridae (Text-fig. 14*e*) is based on the evidence obtainable from the skulls of *Physeter* and *Kogia* together with the information contained in Yamada's paper (1953), no soft parts being available for examination. It would seem that the excavation of the pterygoid bones is the reverse of that found in the Ziphiidae. In the latter the pterygoid hamulus is greatly enlarged and extensively excavated, while the pterygoid plate is relatively unaffected, whereas in the Physeteridae the hamulus is small, inconspicuous, and unexcavated, while the pterygoid plate is extensive in area and excavated to such a degree that the osseous content of the superior and lateral laminae of the pterygoid bone is completely absent.

From the condition of excavation of the pterygoid it can be deduced that the pterygoid muscles (MTP) must be inserted onto the periosteal closing membrane of the air sac but verification of this must await inspection of the soft parts.

The tensor palati muscle (MTP) ensheathing the air sac must be very nearly horizontal in its main direction, such is the relation of the pterygoid hamulus to the proximal end of the Eustachian tube. The pterygoid hamuli (PTH) are not quite in apposition in the middle line, but as in the Ziphiidae the palato-pharyngeal muscles (MPP) are enclosed within the posterior nares.

Platanista (Text-fig. 14*f*), so far as the pterygoid bone is concerned, is the least specialized of the Platanistidae. Indeed its condition is such that it provides (along with *Stenodelphis*) the explanation to all the successive changes found in the Cetacea, and this notwithstanding the great development of the presumably pneumatized maxillary crests. In *Platanista*, although both pterygoid plate (PT) and hamulus (PTH) are excavated, there is little inflation between the laminae, which are connected by numerous, bony trabeculae. Both the ventral and lateral laminae retain their osseous content and only the hamulus shows any degree of fenestration.

The pterygoid hamuli are closely approximated to each other in the middle line, in this feature resembling what is found in most of the Delphinidae.

No direct inspection of the pterygoid (MEP) and palatal muscles (MPP) was possible, but it can be inferred from the close approximation of the pterygoid hamuli that the palato-pharyngeal muscles are enclosed within the posterior nares. Similarly the tensor palati muscles (MTP) would appear to be more horizontally directed, as in the Physeteridae and Delphinapteridae. With regard to the pterygoid muscles it may be noted that their normal place of origin—the lateral aspect of the pterygoid plate—retains its osseous condition. This implies that the primary function of the muscles is as in the normal terrestrial mammal, that of actuating the lower jaw. It also implies that the articulation of the lower jaw must be similar to that of the terrestrial mammal. It is interesting to note that Anderson (1879, p. 433) observed in a specimen of 6½ ft long that "the jaws are capable of great extension, opening at their tip . . . to 13 inches". The size of the zygomatic process of the squamosal similarly indicates that the masseter muscle is not reduced in size as in the delphinids. The presence of a mandibular articular capsule is conjectural but seems very likely.

In the Phocaenidae and Delphinidae (Text-fig. 14*g*) both the plate (PT) and the hamulus (PTH) of each pterygoid bone are excavated, and inflated to a greater or lesser extent. The lateral and superior laminae of the pterygoid show a diminution of their osseous content, which however, is variable from genus to genus. According to the degree of distension of the pterygoid plate the ventral aspect of the alisphenoid (ALS) is exposed to a greater or lesser extent. The approximation of the hamuli to each other in the middle line is also similarly variable, the degree of approximation depending to a large extent on the state of inflation of the hamuli. The final expression of this process can be seen in *Delphinus delphis* in which the greater part of the pterygoid musculature (MEP, MTP) is attached to the persisting, non-osseous, periosteum of the lateral lamina. Due to the expansion of the pterygoid hamuli in a ventral direction, the tensor palati muscles (MTP) retain more of their vertical orientation, although they are greatly extended antero-posteriorly. The naso-pharyngeal muscle mass (MPP) lies within the posterior nares and is separated from the ventral aspect of the aponeurosis by the pterygoid air spaces.

SYSTEMATIC ARRANGEMENT

The descriptions and figures given in the foregoing section are intended to convey an impression of the average differences in the middle ear air sac system between the families of the Cetacea. There is however also intergeneric variation, which is considered to be significant and which in some families shows a serial gradation of specialization.

Text-figs. 15–21 show a schematic representation of the splitting of the pterygoid bone in the Cetacea. The diagrams in the left hand column are of the lateral aspect of the pterygoid region. The right hand column shows an antero-posterior view of the same region. In the diagrams the thick black line represents pterygoid bone, the dotted line (except in Text-fig 15*b*′) indicates those parts of the pterygoid bone from which the osseous content is absent, leaving periosteal tissue. The peribullary sinus which is derived from the tympanic cavity is shown in the diagrams but not discussed.

Text-figs. 22–25 show the dorso-ventral views of the sinus system dissociated from the skull.

Text-fig. 15*a* shows schematically the inter-relationship of the alisphenoid (ALS), palatine (PAL), maxilla (MAX), orbito-sphenoid (OS), the pterygoid plate (PT), the tympanic bulla (TB), optic (NO) and adjacent foramina, the foramen ovale (NM) and the mandibular branch of the 5th nerve, in some terrestrial mammals. Text-fig. 15*a′* is an antero-posterior view showing the inter-relationship of the pterygoid plate, basioccipital (BO), alisphenoid 5th nerve branch, foramen ovale and squamosal.

MYSTICETI

Text-fig. 15*b*, *c* shows diagramatically these relationships in *Caperea*. The tympanic cavity and Eustachian tube form a wide diverticulum which invades the pterygoid plate, and the tympano-periotic is withdrawn from direct contact with the cranial cavity. The pterygoid has become greatly thickened laterally, enveloping the mandibular branch of the 5th nerve in a deep fissure, the lips of which are in contact in a pterygoid to pterygoid suture. The nerve has been partially deflected simultaneously in a slightly anterior direction, by the forward extension of the diverticulum i.e. the pterygoid sinus. It should be noted that at this stage there is no lateral deflection of the 5th nerve branch (Text-fig. 15*b′*).

In *Balaena* (Text-fig. 15*c*) the pterygoid sinus (PTS) extends anteriorly beyond the level of the foramen ovale (NM), and the pterygoid plate (PT) is expanded laterally to a greater extent than in *Caperea*. These factors have produced a lateral as well as forward deflection of the 5th nerve branch (Text-fig. 15*c′*). That part of the pterygoid which would have covered the 5th nerve branch posteriorly has disappeared owing to the extension of the sinus dorsally. The 5th nerve branch is partially enclosed within a channel formed dorsally by the alisphenoid (ALS) and ventrally by the superior lamina of the pterygoid plate. A ventrally-directed extension of the squamosal, the falciform process (FP), lateral to the lateral pterygoid plate deflects the 5th nerve branch to its original ventral direction.

In *Caperea* the pterygoid hamulus (PTH) remains rather small but in *Balaena* it forms a wide, mesially-directed shelf.

In *Eschrichtius* (Text-fig. 15*d*) the pterygoid sinus is similar to that of *Balaena* in its posterior part whilst anteriorly it projects forward to an extent comparable with *Balaenoptera*. The falciform process (FP) is not as prominent as in *Balaena*. The mesial lamina of the pterygoid is distended mesially as well as laterally (Text-fig. 13*d′*).

Text-fig. 15*e* shows the condition in the Balaenopteridae (see also Pl. 7). The diverticulum of the Eustachian tube is more elongated and, with reference to the position of the foramen ovale, has extended anteriorly as compared with its limits in the Balaenidae. The superior lamina of the pterygoid plate (PT) completely covers the ventral aspect of the alisphenoid (ALS). Again the 5th nerve branch (NM) is deflected in a lateral direction (Text-fig. 15*e′*) and is completely enclosed within a bony tube formed ventrally by the superior lamina of he pterygoid and dorsally by the alisphenoid. The nerve is directed ventrally by an even greater development of the falciform process (FP). The falciform process bifurcates antero-posteriorly round the 5th nerve branch, thus the latter has its exit from the side of the skull formed by a second bony tube. Text-fig. 15*e′* also shows the mesial dilation of the pterygoid plate which is absent in *Balaena*. The pterygoid hamulus

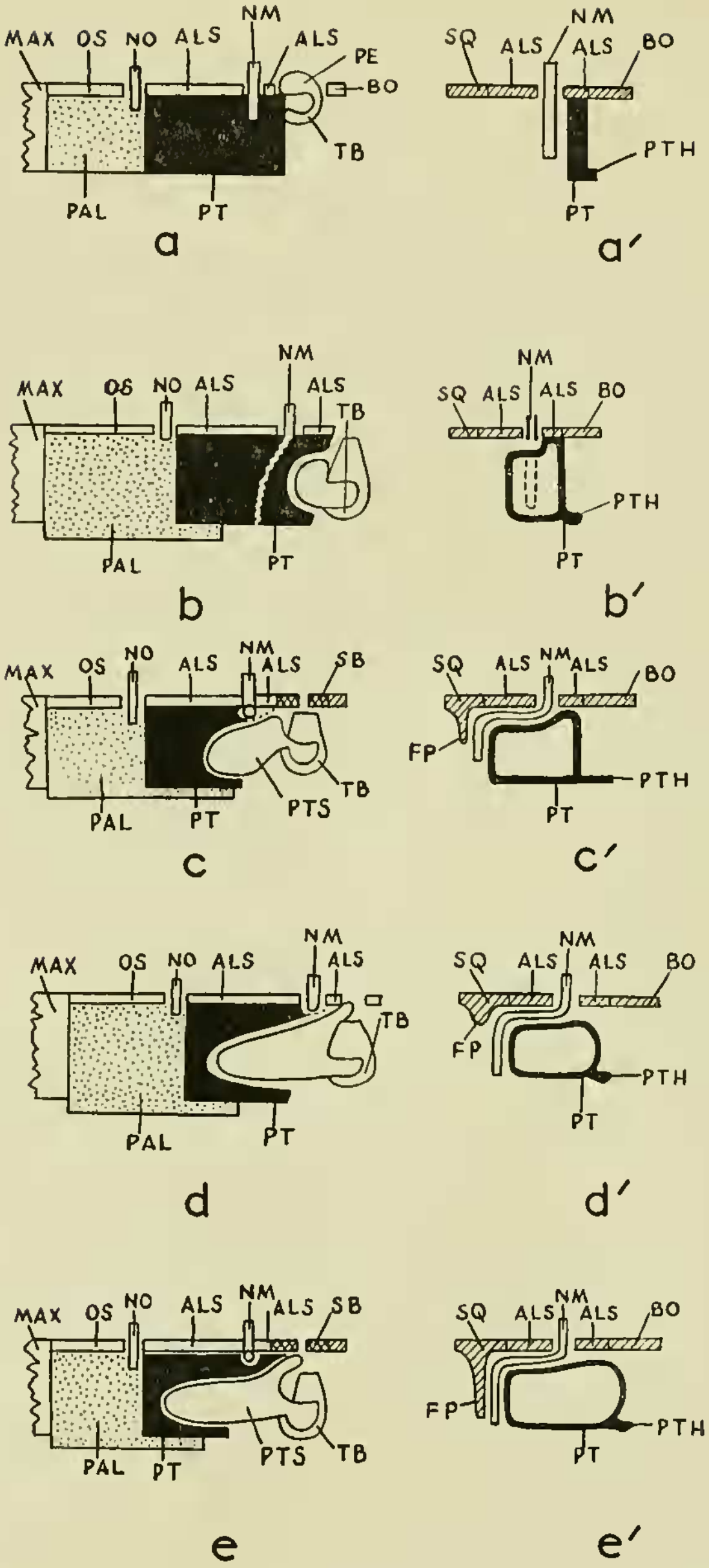

FIG. 15. Schematic diagrams showing the progressive invasion of the pterygoid bone by the pterygoid sinus in *a* (longitudinal section), *a′* (antero-posterior transverse section), terrestrial mammal ; b, b′, *Caperea* ; c, c′ *Balaena* ; d, d′ *Eschrichtius* ; e, e′ *Balaenoptera*.

(PTH) is relatively small and, as in *Balaena*, unexcavated. Text-fig. 22 *a–d* shows the gradual development of the air sacs in the genera referred to above.

ODONTOCETI

ZIPHIOIDEA

Text-fig. 16*a* shows diagramatically the condition existing in the Ziphioidea. The distension of the pterygoid bone shows a distinct advance on the condition found in the Mysticeti. Thus the pterygoid hamulus is so extended anteriorly that it passes beyond the anterior limit of the alisphenoid (ALS), passes below the orbitosphenoid (OS) and the optic foramen (NO), compresses the palatine (PAL) anteroposteriorly and at its anterior limit makes contact with the maxillary (MAX), dividing the palatine into dorsal and ventral components. The superior lamina is fenestrated, exposing a small area of palatine. The pterygoid hamulus also extends posteriorly under the foramen ovale (NM). Its freely projecting, postero-ventral portion extends ventrally to the level of the basioccipital (BO).

Above the inflated pterygoid hamulus, in the region of the optic foramen, the undivided pterygoid plate persists, and to it the pterygoid muscles are attached (see p. 82).

The 5th nerve branch (NM) (Text-fig. 16*a*′) is directed laterally by the thin superior lamina of the pterygoid hamulus. Its more distal portions are not enclosed within a bony tube as in the Mysticeti since the whole of the osseous content of the lateral lamina is lacking and the falciform process is reduced to a slender spine. The condition of the pterygoid just described is common to all the ziphioids with negligible variation.

The air sac development is shown in Text-fig. 22*e* (see also Pls. 8–12).

MONODONTOIDEA

In *Monodon* the pterygoid hamuli remain unexcavated, inflation being confined to the pterygoid plate (Text-fig. 16*b* (and Pls. 13 and 14)). The pterygoid does not extend so far forward as to bifurcate the palatine but there is some resorption at the anterior limit of the bone so that, in the prepared skull, the palatine is exposed.

A new feature is a small, anteriorly projecting diverticulum which cavitates the alisphenoid bone behind and above the foramen ovale. As a result the portion of the alisphenoid posterior to the foramen ovale is raised in level above the remainder of the alar process and the tympano-periotic consequently is further removed from the cranial cavity.

The 5th nerve branch (Text-fig. 16*b*′), after emergence from the cranium, is not (for the most part) enclosed within a bony infundibulum because of the loss of the alisphenoidal part of the superior lamina of the pterygoid plate and because of the great reduction in size of the falciform process. There is, however, the beginning of a new infundibulum formed from the alisphenoid.

More anteriorly (Text-fig. 16*b*″) considerable parts of the ossified superior and lateral laminae remain.

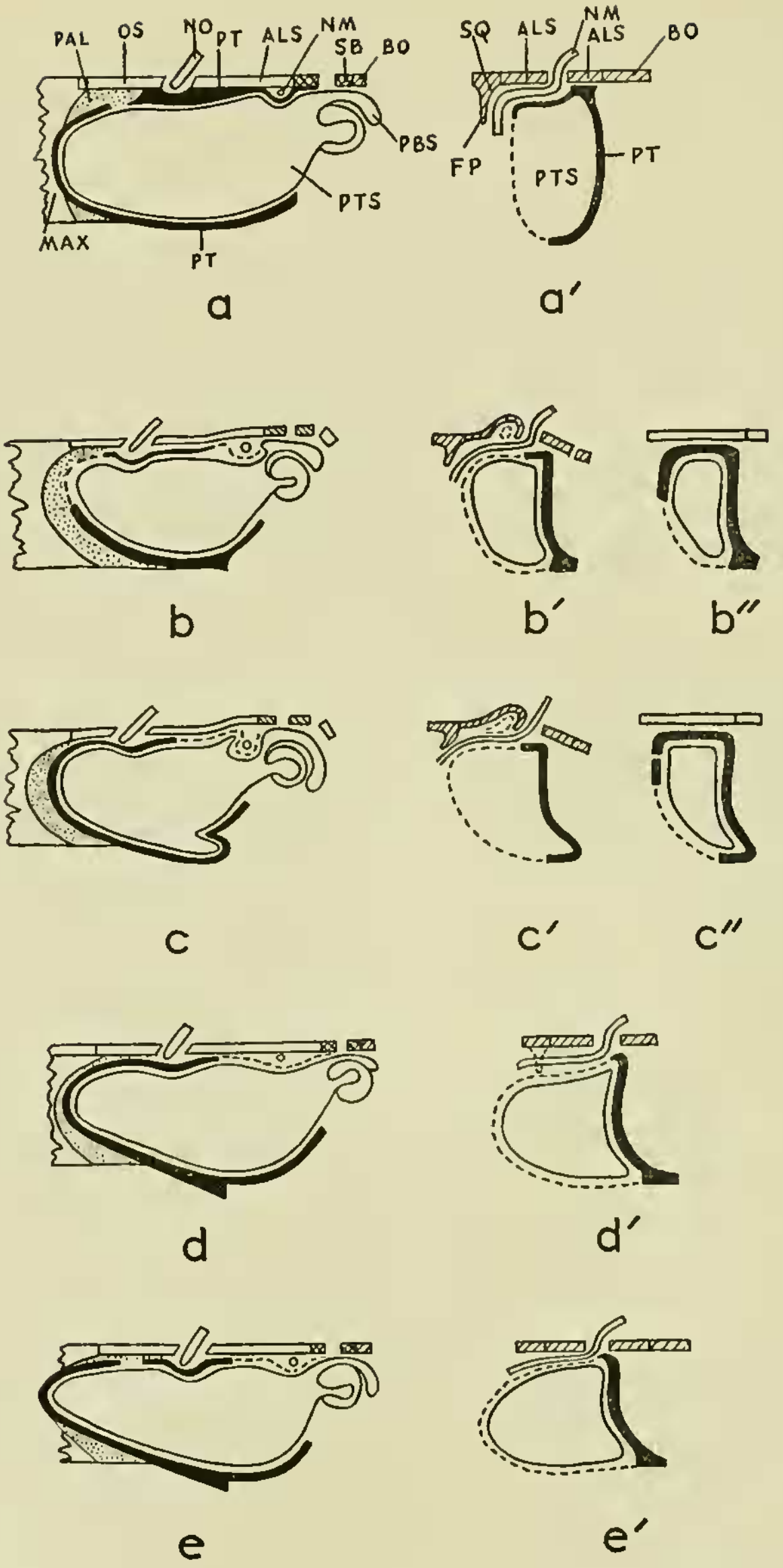

FIG. 16. Schematic diagrams showing invasion distention and resorption of the pterygoid bone by the pterygoid sinus in *a* (longitudinal section), *a′* (transverse section). Ziphioidea ; *b*, *b′* and *b″* (further rostral than *b′*) *Monodon* ; c, c′ c″ *Delphinapterus* ; d, d′ *Kogia* ; e, e′ *Physeter*.

The other existing representative of the Monodontoidea, *Delphinapterus* (Text-fig. 16*c* and Pl. 15) differs from *Monodon* mainly in having the pterygoid hamuli slightly inflated, in this approximating to the condition generally encountered in the Delphinidae. As in *Monodon* the alisphenoid is excavated behind the foramen ovale and in this region is raised in level above that of the rest of the bone. A posterior extension of the pterygoid periosteum is in contact with this excavation above the foramen ovale.

The 5th nerve branch (Text-fig. 16*c*′) shows approximately the same condition as in *Monodon*. More anteriorly (Text-fig. 16*c*″) there is greater resorption of the lateral lamina than in *Monodon*. The hamulus, as shown in this and the previous figure, is excavated.

The diagram of the dissociated air sacs are shown in Text-fig. 22*f* and *g*.

PHYSETEROIDEA

In contrast with the Ziphioidea, in the Physeteroidea (Text-figs. 16*d* and *e* and Pl. 16) the splitting of the pterygoid is restricted to the pterygoid plate and does not involve the hamulus. The degree of anterior extension of the pterygoid plate in *Physeter* (Text-fig. 16*d*) is similar to that effected by the hamular element in the Ziphiidae except that the palatine bone, although compressed, is not divided anteriorly. The occipital crest (not shown in the figure) is reduced in size by a backward projection of the mesial lamina of pterygoid plate, and it is reasonable to assume that the superior lamina has been similarly extended and that the wide exposure of the alisphenoid in the cleaned skull is due to the loss of the osseous content of the superior lamina.

The 5th nerve branch (Text-fig. 16*d*′) is not enclosed within any bony tube lateral to its emergence from the alisphenoid since the osseous content of the superior lamina of the pterygoid is lacking. Similarly the distal portions of the nerve are not surrounded by bone because the lateral lamina is no longer ossified. The falciform process is reduced to a diminutive plate. The lateral aspect of the mesial plate is convex which is in contrast to the concavity found in this region in the ziphioids.

Kogia (Text-fig. 16*e*) is essentially similar to *Physeter* in the condition of splitting of the pterygoid, except that in its forward extension the latter divides the palatine into a dorsal and a ventral component. This condition is comparable with that found in the Ziphiidae except that in the latter it is the hamular portion of the bone, which is involved. The 5th nerve branch (Text-fig. 16*e*′) is not enclosed in any bony channel after emergence from the alisphenoid and there is no remaining vestige of the falciform process.

The diagrams of the dissociated air sacs are shown in Text-fig. 22*h* and *i*.

PLATANISTOIDEA

The members of the family Platanistidae (Text-fig. 17 and Pls. 18–23) show relatively primitive features so far as the ventral region of the pterygoid bone is concerned but they approximate more closely to the conditions found in the delphinids than to the Physeteridae, Ziphiidae or any of the Mysticeti. The chief characteristic

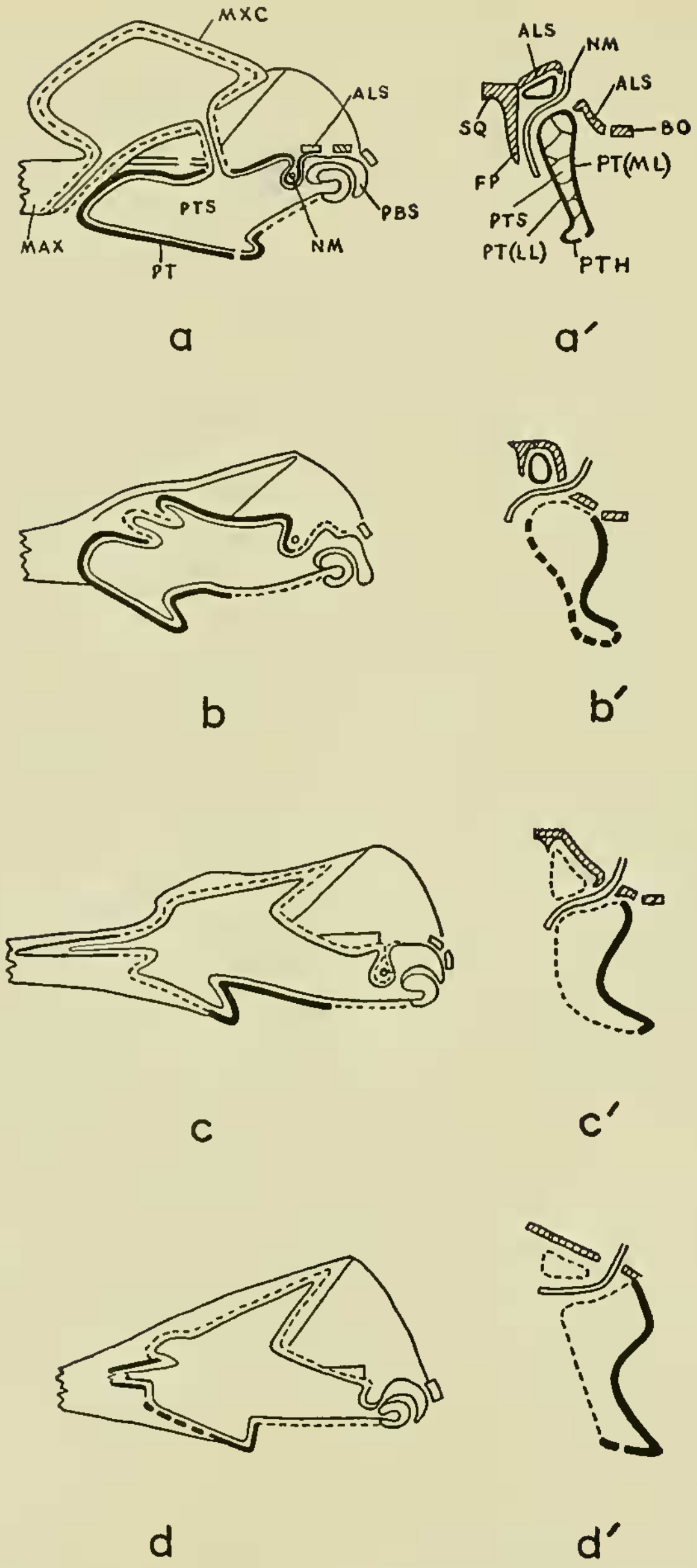

FIG. 17. Schematic diagrams showing invasion, distention and resorption of the pterygoid bone by the pterygoid sinus in *a* (longitudinal section), *a′* (transverse section), *Platanista*; b, b′, *Stenodelphis*; c, c′, *Inia*; d, d′ *Lipotes*.

of *Platanista* (Text-fig. 17*a*) is that each pterygoid (PT) completely overrides the palatine and extends onto the posterior end of the maxilla (MAX). The pterygoid hamuli, although small, are completely excavated and to some extent fenestrated. The mesial (PT (ML)) and lateral (PT (LL)) laminae of the pterygoid plate are connected by bony trabeculae (Text-fig. 17*a'*). In addition to the forwardly projecting cavitation of the alisphenoid behind the foramen ovale, there is a posteriorly projecting diverticulum of the pterygoid bone which comes into contact with the alisphenoidal cavitation above the foramen ovale. The two diverticula do not merge where they come together, two very thin bony laminae having been observed which separate them. The infundibulum of the optic nerve is very greatly reduced.

The internal architecture of the characteristic maxillary crests (MXC) of *Platanista* so resembles that of the interlaminar region of the pterygoid that it is reasonable to suppose that the cavitation of the pterygoid is continuous with that of the maxillary crests. Bony channels connect the two regions and, in the series of cetacean skulls examined and described in this paper, there is plenty of evidence of the extensibility of the pterygoid beyond its obvious limits (see for example Text-fig. 19*a* of *Pseudorca* where portions of the pterygoid have penetrated the orbital and preorbital regions). *Platanista* can be regarded as an extreme example of this process. Indeed it would not be unreasonable to regard the development of the maxillary crests as a consequence of a corresponding extension of the pterygoids. A diverticullum of this extension passes obliquely forward on either side of the base of the rostrum splitting the bone in this region into dorsal and ventral laminae which are connected mesially, and probably laterally also in the living animal, by bone. In *Inia*, as will be described below, a slender extension of the pterygoid sac projects into the rostrum, whether this is so in *Platanista* has yet to be ascertained.

There is no indication in *Stenodelphis* (Text-fig. 17*b*) of the assumed extension in *Platanista* of the pterygoid sinus system onto the dorsal aspect of the skull. Apart from this, the ramifications of the pterygoid bone on the ventral aspect of the skull show an advance on *Platanista*. Each extends forward beyond the limit of the orbitosphenoid onto the lateral aspect of the frontal. It also invades the orbit in the region normally occupied by the prominent orbital nerves and muscles. This condition should be compared with that found in *Pseudorca* in which the eye and its muscles are fully functional. The pterygoid hamuli are more pronouncedly excavated and inflated than in *Platanista*. The posterior diverticulum of the pterygoid sinus which passes dorsal to the foramen ovale is more dorsally situated in relation to the latter than in *Platanista*.

The 5th nerve branch (Text-fig. 17*b'*) issuing from the cranial cavity appears to be bounded dorsally by the very thin, bony lamina which encloses the small pterygoid diverticulum passing posteriorly above the foramen ovale. The corresponding ventral boundary of the nerve is not ossified. The lateral lamina of the pterygoid retains most of its osseous content although it is extensively fenestrated. The dorsally-directed spread of the pterygoid is accompanied by a corresponding dorsal deflection of the wing of the alisphenoid.

The distribution of the pterygoid sinus system in *Inia* has been obtained largely from radiographic evidence, the bony element of the region being so greatly lacking (see p. 45). In this species (Text-fig. 17*c*) the whole of the ventro-lateral aspect of the frontal is ensheathed by an extension of the sinus system which was presumably enclosed within a corresponding extension of the pterygoid bone, the osseous element of which has disappeared. In addition to the excavation and extension of the pterygoid hamulus, there is a slender, elongated extension of the sinus into the maxillary bone of the rostrum. The exact disposition of the diverticula round the foramen ovale cannot be ascertained but presumably they are in very close contact with each other, the 5th nerve on emergence from the cranium being completely surrounded by a non-ossified boundary. Text-fig. 17*c′* shows the remaining, ossified, mesial lamina of the pterygoid. The extensive loss of osseous content in the lateral and dorsal laminae is noteworthy. The diverticulum of the pterygoid sinus above the foramen ovale is much larger than in *Stenodelphis* and is without osseous content in its walls.

The distribution of the air sinus system in *Lipotes* is very similar to that of *Inia*. Noteworthy differences are that more of the osseous content of the pterygoid hamulus persists and that the post-orbital extension is wider and larger. In the absence of soft parts it is presumed that the anterior extremity of the sinus system invades the rostrum (Text-fig. 17*d*, *d′*).

The diagrams of the dissociated air sacs in the Platanistoidea are shown in Text-fig. 23*a*–*d*. The conjectured maxillary air sac of *Platanista* is not shown in Text-figure 23*a*.

DELPHINOIDEA

Consideration of the splitting of the pterygoid in the Delphinoidea begins with an examination of the conditions found in the Phocaenidae, because the average condition in this family is less specialized than in the Delphinidae, particularly with respect to the portions of the pterygoid on the ventral aspect of the skull. In *Phocaena* (Text-fig. 18*c*), as in *Inia*, there is an extension of the pterygoid sinus under the post-orbital process of the frontal (see also Pl. 27), and another pre-orbital extension, which in *Inia* is confluent with the post-orbital because of the reduction in size, in the latter, of the optic nerve and muscles. In *Phocaena* the optic nerve and muscles are fully functional and lie between the two diverticula. An extension of the pre-orbital diverticulum passes dorso-caudally between the frontal and maxilla; the fossa formed by this diverticulum being a characteristic feature in the phocaenid skull.

Another diverticulum in front of the foramen ovale projects posteriorly and mesially, producing a cavitation of the alisphenoid in which no osseous trace of the pterygoid remains. A ventral curving of the posterior margin of the alisphenoid posteriorly to the diverticulum just referred to, separates the latter from the peribullary sinus. A bony bridge between the hinder margin of the alisphenoid and the hinder margin of the palatine represents the remaining portion of the lateral lamina of the pterygoid (Text-fig. 18*c′*).

The 5th nerve branch, on emergence from the cranial cavity, is surrounded not by bone, but by the periosteal closing walls of the sinus, except in the vicinity of the falciform process where the dorsal aspect of the nerve is in contiguity with the

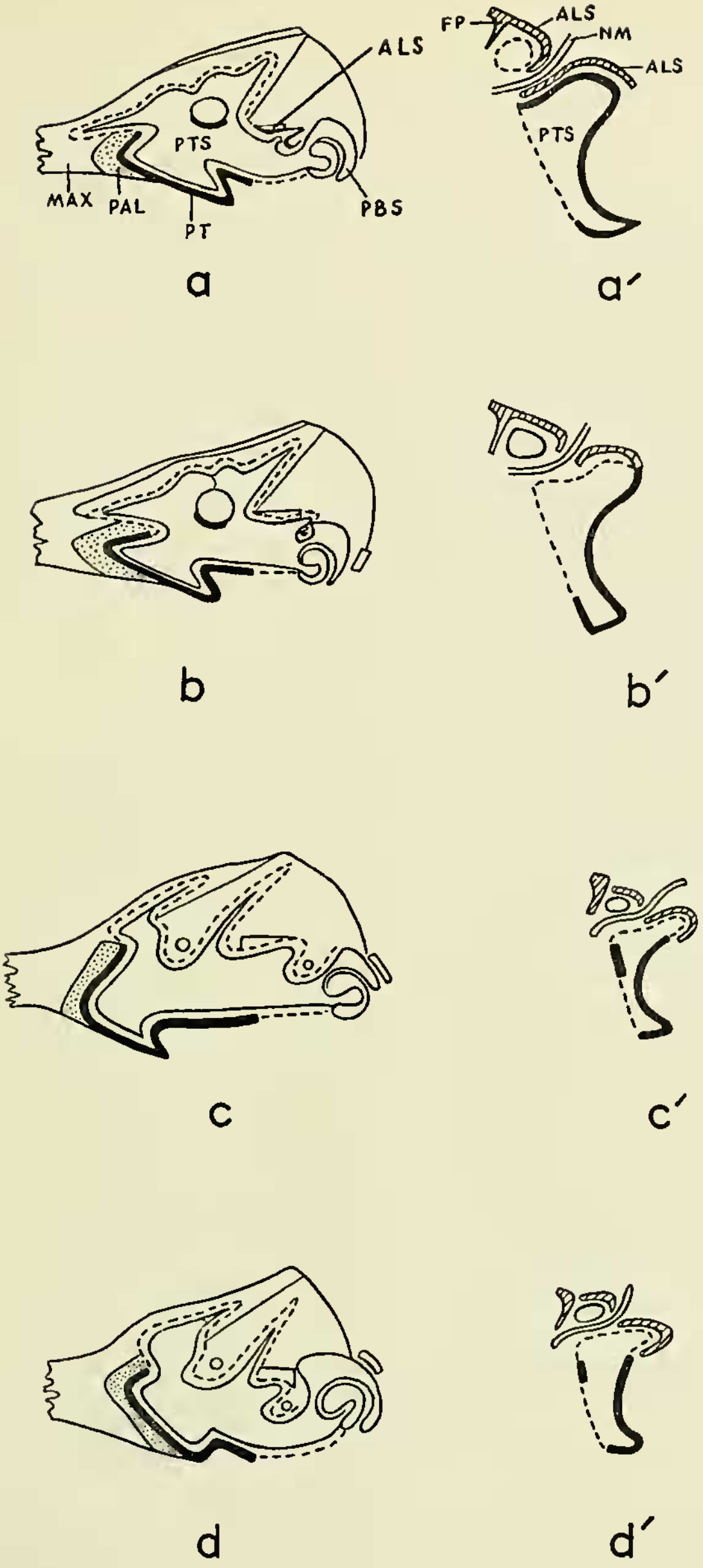

FIG. 18. Schematic diagrams showing invasion, distention and resorption of the pterygoid bone by the pterygoid sinus in *a* (longitudinal section), *a′* (transverse section), *Steno*; b, b′ *Sousa*; c, c′ *Phocaena*; d, d′ *Neomeris*.

ventrally-directed, posterior margin of the alisphenoid. The figure (18*c*′) shows the mesial cavitation of the alisphenoid, not the more lateral, ventrally directed portion.

The pterygoid hamuli are excavated by the sinus but are not greatly inflated. Anteriorly they do not override the palatines which form an appreciable part of the palatal area of the skull.

In general, the condition of the pterygoid and its associated sac in *Neomeris*(Text-fig. 18*d* and Pl. 28) are similar to that of *Phocaena*. The pre-orbital diverticulum is more prominent, its extension between frontal and maxillary more slender. The posteriorly projecting diverticulum anterior to the foramen ovale is shorter antero-posteriorly and occupies a deeper concavity of the wing of the sphenoid. The anterior lobe of the peribullary sinus extends further anteriorly above the foramen ovale. The palatines are as in *Phocaena*. The pterygoid hamuli are only partially excavated and are uninflated. The small bony bridge (Text-fig. 18*d*′) of the lateral lamina of the pterygoid plate remains.

The 5th nerve branch on emergence from the cranial cavity is surrounded dorsally and posteriorly by the peribullary sinus, ventrally and anteriorly by the pterygoid diverticulum in the region of the alisphenoid.

The diagrams of the dissociated air sacs of the Phocaenidae are shown in Text-fig. 23*g* and *h*.

The sub-family Orcinae, and particularly *Pseudorca*, provides most useful evidence about the origin of ramifications of the sinus system. Like *Stenodelphis* (see above p. 91), *Pseudorca* specimens demonstrate how the non-osseous closing membranes of the pterygoid system are secondary to a phase during which the osseous content of the ramifying pterygoid bone is still present (see Pls. 29 and 30). Thus there are individuals in which the pre- and post-orbital diverticula are completely enclosed in a bony armour. In other specimens again, the bony armour is heavily fenestrated and frequently represented by a bony cagework. (This last is the condition in the specimen figured in Pl. 30). At the other end of the scale there are specimens in which the osseous content of the pre-orbital extensions and the lateral lamina of the pterygoid is wanting. Text-fig. 19*a* gives a generalized picture of the *Pseudorca* condition and shows the relatively small pre-orbital and post-orbital diverticula.

The posteriorly projecting diverticulum of the pterygoid air sac passes round the dorsal margin of the foramen ovale (NM) and the implication of the peribullary sinus (PBS) in the investment of the 5th nerve branch is very small. The bony, dorsal lamina of the pterygoid is fenestrated to a greater or less extent in different individuals.

The pterygoid hamulus is excavated and much inflated but only slightly overrides the palatine (PAL).

The hamulus projects mesially to a greater extent than in previously described genera (Text-fig. 19*a*′) so that the mesial border of the one hamulus closely approximates to that of the other.

The 5th nerve branch on emergence from the skull is frequently enclosed in a cagework of small, bony trabeculae which represent the last remnants of a bony infundibulum.

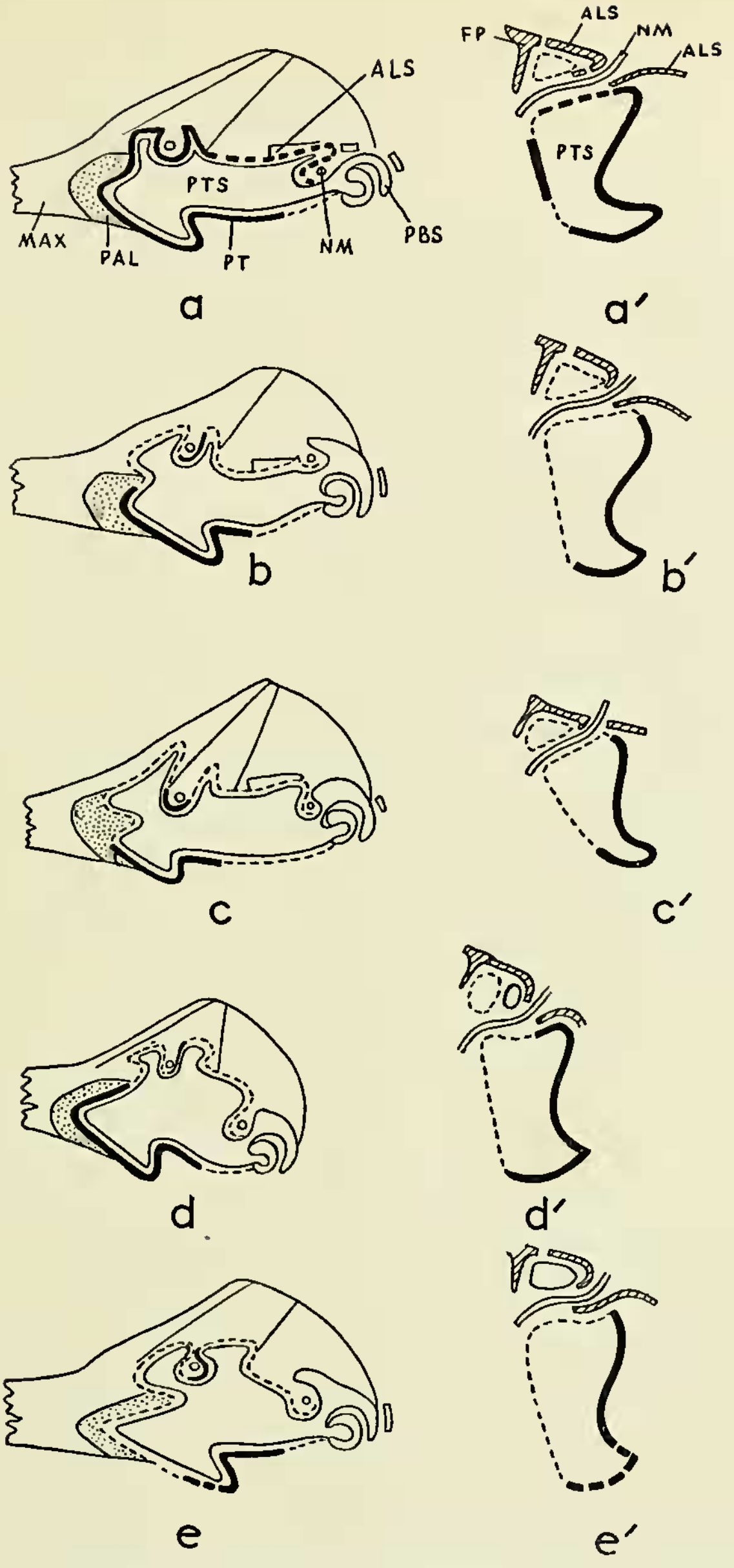

FIG. 19. Schematic diagrams showing invasion, distention and resorption of the pterygoid bone by the pterygoid sinus in *a* (longitudinal section), *a′* (transverse section), *Pseudorca* ; b, b′ *Orcinus* ; c, c′ *Orcaella* ; d, d′ *Globicephala* ; d, d′ *Feresa*.

The osseous content of the lateral lamina of the pterygoid appears to be wanting, but external to the pterygoid periosteal closing membrane, is a bony bridge consisting of a plate formed by a posteriorly directed extension of the palatine and an anteriorly extending process from the base of the falciform process (see pp. 35–37 *supra*).

The condition of the sinus system in *Orcinus* (Text-fig. 19*b* and Pl. 31) is in general similar to that of *Pseudorca* but with certain modifications. Thus, the pre-orbital sac is enlarged in size relative to the post-orbital, both sacs are expanded in a lateral direction and the anterior sac extends onto the palatal surface of the maxilla (its anterior limit being difficult to define in the prepared skull). The fossa which gives access to the maxillary foramen is very much enlarged relative to that of other dolphins. It is confluent with the bony cavity which houses the pre-orbital sac, but the significance of their contiguity is not understood.

The peribullary sinus projects anteriorly as far as the anterior margin of the foramen ovale.

As in *Pseudorca* the palatine is not extensively over-ridden by the pterygoid.

The extensive disappearance of the osseous content of the superior and lateral laminae is indicated in Text-fig. 19*b*′. The hamuli are extensively excavated and inflated. They meet in the middle line.

The 5th nerve branch on emergence from the cranial wall is entirely surrounded by air sac derived from the peribullary and pterygoid sinuses.

In *Orcaella* (Text-fig. 19*c* and Pl. 32) the pre-orbital cavity is conspicuously wide and does not become constricted as it passes dorsally behind the maxilla. A diverticulum of the pre-orbital extension of the air sac projects forward and overlaps the ventral surface of the maxilla at the base of the rostrum. In the sphenoidal region there is no clearly delineated line of demarcation between the posterior limit of the pterygoid system and the peribullary sinus. Any division that exists between these systems must be membranous. The pterygoid hamulus overrides the palatine to such an extent that the latter is divided into two portions, dorsal and lateral respectively.

The pterygoid hamuli (Text-fig. 19*c*′) are widely separated, excavated and partially dilated. There is no trace of an osseous lateral lamina. The 5th nerve branch is entirely surrounded by air sac. The respective participation of the peribullary and pterygoid systems in the investment of the nerve cannot be assessed in the absence of soft parts. The falciform process is considerably reduced and attenuated in correspondence with the increased development of sinuses.

In the genus *Globicephala* (Text-fig. 19*d*, frontispiece, and Pls. 33 and 34) lateral expansion of the sphenoidal portions of the pterygoid sac has taken place. The orbital lobes appear to be relatively insignificant. The alisphenoid has been completely over-ridden by the pterygoid sac and in its lateral aspect presents only the edge of a thin lamina.

A posteriorly projecting process of the sphenoidal part of the pterygoid sac passes dorsal to the foramen ovale and superior to the anterior tip of the peribullary sinus. Anteriorly the pterygoids do not greatly override the palatines so that a fairly wide band of the latter is exposed on the palate. The palatine bones are themselves excavated by the forward extension of the hamular cavities.

The osseous content of the dorsal lamina persists (Text-fig. 19*d*) as a shelf, narrowing from below the orbito-sphenoid to disappearance below the alisphenoid. No trace remains of a bony, external lamina.

The pterygoid hamuli are completely excavated and widely dilated (Text-fig. 19*d*′). They are in contact in the middle line.

On emergence from the cranium, the 5th nerve branch is surrounded proximally by a bony infundibulum but more distally it is surrounded by extensions of the peribullary and pterygoid sinuses.

The genus *Feresa* may be considered conveniently with the *Orcinae* because of its apparent affinity with the latter, although in some respects it bears resemblance to *Grampus griseus* also.

The post-orbital and sphenoidal portions of the pterygoid sacs are greatly enlarged (Text-fig. 19*e* and Pl. 35). The pre-orbital and post-orbital sacs are apparently in contact above the optic nerve. Not only has the bony content of the dorsal lamina of the pterygoid disappeared, but the wide, ventrally exposed alisphenoid is so reduced in thickness that its lateral aspect, in the temporal fossa, is extremely narrow. The peribullary sinus passes forward above the foramen ovale. The pre-orbital sac overlaps onto the palatal aspect of the maxilla to form the anterior sac.

The palatine bones are widely exposed but very deeply excavated by the pterygoid sacs. This excavation is continued forward so that the posterior aspect of the maxilla is also involved and both palatine and maxilla are fenestrated on the palatal aspect.

The superior and lateral laminae of the pterygoid (Text-fig. 19*e*′) have lost their osseous content. In both of the British Museum specimens and in Yamada's (1953) figured specimen, the posterior portions of the pterygoid hamuli are missing. The heavily fenestrated portions that remain, together with the incompleteness of the hamuli, are an indication of the extent to which resorption has proceeded in this genus.

The 5th nerve branch, medially to the falciform process, is surrounded by air sac, but proximally an infundibuliform extension of the alisphenoid invests it.

The dissociated air sacs of members of the Orcinae are shown in Text-fig. 24 *a–e*.

The pre-orbital and post-orbital diverticula of the pterygoid system in *Cephalorhynchus heavisidei* (Text-fig. 20*a* and Pl. 36) approximate to each other superiorly to the optic foramen to a greater extent than was evident in any of the Orcini with the exception of *Feresa*. These lobes have a tendency to spread laterally rather than vertically, giving them greater width than height, the post-orbital lobe extending posteriorly as in *Phocaena* but not to the same degree. The peribullary sinus (PBS) extends anteriorly above the foramen ovale but a well defined bony ridge of the alisphenoid separates it from the posterior limit of the pterygoid system. Each palatine bone (PAL), anterior to the pterygoid (PT) is widely exposed and not overridden by the latter.

The pterygoid hamuli (Text-fig. 20*a*′) are widely excavated and inflated, they also approximate to each other in the middle line. The 5th nerve branch (NM) on emergence from the cranium is completely surrounded by air sinus; posteriorly and dorsally by the peribullary, anteriorly and ventrally by the pterygoid.

C. commersoni (Text-fig. 20*b* and *b*′) is very closely comparable with *C. heavisidei* in the general arrangement of the sinus systems. One or two differences may however

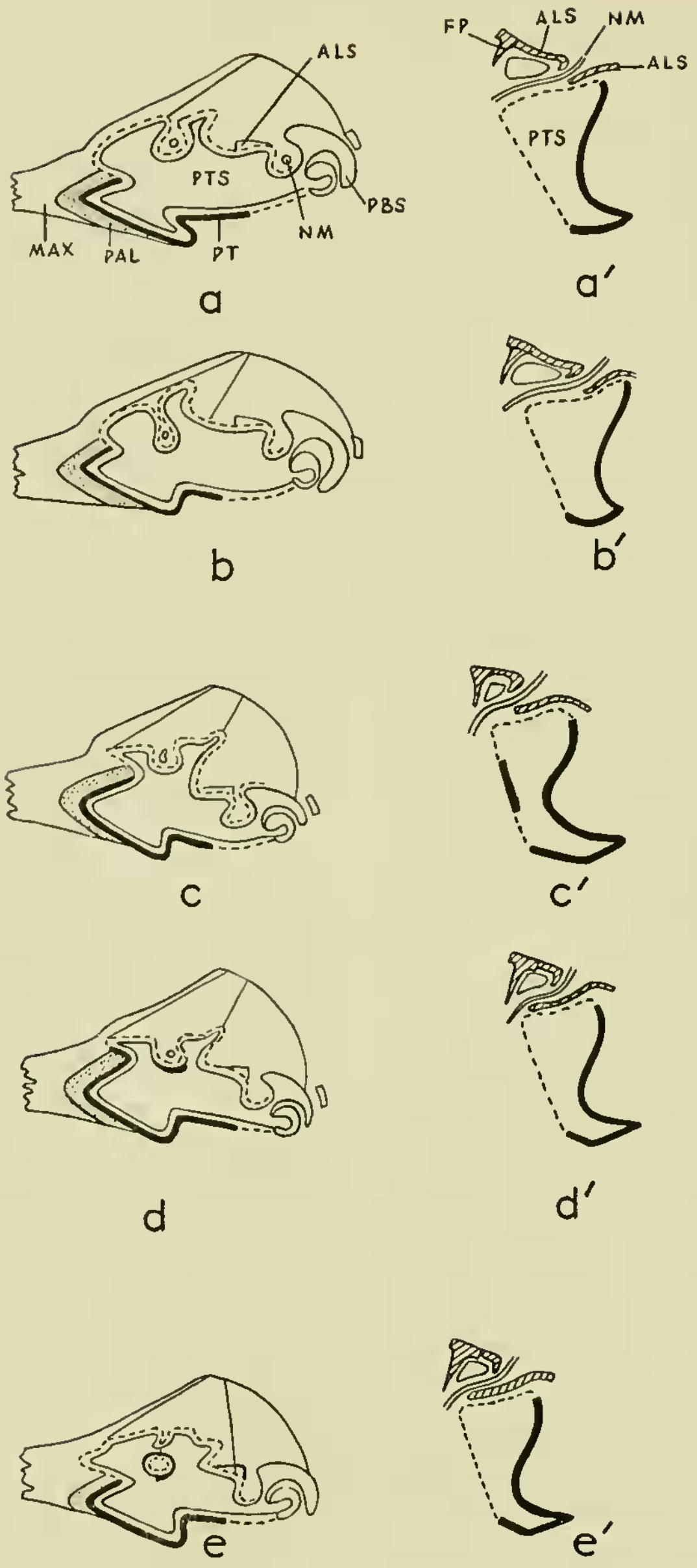

FIG. 20. Schematic diagrams showing invasion, distention and resorption of the pterygoid bone by the pterygoid sinus in *a* (longitudinal section), *a′* (transverse section), *Cephalorhynchus heavisidei* ; b, b′ *C. commersoni* ; c, c′ *Lagenorhynchus albirostris* ; d, d′ *L. acutus* ; e, e′ *L. obscurus*.

be noted. The pre- and post-orbital diverticula are in closer approximation to each other than in *C. heavisidei* because of the disappearance, on the under surface of the orbital process of the frontal, of a bony ridge, which in the latter species forms a barrier between the two diverticula. The pre-orbital diverticulum does not extend vertically between the frontal and maxilla as in *C. commersoni*.

The air sinus system of *Cephalorhynchus* dissociated from the skull is shown in Text-fig. 24*f*.

The genus *Lagenorhynchus* is one about which information regarding the air sacs has been obtained from plastic casts of *L. albirostris* (see p. 66), but for comparative purposes it is necessary to include it in the series of diagrams.

The pre-orbital and post-orbital sacs of this species (Text-fig. 20*c* and Pl. 38) are relatively small and of about equal development, although the latter has a small posterior extension onto the posterior face of the orbital process of the frontal. They do not meet above the optic nerve. There is nothing in the nature of an anterior sinus. In the sphenoidal region the sacs do not entirely cover the ventral aspect of the alisphenoids, which are quite stout, and present a broad lateral surface in the temporal fossa. The anterior portion of the space normally occupied by the peribullary sinus is filled with a complex of veins, and by very slender, bony trabeculae with air spaces between.

Ventrally and anteriorly the pterygoids override the palatines so that only a thin strip of the latter are exposed on the palate.

The dorsal lamina (Text-fig. 20*c*′) lacks any remains of the osseous content, but the lateral lamina is represented by a bony bridge which may be fenestrated (Pl. 37). The pterygoid hamuli are very wide, meeting in the middle line. They are fully excavated although not greatly inflated.

The 5th nerve branch on exit from the cranium lies within a short bony infundibulum formed by the alisphenoid.

Lagenorhynchus acutus (Text-fig. 20*d* and Pl. 39) differs very little in the distribution of air spaces from *L. albirostris*. A bony portion of the ventral lamina of the pre-orbital extension of the pterygoid persists, in this resembling the condition found in individual specimens of *Pseudorca crassidens*. The ventral extent of the palatine is even more restricted than in *L. albirostris*. The alisphenoid is more attenuated, and presents a much thinner surface laterally than in *L. albirostris*, indicating a greater lateral extension of the pterygoid sac. There is no apparent trace of a bony lateral lamina (Text-fig. 20*d*′). The bony infundibulum associated with the 5th nerve branch is much larger than in *L. albirostris* and almost touches the falciform process.

In *L. obscurus* (Text-fig. 20*e* and Pl. 40) the post-orbital lobe of the sinus projects anteriorly to a greater extent than in either of the two previously mentioned species and probably unites with the anterior lobe. The bony ridge on the ventral surface of the orbital process of the frontal is a very narrow crest. The pre-orbital lobe also shows an anterior extension under the ventral surface of the rostrum.

A small bony fragment of the superior lamina remains under the optic infundibulum. The lateral aspect of the alisphenoid (in the post-temporal fossa) is more extensive than in *L. acutus* but less than in *L. albirostris*.

The osseous lateral lamina of the pterygoid is wanting, as in *L. acutus*, and the alisphenoidal infundibulum of the 5th nerve is much shorter than in either of the previous species (Text-fig. 20*e′*).

The three species of *Lagenorhynchus* show a progressive development of a mesial excavation of the frontal by the post-orbital pterygoid lobe (not shown in figures). The excavation is present in *L. albirostris* as an ill-defined shallow depression lateral to the orbito-sphenoid. It is deeper and better defined in *L. acutus* and attains its maximum development in *L. obscurus* in which its mesial extremity is dorsal to the orbito-sphenoid.

In the genus *Grampus* (Text-figs. 21*a* and 25 and Pls. 41 and 42) the post-orbital and pre-orbital lobes are very much expanded laterally, the anterior sac of the pre-orbital lobe projecting onto the ventral surface of the rostrum.

The post-orbital lobe has a considerable extension posteriorly under the ventral surface of the frontal. The two lobes are in close apposition above the optic infundibulum and appear in some instances to coalesce. The alisphenoid is completely covered by the pterygoid sac and its lateral aspect in the post-temporal fossa is very much reduced. Two posteriorly projecting lobes of the sac in the sphenoidal region surround the 5th nerve branch exit in addition to the anteriorly projecting lobe of the peribullary sinus (Text-fig. 21*a′*).

The palatines (PAL) may or may not be overridden by the pterygoids (PT), in some specimens each palatine is divided by the forward extension of the pterygoid whilst in others a continuous band of palatine lies anterior to the pterygoid.

In the orbito-sphenoidal region part of the osseous content of the superior lamina of the pterygoid remains, but at the level of the foramen ovale no part. The pterygoid hamuli are widely excavated and dilated (Text-fig. 21*a′*).

In *Tursiops* (Text-fig. 21*b* and Pl. 43 and 44) the pre-orbital and post-orbital lobes are merged above the optic infundibulum ; if any separation of the two exists it must be very thin and membranous. The pre-orbital lobe is extended below the maxilla as a well-defined anterior sinus. As in *Grampus* two posteriorly projecting extensions of the sphenoidal portion of the pterygoid sac surround the exit of the 5th nerve branch. Laterally in the same region the whole of the alisphenoid is covered by the sac, the lateral edge of which projects beyond the lateral limit of the bone.

The dorsal lamina in the sphenoidal region (Text-fig. 21*b′*) has no osseous content but in the orbito-sphenoidal region a very small remnant persists. The hamuli are fully excavated but the lateral and mesial laminae are in close proximity.

Stenella (Text-fig. 21*c* and Pl. 45) closely resembles *Tursiops* in the general distribution of the air sac system. The pre-orbital and post-orbital lobes have a dorsal development resulting in the formation of a narrow ridge on the ventral aspect of the frontal (cf. *Lagenorhynchus obscurus*, see above. The pterygoid hamuli (Text-fig. 21*c′*) are rather more dilated than in *Tursiops*.

Delphinus in its turn is closely similar to *Stenella* except that the anterior sac extends very much further anteriorly below the maxilla (Text-figs. 21*d*, *d′* and Pls. 46 and 47). The pterygoid hamuli are less dilated than those of *Stenella*.

The air sinus systems of the Delphininae dissociated from the bones of the skull are shown in Text-fig. 25 *a–f*.

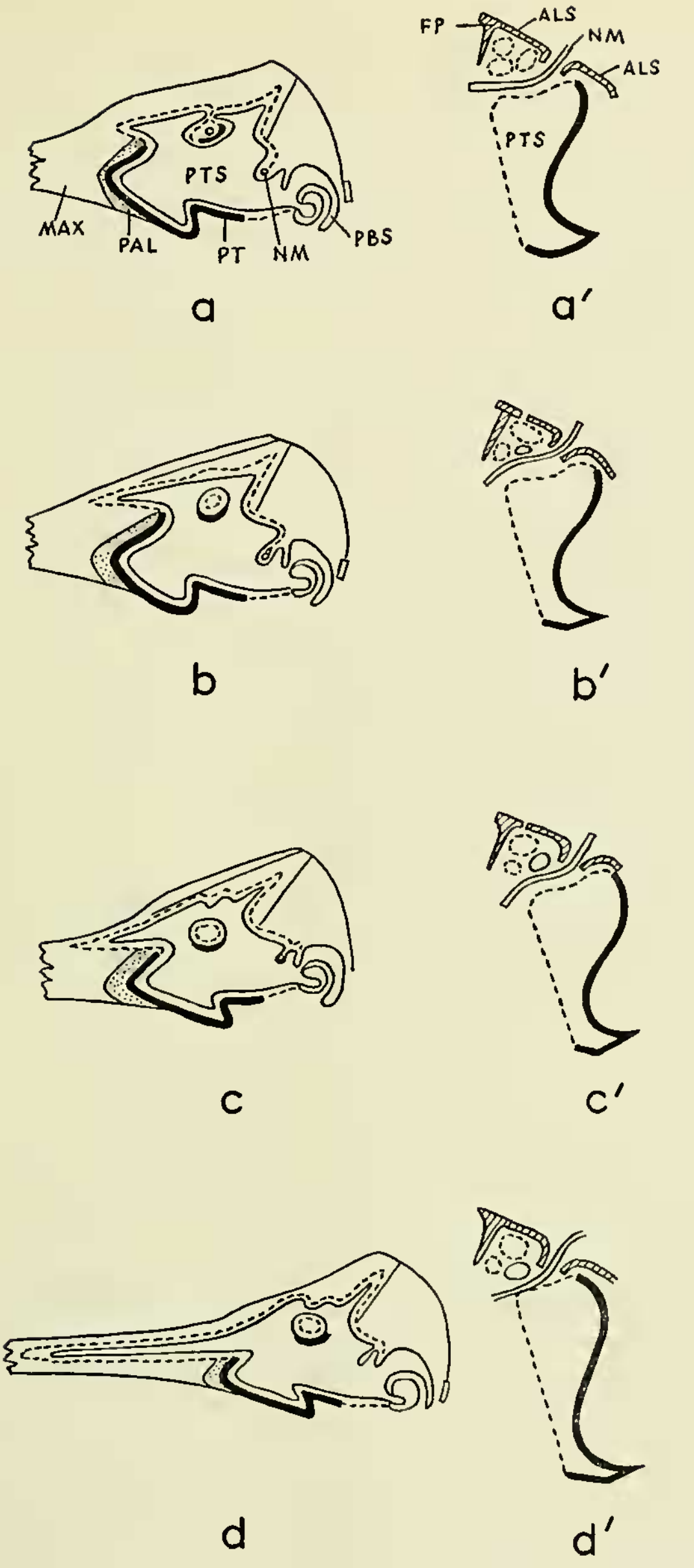

Fig. 21. Schematic diagrams showing invasion, distention and resorption of the pterygoid bone by the pterygoid sinus in *a* (longitudinal section), *a′* (transverse section), *Grampus*; b, b′ *Tursiops*; c, c′ *Stenella*; d, d′ *Delphinus*.

In *Steno* (Text-fig. 18*a* and Pl. 24) the pre-orbital and post-orbital lobes of the pterygoid sac are well developed and apparently coalesce above the optic infundibulum. As in *Delphinus*, *Stenella* and *Lagenorhynchus obscurus*, there is a conspicuous dorsal development of the pre-orbital and post-orbital lobes, forming deep cavities on the ventral surface of the maxilla and frontal bone which are separated by a smooth, obliquely antero-laterally directed ridge. There is a conspicuous anterior sinus. More posteriorly the sinus system is not so well developed. Thus a considerable portion of the alisphenoid (ALS) remains uncovered and the peribullary sinus does not project very far forward.

A considerable portion of the superior bony lamina of the pterygoid persists (Text-fig. 18*a*′) and the 5th nerve branch is invested in a double, bony infundibulum formed internally of alisphenoid (ALS) and externally of the superior lamina of the pterygoid. The pterygoid hamuli are fully excavated but not dilated, and they are in contact in the middle line.

The supra-orbital process of the frontal of *Sousa* (Text-fig. 18*b* and Pl. 25) is much narrower antero-posteriorly than in *Steno* and correspondingly the excavation of its ventral surface by the pre-orbital lobe is much smaller. The post-orbital lobe is rather more developed and extends high up on the posterior face of the frontal (in the temporal fossa), which is resorbed to the extent that the maxilla is exposed. The lateral expansion of the pterygoid sac in the alisphenoidal region is only moderate, so that a fair portion of the alisphenoid is exposed laterally. The peribullary sinus does not extend far forward.

In the specimen examined (No. 1914.1.14.1) a very minute fragment of the osseous lateral lamina remains in the alisphenoidal region but the dorsal lamina is not represented osseously.

The mesial lamina of the pterygoid (Text-fig. 18*b*′) has a deep concavity in its lateral aspect. The hamuli are excavated but not widely dilated and are separated widely in the middle line.

Text-fig. 23*e* and *f* show the air sac system, dissociated from the skull bones, in the Stenidae.

The chart shown in Text-fig. 26 shows a co-ordination of increasing specialization of the sinus system with the orthodox idea of classification of the Cetacea. There are however certain deviations from the conventional classification which will be discussed. The chart demonstrates a normal frequency distribution in the degree of specialization. Thus the majority of forms have a moderately specialized sinus development while the extremes at both ends are represented by fewer forms.

In terrestrial mammals, generally speaking, the pterygoid plate is a single laminar bone, and it is noteworthy that amongst the few exceptions to this rule e.g. *Myrmecophaga*, in which the pterygoid plate is excavated, the latter bone makes contact with the tympanic bulla.

In the Mysticeti, *Caperea* and *Balaena* show approximately the same poorly developed pterygoid sinus. *Eschrichtius* and the balaenopterids are slightly more advanced.

The Ziphiidae sa a family show a remarkable uniformity in the development of the sinus system, a development which, however, is not in the main trend of specialization—being almost wholly associated with the pterygoid hamuli.

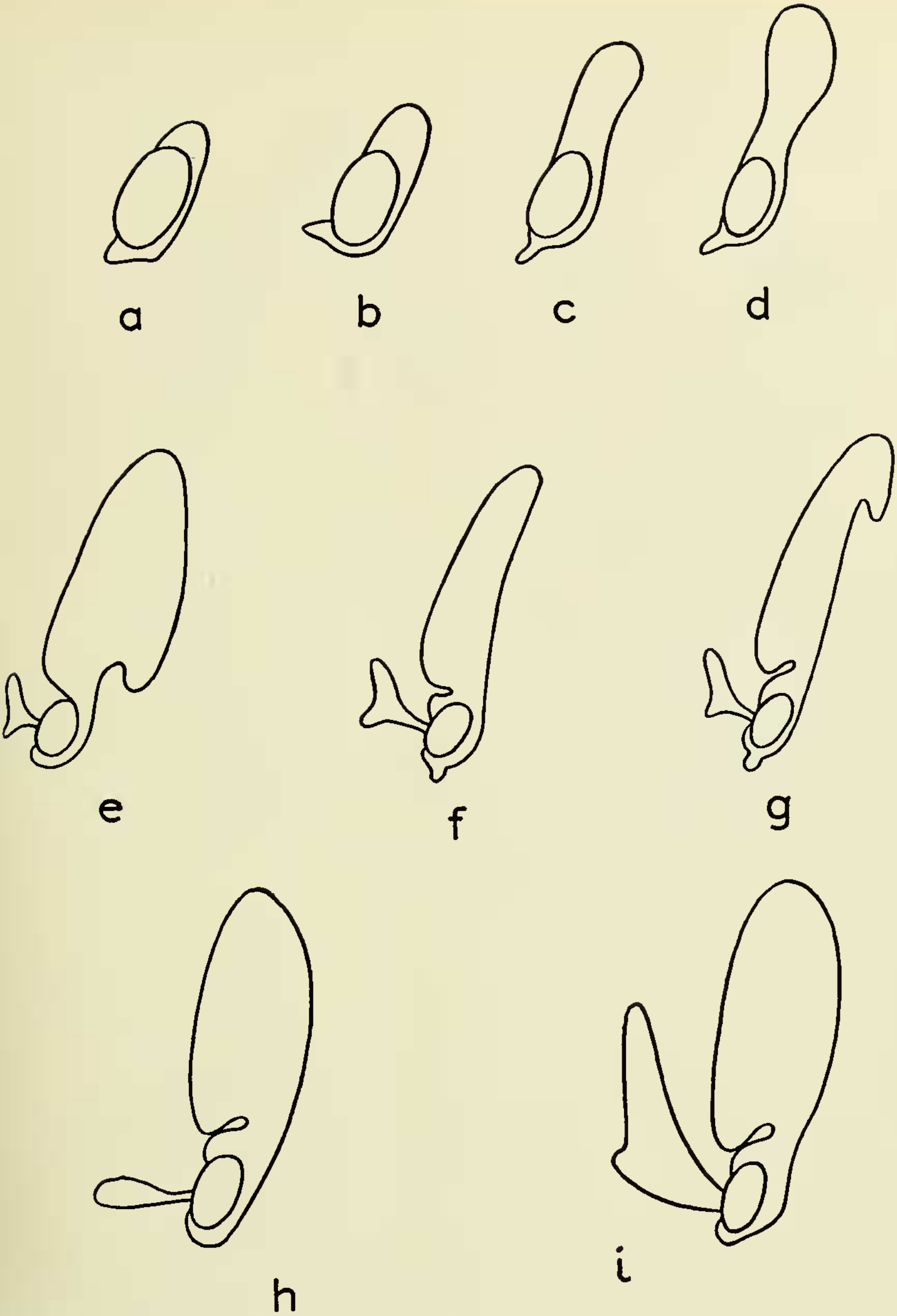

FIG. 22. Diagrams showing progressive distention in the horizontal plane of the air sac system.

a, *Caperea*; b, *Balaena*; c, *Eschrichtius*; d, *Balaenoptera*; e, *Ziphius*; f, *Monodon*; g, *Delphinapterus*; h, *Kogia*; i, *Physeter*.

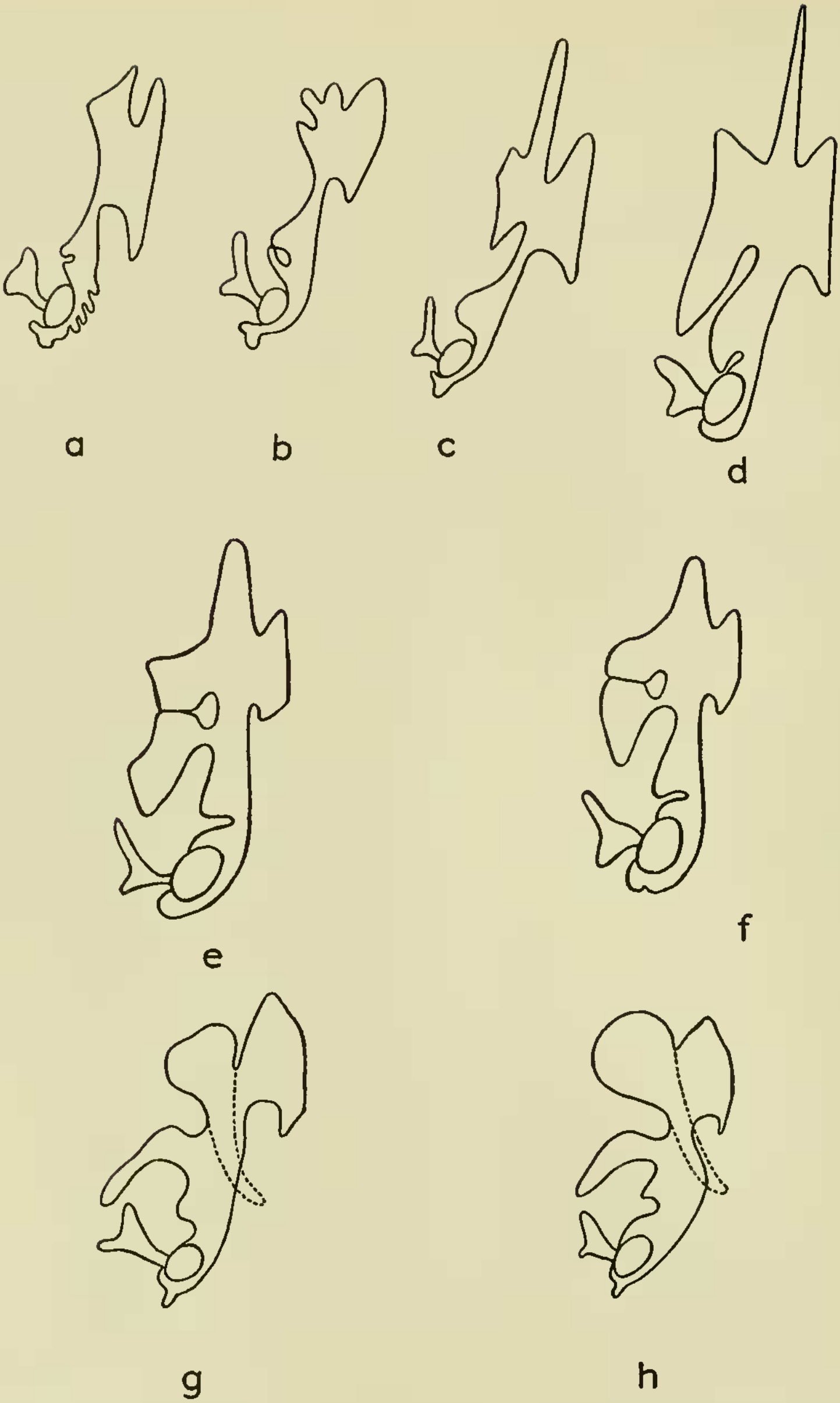

FIG. 23. Diagrams showing progressive distention in the horizontal plane of the air sac system.

a, *Platanista* ; b, *Lissodelphis* ; c, *Inia* ; d, *Lipotes* ; e, *Steno* ; f, *Sousa* ; g, *Phocaena* ; h, *Neomeris*.

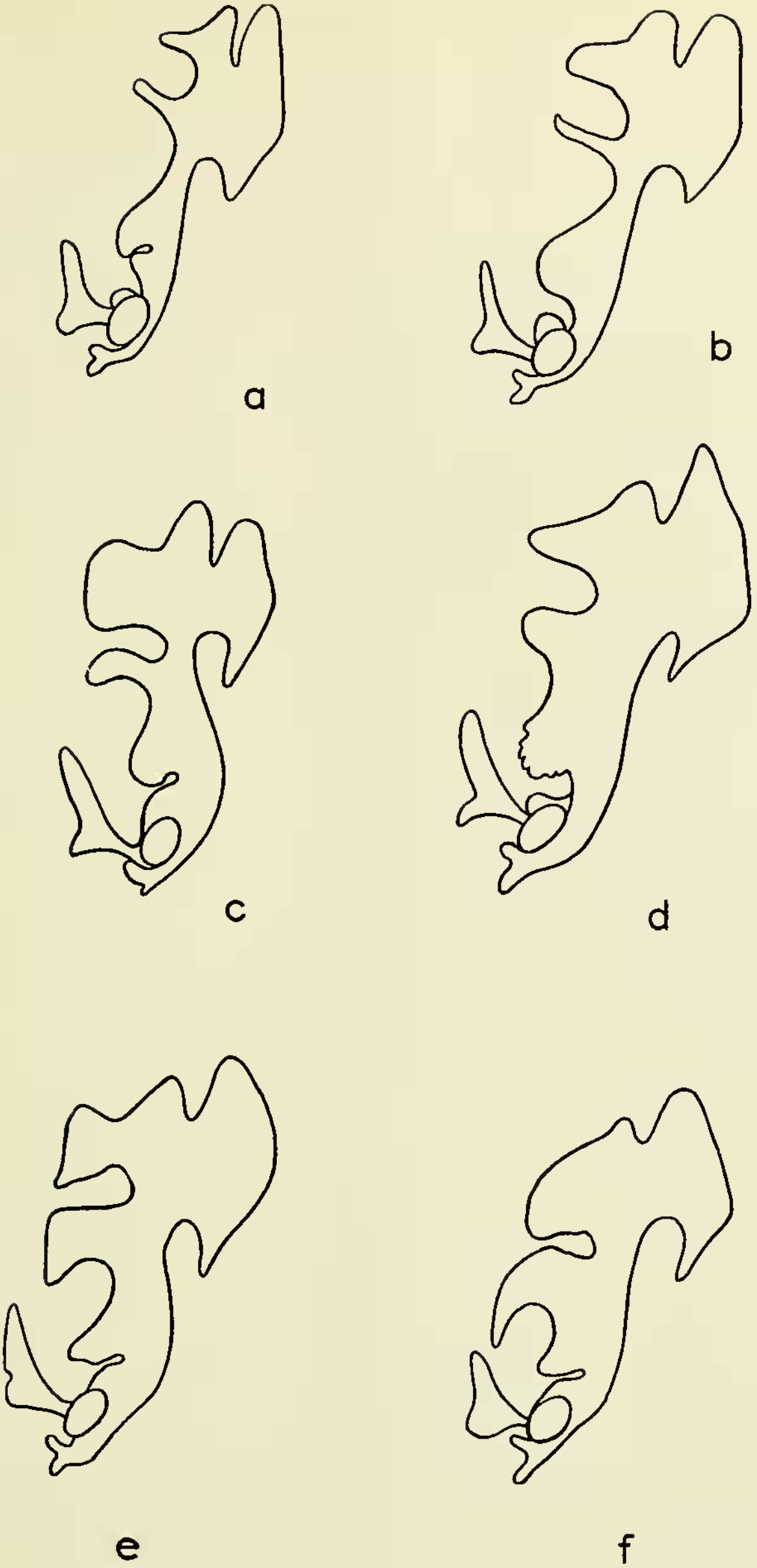

FIG. 24. Diagrams showing progressive distention in the horizontal plane of the air sac system.

a, *Pseudorca*; b, *Orcinus*; c, *Orcaella*; d, *Globicephala*; e, *Feresa*; f, *Cephalorhynchus*.



FIG. 25. Diagrams showing progressive distention in the horizontal plane of the air sac system.

a, *Lagenorhynchus albirostris*; b, *L. obscurus*; c, *Grampus*; d, *Tursiops*; e, *Stenella*; f, *Delphinus*.

In respect of the sinus system, the Monodontidae show a primitiveness which justifies the position in which they have been placed in the chart. Slijper (1936), for other reasons, distinguishes the Monodontidae by family ranking, but in respect of the pterygoid sinus system the removal of the family from the Delphinoidea and the creation of a separate super-family in which to include *Monodon* and *Delphinapterus* seems justified.

The Physteridae in some respects resemble the Monodontidae, e.g. in the limited enlargement of the pterygoid hamuli, but in other respects the former are considerably more advanced, there being no trace of superior or lateral laminae.

The Platanistidae, as represented by the four extant genera *Platanista*, *Stenodelphis*, *Lipotes* and *Inia*, cover nearly as wide a range of specialization of the sinus system as encountered in the whole of the rest of the Odontoceti as a sub-order. In this family *Platanista* itself is a mosaic of extremely primitive development and of a specialization encountered nowhere else in the Cetacea. The apparent extension of pneumatization to the maxillary crests is unique, and indeed, may be associated with the under-developed state of the sinus system in the pterygoid region.

Slijper's (1936) opinion about the primitiveness of *Sousa* and *Steno* presents a problem so far as air sinus development is concerned. In this they show a combination of primitive and highly specialized features. Thus in the sphenoidal region the development is poor and can be associated with the relatively large size of the temporal muscles. In the pre-orbital region there is evidence of the development having reached a stage comparable with that of *Tursiops*. In the chart they have accordingly been placed after the Platanistidae and before any of the remaining Delphinoidea.

The distinctness of the Phocaenidae, recognized in Slijper's classification, is supported in the sinus development by the presence, characteristic of this family, of an extension of the pre-orbital lobe into a vacuity between the maxillary and the frontal ; also in the unusual formation of the sphenoidal part of the sinus. For the rest they are rather more advanced than some of the Delphinidae, notably *Pseudorca*.

In the Orcinae, *Pseudorca*, *Orcinus* and *Orcaella* fall into a natural sequence of specialization. So far as *Pseudorca* itself is concerned it is found that considerable individual variation occurs ; thus there are some individuals with a more or less complete bony sheath covering the sinus system, whereas in others all trace of the lateral portions of this sheath has disappeared. In *Orcaella*, an incipient extension of the pre-orbital lobe between the frontal and maxillary is reminiscent of the development in this region, just mentioned as occurring in the Phocaenidae. *Globicephala* and *Feresa* show a general similarity to *Orcinus*, but the development of the pre- and post-orbital lobes is much greater, and in this respect *Feresa* is more advanced than *Globicephala*.

Skull features other than those related to the sinus system would point to *Lissodelphis* being comparatively unspecialized and to be placed in the neighbourhood of the Stenidae. The cranium is low, the backward extension of the pre-maxillae round the nares is limited, so that in this region the maxillae are exposed. The pre-maxillae are of equal length, those of the more advanced delphinids being further extended on the right side than on the left. The maxillae in the neighbourhood of the nares are covered by the mesial margins of the pre-maxillae. On the other hand, the reduced size of the post-temporal fossa and the teeth, which are hardly distinguishable from those of *Delphinus*, indicate a contrasting specialization.

In the sinus system also there is a mosaic of primitive and specialized features. Thus there is little lateral expansion of the system in the sphenoidal region and the paroccipital processes are incompletely excavated. There is no extension of the post-orbital lobe under the post-orbital process of the frontal. Anteriorly however, there is evidence of coalescence of the pre- and post-orbital lobes and a well marked anterior sinus, which is correlated with almost complete disappearance of the bony superior lamina of the pterygoid in this region.

A general assessment of the specialization of *Lissodelphis borealis* with regard to the sinus system particularly, but considering also other features of the skull, seems to justify the erection of the sub-family Lissodelphinae, with affinities with the more specialized genera of the Orcinae on the one hand, and the Cephalorhynchinae on the other.

In the genus *Cephalorhynchus* the chief advance in development is in the pre- and post-orbital lobes which are moderately approximated to each other. In addition, the post-orbital lobe has a narrow diverticulum which passes dorso-posteriorly under the post-orbital process of the frontal.

In the remaining genera, included in the Delphininae, there is a gradual augmentation of the sinus development. Within the genus *Lagenorhynchus*, *L. albirostris* still shows a partial bony lamina while *L. obscurus* in the close approximation of the pre- and post-orbital lobes resembles *Stenella*. The air sinus development in *Grampus* closely resembles that of *Tursiops*, and in general there appears to be justification for including it with the Delphininae rather than, as some authors have done, associating it with the Orcinae. *Tursiops*, *Stenella* and *Delphinus* show a progressive development of the anterior sinus which reaches its extreme extension in the last named genus.

The chart thus shows that in the evolutionary development of the sinus system there is an over-all sub-ordinal trend towards greater specialization, but also within the lower ranks of the hierarchy similar trends can be distinguished, even to the specific level in *Lagenorhynchus*.

FUNCTION

The mode of hearing of whales has for long been a subject of controversy among cetologists. Apart from those who maintained that cetaceans are unable to hear water-borne sounds, the most generally accepted hypothesis has been that these animals hear by bone conduction, that is by the perception of vibrations through the skull directly to the cochlea. It is proposed to show that this method of hearing is not only undesirable but also that it is impossible in normal circumstances in the cetaceans.

EXTERNAL AUDITORY MEATUS

In order to substantiate statements which will be made later about the function of the external and middle portions of the ear, it is necessary to review certain features of their anatomy.

	Pterygoid plate complete.	Disappearance of superior lamina in orbital region, partial.	Disappearance of superior lamina in orbital region, complete.	Increased lateral expansion of pre- and post-orbital lobes.	Lateral expansion of sphenoidal part, complete.	Posterior extension of sphenoidal part with encirclement of Vth nerve single & advanced.	Posterior extension of sphenoidal part with encirclement of Vth nerve double & advanced.	Coalescence of pre- and post-orbital lobes above the optic nerve.	Anterior sinus elongated.
Terrestrial Mammal	X								
Mysticeti									
Balaenidae									
Balaeninae									
Caperea									
Balaena									
Eschrichtidae									
Eschrichtinae									
Eschrichtius									



FIG. 26. Chart showing classification of the Cetacea in relation with increasing specialization of the air sinus system (For 'Delphinioidea' read 'Delphinoidea'; for 'Phocininae' read 'Phocaeninae'; for *Orca* read *Orcinus*. Circles indicate unverified features).

Several descriptions exist of the structure and course of the external auditory meatus in the Cetacea. The absence of an external pinna was noted by some of the earliest writers; Rondelet (1554) appears to have been the first to notice the external aperture of the ear. In the smaller odontocetes it is less than a millimetre in diameter and can only be detected by careful examination of the region behind the eye. The aperture in the larger, baleen whales is lenticular in shape, usually concealed in a groove and measures about 1 cm in its larger diameter.

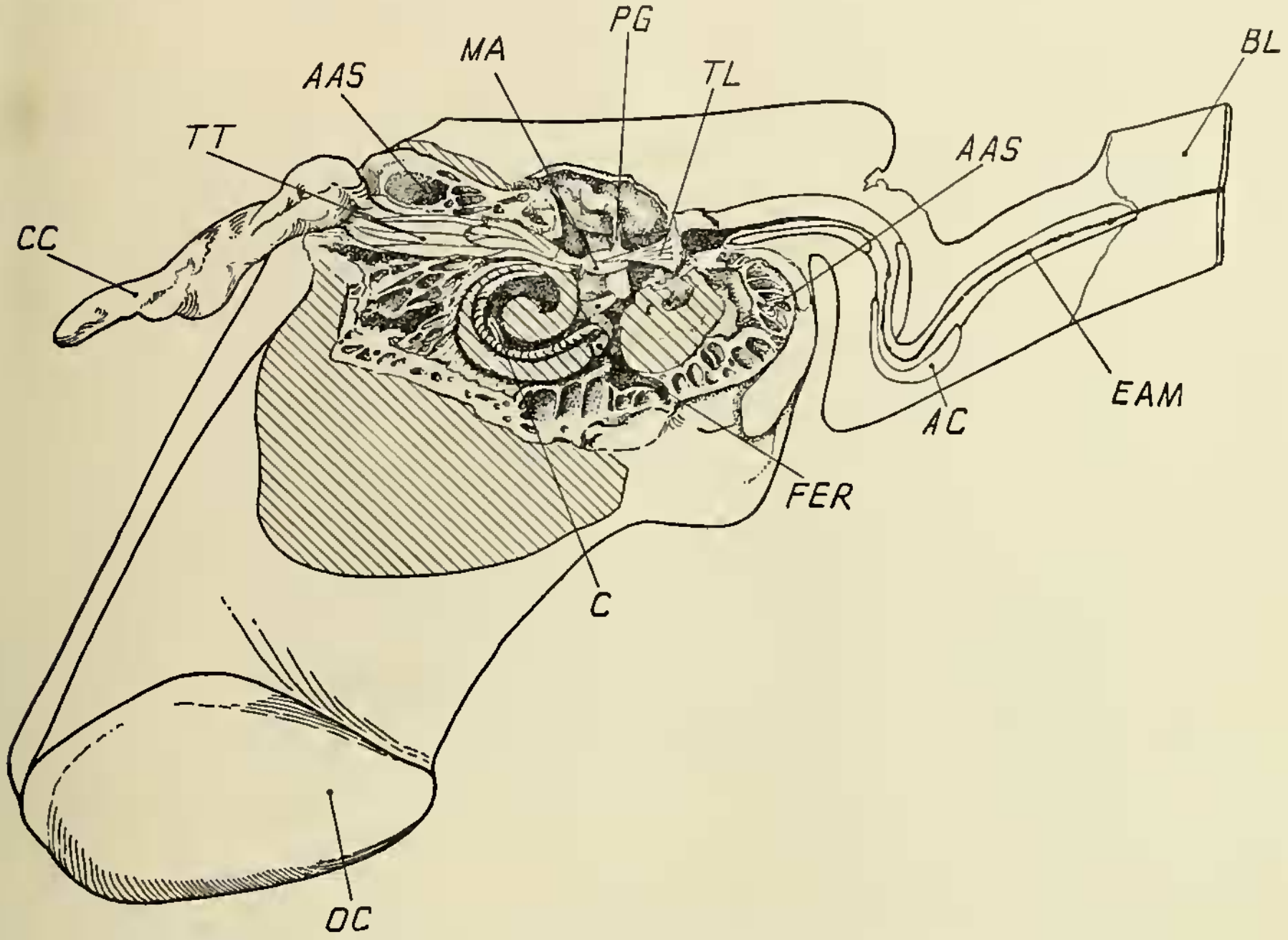

Fig. 27. Diagram of a dissection of the ear of *Globicephala melaena* (cf. Plate 49). Ventral view, left side.

The course of the meatus in *Globicephala melaena* from the surface of the body to the external aspect of the tympanic membrane is shown in Text-fig. 27. The tube (EAM) passes inwards more or less horizontally for about 2·5 cm, then dorsally and caudally in a sharp bend which occupies another 2·5 cm, rounding again to its original direction to its termination at the tympanic membrane. The mean axis of the meatus is at right angles to the long axis of the body.

According to Lillie (1915), in *Megaptera novaeangliae*, from the external orifice "a tube about 1/10 in. in diameter traversed the blubber which was about 3½ in. thick in this region. The tube was continued through the underlying tissue for about 2 in. and gradually decreased in diameter until it ended blindly. The meatus was closed up for about 3 in. of its course It widened out again to a diameter of rather more than an inch and maintained a more or less uniform size for the remainder of its passage to the tympanic bulla. The total length of the canal was about 1 ft. 9 in. in a humpback whale 40 ft. in length. The walls of the wide innermost portion were invariably pressed together." Lillie pointed out that Burfeld & Hamilton noticed that in several of the *Balaenoptera* examined by them the meatus was closed up for part of its course. This was further confirmed by the present writers during the

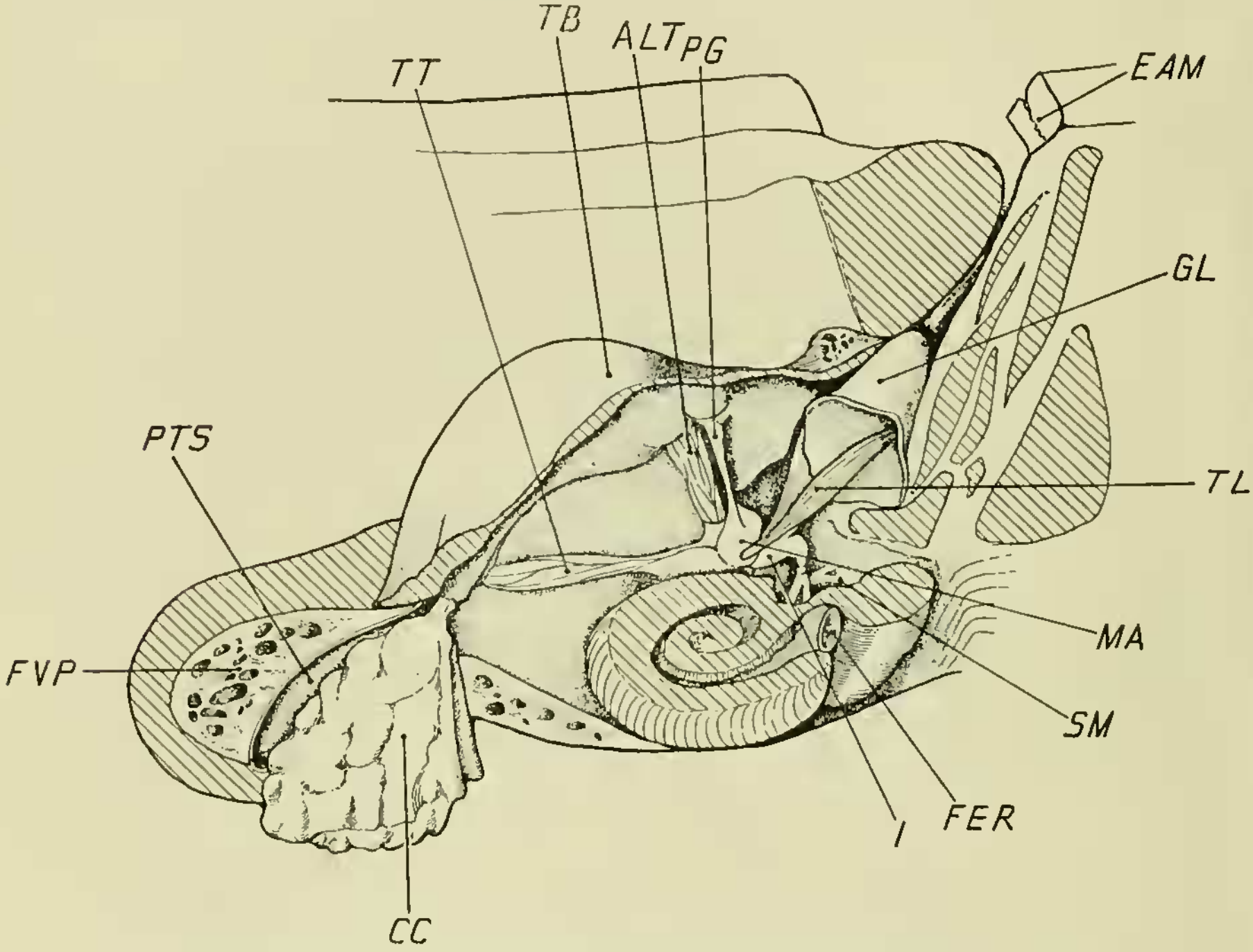

FIG. 28. Diagram of a dissection of the ear of a juvenile *Balaenoptera acutorostrata* (cf. Plate 50). Ventral view, left side.

dissection of a Fin Whale, *Balaenoptera physalus*, the closed portion of the meatus being partially invested in cartilage (see Pl. 51).

Carte & MacAllister (1867) reported that in *B. acutorostrata* the meatus was open. In the foetal specimen of *B. acutorostrata* dissected in this museum (Text-fig. 28) the meatus (EAM) appeared to be closed about $\frac{3}{4}$ in. from the external aperture but a section through the apparently closed portion (see Purves 1955) shows that a minute perforation exists.

In a foetal specimen of *Megaptera* sectioned and kindly lent by Professor D. V. Davies, St. Thomas' Hospital Medical School, it was noted that the external open portion was very shallow (Pl. 48*a*), perhaps because of the absence of a thick blubber layer. Internal to this opening was a closed portion (Pl. 48*b*) followed in its turn by an open tube, which soon became occluded for a short distance before opening out again in the innermost portion ending in the tympanic membrane (TM) (Pl. 48*c*).

In the Sperm Whale, Clarke (1948) describes the external auditory meatus as commencing as " a short blind sac which penetrates from the auditory aperture for a distance no deeper than the blubber thickness. The sac has somewhat thickened unpigmented walls. . . . Internally these walls are thrown into transverse folds. . . . Dissection reveals that the proximal portion running in the temporal bone is still intact. Also in two physically immature adults the external meatus after termination of its cavity was prolonged into a short solid stick representing the canal after obliteration of its lumen." Yamada (1953) also notes the presence of a solid cord beneath the blubber layer and could not demonstrate any lumen in it. In a specimen examined by the present writers, the apparently solid cord contained a number of small, spherical cavities lined by pigmented epidermis separated by short intervals in which no lumen could be detected.

More or less detailed descriptions of the structure of the meatus have been given by such writers as Carte & MacAlister (1868), Buchanan (1828), Hanke (1914), Yamada (1953) and Ryseenbach de Haan (1957). In general it appears that, as described by Carte & MacAlister, there are three layers forming the wall of the meatus. Lining the tube is an involution of the cuticle, this is usually pigmented, and in the specimen of *G. melaena* dissected (Text-fig. 27) it is of a dense black colour throughout its length. The cuticle is enveloped by a thick, rigid, fibrous, middle layer and external to this again a fibro-cellular layer, in which, according to Carte & MacAlister, a thin stratum of circular constrictor muscle is present.

Elastic fibro-cartilaginous masses are associated with the wall of the meatus in all those odontocetes which have been examined. In the mysticetes, Hanke (1914) says that the cartilage is absent but Carte & MacAlister (1868) and Boas (1912) have described, and the latter has figured, a cartilaginous mass associated with the meatus of *B. acutorostrata*. It has also been found in a recently dissected specimen of Fin Whale (see p. 135 and Pl. 51). It is suggested by the present writers that Buchanan's (1828) " globular substance " in *Balaena mysticetus* may in fact be the ear cartilage. In the Odontoceti the cartilage is more extensive than in the Mysticeti (*B. acutorostrata*). Its position and shape in *Phocaena phocoena* and *Lagenorhynchus acutus* are figured by Boas in his pls. 12 and 25.

The cartilage is also evident in the specimen of *G. melaena* dissected in this Museum (Text-fig. 27, AC). It occupies much the same position as that figured for *Ph. phocoena*. The more reduced condition of the cartilage in *B. acutorostrata* is indicated in Boas' figure.

Boenninghaus (1903) compared the ear cartilages in the Odontoceti with those of seals, and came to the conclusion that the former showed a further stage in the process of retraction of the pinna to that exhibited in seals, in which the pinna is withdrawn inside the meatus prior to submergence. Boenninghaus argued that the absence of external pinna in the cetaceans was correlated with their purely aquatic mode of life. Boas' paper on the ear cartilages of mammals (1912) supports this point of view.

Vestigial outer ear muscles have been described by Boenninghaus (1903) (see Pl. 1, fig. D), Beauregard (1894) and Hanke (1914), the last discussing their homologies in detail and producing a comparative table of his own and other workers' conclusions. Hanke (p. 303) cites the presence of sweat glands in the meatus of the baleen whales and suggests, from the absence of sebaceous glands, that the plug in contact with the " glove finger " of the tympanum is not a true ear wax but a secretion similar to this. However it is generally accepted that the glands producing ear wax in man are modified sweat glands and there appears to be no reason why this should not apply to the Cetacea also. Carte & MacAlister described " a very distinct series of ceruminous glands the orifices of whose ducts were visible in the lining membrane".

A characteristic feature of the external meatus of the rorquals and the Humpback is the elongated plug of wax and desquamated epithelium which caps the " glove-finger " extension of the tympanic cavity. Typically this is an elongated, roughly conical mass, brownish in colour, scored longitudinally by numerous shallow grooves and flattened dorso-ventrally throughout its length. It fills the meatal cavity mesial to its blind portion. The base of the cone is occupied by a rounded, conical concavity which fits onto the distal end of the " glove-finger ". The homologies of the " wax-plug " are indicated by Purves (1955).

Buchanan's (1828) description of the meatus in the Greenland Right Whale (*Balaena mysticetus*) indicates that in this species the lumen is continuous throughout its course. Buchanan's particular interest was in the ceruminous secretion of the ear and he describes it as being of a greyish-blue colour and in no great quantity.

The evidence from the Delphinidae is that the lumen of the meatus is continuously open from the exterior to the tympanic membrane. From this it may be assumed that the presence of the ear-plug in the rorquals and Humpback is a direct result of the closure of the meatus along part of its length. The absence of an ear-plug in the Sperm Whale has yet to be confirmed.

TYMPANIC MEMBRANE

Hunter (1787) gives a brief description of the tympanic membranes of Toothed and Baleen Whales, and Buchanan (1828) describes the membrane of *Balaena mysticetus* and *Monodon monoceros*. Of more recent descriptions of this structure in odontocetes, those of Beauregard (1894) and Boenninghaus (1903) coincide in a general way with the condition found in the specimen of *Globicephala melaena* examined by the present writers (Text-fig. 27, TL and Pl. 49).

The general shape of the Narwhal tympanic membrane was described by Buchanan as comparable with a convolvulus flower in having an oval, concave, exterior surface and, within the tympanum, a core tapering to a very attenuated attachment on the malleus. The condition in the recently examined *Globicephala melaena* is more in agreement with Boenninghaus' description of what he found in *Phocaena phocoena*. Thus the external aspect of the tympanic membrane is more shallowly concave than funnel-shaped. Hyrtl's (1845) description of the tympanic membrane of the Narwhal disagrees with Buchanan's. In this species, as in the Bottlenosed Dolphin, he describes the membrane as presenting externally not a single, but a double concavity in the form of two pits separated by the rectilinear base or origin of the extension of the tympanic membrane to the malleus. In the recently examined *Globicephala* neither trace of the rectilinear base of Hyrtl, nor of the linear depression described by Beauregard, could be detected. In *G. melaena* the internal extension of the tympanic membrane to the malleus is not centrally placed in relation to the external concavity, but displaced towards the posterior margin of the tympanic annulus, so that anterior to the extension there is an incipient depression on the internal face. This condition corresponds to that in the Common Porpoise described and figured by Boenninghaus. The internally extending " fleshy process " of the tympanic membrane is flattened, triangular and elongated, its apex being attached to the malleus (Text-fig. 27, MA). The flattening is obliquely antero-posterior so that the ventral margin of the process is slightly in advance of the dorsal.

The meatal aspect of the " membrane " is covered by a densely black epithelium continuous with that of the external auditory meatus. In the specimen dissected, the coarse, fibrous structure of the extension to the malleus can easily be seen with the naked eye (Pl. 47). The bundles of fibres spring from a very narrow attachment on the small tubercle of the malleus, and diverge in straight lines in their course to the tympanic annulus. On the anterior aspect these fibres extend almost to the same extent as do those on the posterior aspect. As the fleshy process is not centrally placed, there is an interval between the outward termination of the fibres and the anterior margin of the tympanic annulus which is closed by the mucous membrane of the tympanum internally, and by the epithelium of the external meatus externally. Boenninghaus found that in *Phocaena phocoena* the drum membrane had irregular areas of fibreless tissue, anteriorly between which the fibres continued to bony prongs on the annulus. In *G. melaena* the separation of the fibres from the anterior margin of the annulus is more complete so that a much larger fibreless region is present, reminiscent of the *pars flaccida* of the human tympanic membrane.

Boenninghaus saw both radial and circular fibres and made the significant statement " all the radial fibres continued into the spur and the latter owes its solidarity to their thickness and stiffness. The circular filaments proceed fairly high up the spur. *All in all the spur is nothing less than the extended centre of the drum.*"

As with the Odontoceti, so with the Mysticeti, the characteristic tympanic membrane has attracted the attention of such workers as Hunter (1787), Carte & MacAlister (1868), Beauregard (1894), Hanke (1914), Lillie (1915) and Kernan (in Schulte 1916) who concentrated on the rorquals. Home (1812) and Buchanan (1828) described the tympanic membrane of the Greenland Right Whale.

Lillie employs the similarity of the membrane to a glove finger when describing it. In his specimen the walls of the sac were 1/10 in. in thickness and consisted chiefly of white fibres and yellow elastic tissue. There was no evidence of nerve cells, nerve fibres or muscle fibres in the tissue. " From the upper surface of the sac, in the median line, a ligament about an inch long and 5 mm in diameter projects towards the tympanic cavity. The ligament is continued along the sac in the opposite direction as a ridge. . . . The mouth of the sac opens into the tympanic cavity while the outer portion projects into the external auditory meatus. The ligamentous process passes under the junction of the malleus and incus and becomes attached at its proximal end to the very much reduced manubrium of the malleus."

A re-description of the tympanic membrane in the light of the evidence furnished by a recently dissected *Balaenoptera acutorostrata* specimen (Text-fig. 28 and Pl. 50), and a re-examination and further description of Lillie's specimen of *Megaptera novaeangliae* is required. Fundamentally the tympanic membranes in these two specimens are similar.

From its attachment on the manubrium of the malleus (MA) the ligament (TL) extends in the direction of the external meatus (EAM) as a broad band which widens perceptibly as it proceeds outwards. The posterior half of the band is much stouter than the anterior, and it is the posterior portion which continues into the glove finger for about one third of the latter's length. None of the fibres of the posterior portion of the ligament is attached to the tympanic annulus ; a deep, tapering concavity penetrates into its fibres from its outer, meatal surface. The tympanic membrane as a whole is thus composed of two distinct parts, (1) a fibrous portion with an external concavity and (2) a non-fibrous portion which projects into the external auditory meatus. The fibrous portion is exactly similar to, and comparable with, the so-called triangular ligament found in the Odontoceti, while the glove finger represents a greatly enlarged development of the fibreless region mentioned above in the descriptions of *Globicephala* and *Phocaena*, and represents a further dissociation of the fibrous portion of the tympanic membrane from the tympanic annulus.

Beauregard (1894) homologizes the glove finger with one of the accessory air sacs—the sac moyen. This is referred to on page 10 *supra*.

The description and figures of Home (1812) and Buchanan (1828) of the tympanic membrane of the Balaenidae, as exemplified by *B. mysticetus*, make possible a close comparison with this region in the Balaenopteridae. Thus the hemispherical extension into the external meatus can be identified with the glove-finger, and the so-called valvular process of Buchanan corresponds with the fibrous portion found in the balaenopterids. From Home's figure it would appear that the fibrous portion has a more extensive attachment to the tympanic annulus than exists in the balaenopterids; this characteristic, together with the broad triangular shape of the fibrous portion of the membrane extending to the malleus, is related to the more limited extension of the glove finger into the external auditory meatus. The general construction of the tympanic membrane in the Balaenidae is intermediate between that of the Odontoceti and the Balaenopteridae. Incidentally, with reference to the membrane of *B. mysticetus*, Knox (1859) corrected the erroneous impression of Buchanan that it was muscular.

Ridewood's (1922) description of the skulls of foetal Humpbacks and rorquals includes accounts of the developmental appearance of the tympanic membrane. He discusses comprehensively the interpretations of earlier workers, including particularly those of Hanke, Beauregard & Lillie. His references briefly summarized are as follows. In a 6-in. foetus of *Megaptera* the tympanic membrane is still flat and horizontal in position, forming part of the roof of the inner end of the external auditory meatus. He states that the membrane is supported on three sides, anterior, mesial and posterior, by the tympanic annulus and that its outer edge passes into a mass of fibrous tissue attached to the lower edge of the squamosal bone. He draws attention to a pale streak on the area referred to by him as the tympanic membrane (his fig. 4, p. 223), and states that it marks a tract of fibrous tissue " to the mesial end of which the extremity of the manubrium mallei is attached, it is this fibrous tissue that develops later into the long conical ligament of the adult tympanic membrane ". Further on in this paper (p. 244) Ridewood states that " there seems to be no question that the thimble-shaped membrane of the 27-in. foetus, and presumably the glove-finger membrane of the adult whale, represents the whole of the tympanic membrane." This view is not held by Beauregard, Hanke or the present writers.

Considering first the boundaries of the tympanic membrane as mentioned above, the sagittal sections of Prof. Davies' 6-in. Humpback foetus indicate that Ridewood set too wide a limit to the extent of the membrane. The tympanic membrane occupies less than a half of the area within the tympanic annulus, in a position corresponding to the pale streak to which Ridewood refers. The relation of the tympanic membrane (TM) both to the external meatus (EAM) and to the manubrium mallei (MM) are clearly shown in the section (Pl. 48*c*). The external face of the membrane forms a deeply concave, conical depression on the roof of the external auditory meatus and is comparable in shape with the tympanic membrane of the adult odontocete.

Ridewood's interpretation of the glove-finger of the adult as the whole of the tympanic membrane is at variance with the present writers' conclusions. As already stated the tympanic membrane is represented by the fibrous ligament *and* the glove finger and not by the glove finger alone. In this connection it may be pointed out that, in the 6-in. foetus (Davies' specimen), while the tympanic membrane is still horizontal in position, it is already divisible into two parts. Firstly, the portion already described and shown in Pl. 48*c*, and, secondly, Pl. 48*d* shows that the external meatus continues beyond the limit of the manubrium mallei and is roofed over by a portion of the tympanic membrane which is flat, and apparently lacking distinct fibrous structure. It is from this portion that the present writers believe that the glove finger is developed.

MIDDLE EAR

As in the Mammalia generally, the chain of auditory ossicles is composed of three elements. Numerous descriptions exist of their form in the Cetacea (Camper, Hyrtl, Beauregard, Carte & MacAlister, Boenninghaus, Yamada, Reysenbach de Haan). It is therefore not proposed here to give a detailed description but to refer to those aspects of their construction which do not appear to have been mentioned previously. A general impression of their shape and arrangement is shown in Text-figs. 27–29.

The fusion of the processus gracilis of the malleus (PG) with the tympanic bulla (TB) is frequently considered to be peculiar to cetaceans but, according to Boenninghaus this condition is fairly common in other mammals. He says " it is always fused (to the tympanic ring) at the Glasserian fissure in the newly born human. In man however, and in many (other) mammals, the fusion later dissolves and the connection disappears. In other beasts the connection continues throughout life. Hyrtl includes monkeys, carnivores and insectivores and, mistakenly, man. I had the opportunity to examine these connections in the lion and hedgehog and it really is a bony growth." Boenninghaus goes on to contrast the stoutness of the processus gracilis of the malleus in whales with its slenderness in other mammals, but it should be pointed out that in the Cetacea generally, while the process is indeed stout in forms such as the rorquals and Humpback it is of much more slender construction in the Right Whales. Again, in the odontocetes, while the attachment of the process to the tympanic ring is elongated its thickness is very greatly reduced. The attachment in *Phocaena phocoena* is so attenuated that, with the exception of Boenninghaus, authors have described it as being unfused.

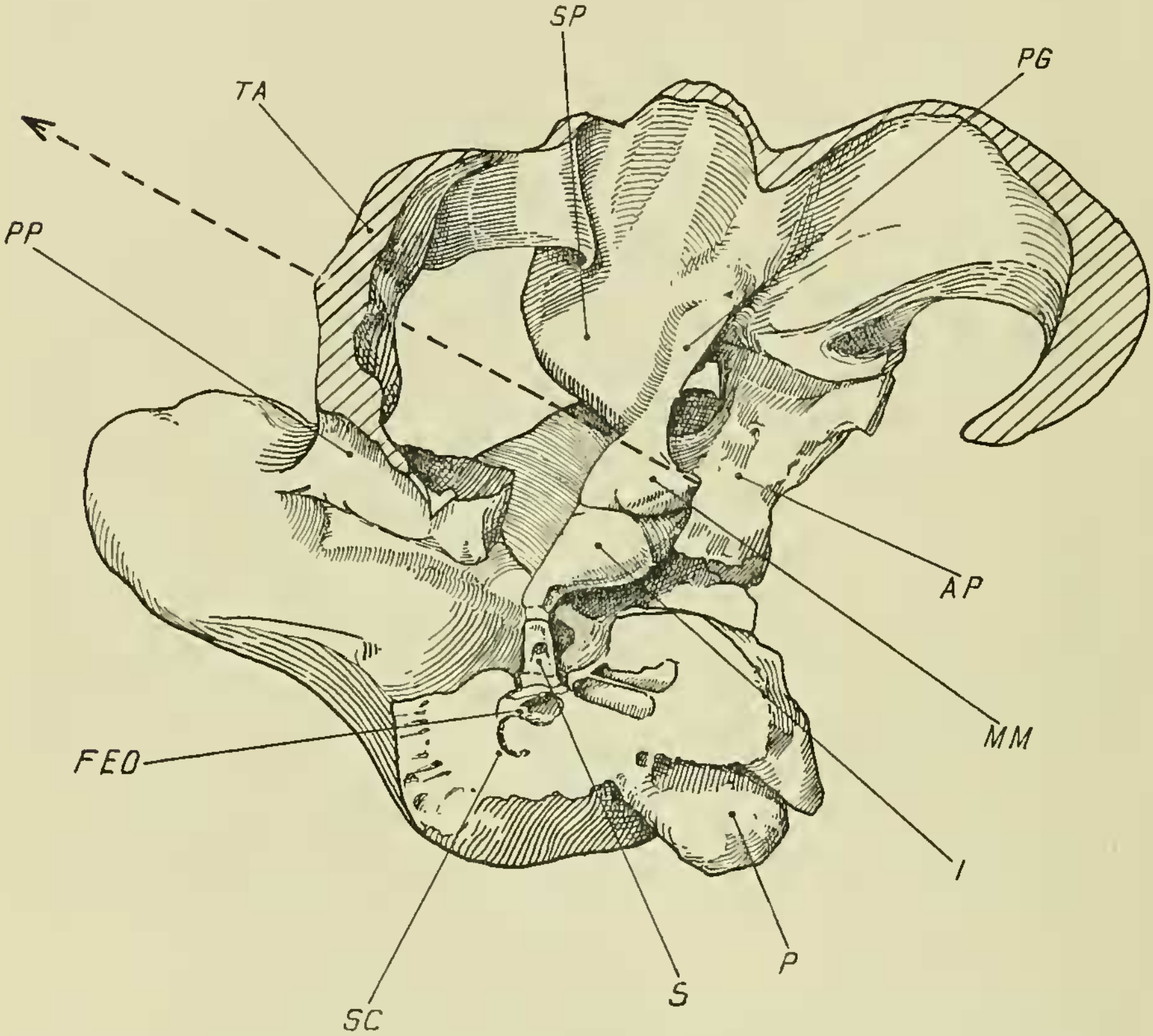

FIG. 29. Right tympanic annulus and auditory ossicles of a Humpback Whale, *Megaptera novaeangliae*. The dotted line indicates the long axis of the tympanic ligament.

MALLEUS

(a) *Anterior process.* For the later consideration of the functioning of the malleus, it is necessary to describe, in some detail, aspects of its structure not previously emphasized. Starting with the processus gracilis (PG) it will be seen from the figure of its anterior aspect (Text-fig. 29), that it is closely associated with the sigmoid process (SP) of the tympanic bulla (TB) which forms a buttress attached to about four fifths of its lateral border. The mesial border of the process is free from any attachment throughout its length. Between these two borders, which are thickened, is a roughly rectangular area of much thinner bone, the borders and the thinner portion forming what may be described as a channel girder. In posterior view the process forms the convexity of the girder, and it will be seen from Text-fig. 29 that this surface is fused to the sigmoid process at a deeply grooved, arcuate junction extending from the meso-ventral to the dorso-lateral edge of the process. Examination of the junction in strong light shows that the dorso-lateral part of it is translucent, the bone in the region being extremely thin, even in the adult rorqual. In general construction the odontocete processus gracilis is essentially similar to that just described for the rorqual except that the concavity of the "girder" is not so emphasized.

(b) *Manubrium.* Unlike the typical, handle-shaped manubrium of most mammals, including man, that of cetaceans is short, stout and roughly conical (Mysticeti) (Text-fig. 29) or globular (Odontoceti) in form (Pl. 49). Its mass is comparable with that of the head of the malleus. At the lateral end of the inferior surface in the Mysticeti, a small promontory is identified as the short process (processus brevis). In the Odontoceti a small pointed process, directed towards the head, and situated about midway along the length of the lower surface of the manubrium, has been identified by Hyrtl as the short process. In the Mysticeti the attachment of the tympanic membrane to the malleus extends to the whole length of the posterior face of the manubrium, whereas in the Odontoceti this attachment is restricted to the short process. On the proximal edge of the anterior aspect of the manubrium a small tubercle forms the point of attachment of the tensor tympani muscle (Text-figs. 27 and 28 TT).

(c) *Head of the malleus.* The massive head of the malleus (Text-fig. 29) is deeply marked by two large facets making a re-entrant angle on its posterior aspect. Both these facets have smoothly convex surfaces covered with articular cartilage, which, with corresponding facets on the incus, form part of a synovial joint. The radii of the convexities, as well as that of the arcuate junction between the two facets, lie approximately at right angles to the long axis of the tympanic ligament (see Text-fig. 34*d*).

INCUS. In general shape the incus (I) is in the form of a short, wide-based cone, the apex of which is curved upwards to end in the facet which articulates with a corresponding facet in the stapes (Text-fig. 29). The base of the cone forms the larger of two facets which articulate with the malleus. The smaller facet is approximately at right angles to the larger on the ventral aspect of the ossicle. For articulation with the malleus, both facets are shallowly concave and their line of junction is also concave. Like the facets of the malleus these also are furnished with articular cartilage. The short process is a short, conical projection directed anteriorly in line with the lateral margin of the processus gracilis of the malleus. The facet for articulation with the stapes is an oval, the long axis of which is parallel to the larger incudo-malleolar facet.

STAPES. The stapes (S) is less obviously stirrup-shaped than in most other mammals and although in the rorqual an intercrural foramen exists, this is not so in all cetaceans. There is no well-defined neck separating the head from the crura and the foot is oval in shape, with a smooth, flanged edge moulded to fit precisely into the fenestra ovalis (FEO). Contrary to what has been stated by many authors the present writers have been unable to find any evidence that the stapes is ankylosed to the fenestra ovalis. It is believed that the impression of fusion is due to the perfect fit of the foot of the stapes in the fenestra ovalis.

MUSCLES OF THE MIDDLE EAR. As Hunter (1787) pointed out, the cetacean tympanum, like that of other mammals, contains two muscles, the tensor tympani and the stapedius (Text-figs. 26 and 27, TT and SM).

In the Odontoceti (*Globicephala melaena*) (Text-fig. 27) the tensor tympani (TT) arises from the dorsal wall of the tympanic cavity near that part which transmits the Eustachian tube. It is attached in a small depression at the tip of the manubrium mallei. Although it is directed approximately in line with the long axis of the tympanic ligament (TL) as viewed ventrally, the two attachments are displaced from each other by about 2 mm when viewed in the lateral aspect. The muscle is intimately associated with the cavernous body (CC) of the tympanic bulla to the extent that Beauregard (1894) regarded the muscle as the attachment of the cavernous body of the malleus.

The stapedial muscle is in the normal position.

The evidence produced by Boenninghaus (1903) and Kolmer (1907), among others who examined the inner ear of cetaceans, is to the effect that the essential organ of hearing, i.e. the cochlea, is comparable in general structure with that of terrestrial mammals. Indeed the essential organ of hearing in certain respects gives indications of being sensitive to a much wider range of frequencies than that of most mammals.

THEORETICAL CONSIDERATIONS AND EXPERIMENTAL EVIDENCE

The Hydrodynamic Function of the Air Sacs

It has often been asserted that the function of the auditory ossicles is concerned with the matching of the incoming air vibrations with those of the fluid vibrations of the cochlea, and it is on this basis that it has been maintained that there is no necessity for an ossicular system in the Cetacea. The fact is that the Cetacea have a functional chain of ossicles and that the stapes is movable in the oval window. The fenestra rotunda is also functional. This implies that some kind of molar, as distinct from molecular, disturbance of the cochlear fluid is required to produce the sensation of hearing. This again points to the maintenance of an air space in the middle ear. The question of the manner in which this air space persists in spite of the enormous variations in pressure to which it is subjected is directly related to one of the functions of the pterygoid sinuses. Amongst other functions, which will be enumerated later, is that concerned with the regulation of pressure on either side of the "ear drum". In the Cetacea (see above p. 113) the pars flaccida is modified and sometimes greatly enlarged, and the pars tensa drawn out in the form of a ligament, the tension on which appears to be maintained by the internal pressure on the pars flaccida and by the operation of the muscle described on p. 135. In mammals, the pressure in the middle ear cavity is adjusted according to immediate necessities, by increments of air from the respiratory tract, by way of the Eustachian tube. In the Cetacea the only opportunities for effecting an adjustment by this method are when the animal surfaces for breath. It seems likely that the pterygoid air sinuses form a reservoir for this process of pressure regulation, and that the maximum depth to which the animal can dive is in relation to the ultimate compressibility of the air sacs and the size of the tympanic cavity.

It has been stated above (p. 30) that the sinuses and tympanic cavity are filled with a foamed, oil-mucus emulsion so that the compressibility of the air sacs ultimately depends on that of the foam and the rigidity of the surrounding tissues.

The question naturally arises about the persistence of the gas in the foam cavities and the maintenance of acoustic isolation (see p. 121) under great pressures. Experiments were made on the relation to pressure of gelatinous, albuminous and detergent foams. The foam to be investigated was placed in a pressure-tight, optical cell and observed by transmitted light through a vertically mounted, low power microscope with micrometer eyepiece. Pressure was applied by pumping B.P. liquid paraffin into the cell (in direct contact with the foam) and was measured on a Bourdon gauge. As pressure increased above atmospheric, the gelatinous foam bulk volume decreased considerably and the foam structure was replaced by a system of spherical air bubbles dispersed in liquid. These bubbles were a few microns in diameter and separated by distances of comparable magnitude. The system was stable at higher pressures, and the bubbles had not disappeared after 20 minutes at 100 atmospheres. On release of pressure to one atmosphere the foam structure reappeared. Using egg albumen, the foam structure was again replaced by air bubbles, dispersed in a continuous liquid phase, which persisted at 100 atmospheres. The bubbles were of less regular size and shape than in gelatin. Using the detergent, the foam structure collapsed under pressure and no bubbles were visible at higher pressures.

From the results of the experiments just described, and assuming that the naturally-occurring foam behaves in a similar manner to that of gelatinous and albuminous foams, it may be deduced that, even at the greatest depth to which cetaceans normally dive, air bubbles would persist and there would be a sound reflecting system surrounding the essential organ of hearing. Some of the smaller cetaceans are capable of undergoing very rapid changes of depth and are also dependent upon a very acute sense of directional hearing. The rate of change of bulk volume of the foam would be important because of the variation in pressure involved in such rapid changes of depth. Acoustic efficiency must ultimately depend on the maintenance of fairly constant conditions of sound reflection and absorption round the essential organ of hearing.

The air sacs themselves are so extensive that their contraction would cause disruption of the adjacent musculature were it not for the intervention of some space-filling mechanism. It seems that the fibro-venous plexus which surrounds the sacs is ideally suited for this purpose, because there would be reciprocal filling of the plexus with reduction in the volume of the sinuses. A conventional venous plexus might be expected to be turgid at normal atmospheric pressure, but the pterygoid plexus of the cetacean is strongly adpressed between two sheaths of tough, fibrous tissue which, as previously stated, has been derived from the periosteum of the de-ossified pterygoid laminae. It is reasonable to suggest that the venous blood pressure, which is assumed to be zero at atmospheric pressure, must attain a value of at least two or three atmospheres before any swelling of the vessels could take place. There is also evidence to show that there is positive pressure in the pterygoid sinus under normal surface conditions if the squirting of foam from the newly cut sinus can be so interpreted. These factors suggest that the pterygoid cavities have an initial rigidity, and therefore a reserve capacity for withstanding hydrostatic pressure before appreciable diminution of the air cavity takes place.

If it is accepted that an air space is maintained in the middle ear cavity, it might be assumed that there would be a safe limit to the depth to which the cetacean can dive, after which fracture of the bulla would occur. The infrequency with which fractured bullae have been observed (Fraser & Purves 1953), suggests that there is a mechanism for overcoming this eventuality. As previously stated, Beauregard recognized the corpus cavernosus tympanicus as erectile tissue, but Bonninghaus and also the present authors have been unable to inject this body by manual pressure. It will be recalled that the lumen of the internal carotid in this body is extremely narrow and was thought by various anatomists to be degenerate. It is clear, however, that under the hydrostatic pressures available, the corpus could be erected by way of the internal carotid, in which eventuality it would occupy the tympanic cavity sufficiently to prevent fracture.

Unlike the lining of the air sacs, the tympanic cavity proper is lacking in the network of crypts and mucous ducts which are normally present in the lining of the air sacs, and mucous glands, if present at all, are poorly developed It seems highly probable that the foam in the sinuses is produced by secretions of the glands in association with the gaseous content of the air sinuses. In these circumstances, the air sinuses could be filled with foam leaving a foam-free cavity in the tympanic bulla. This foam-free cavity would diminish in volume with hydrostatic pressure and would, in extreme conditions, only occupy the vicinity of the auditory ossicles and fenestra rotunda. If the air sinus system reaches its limit of compressibility, there would be a pressure difference between the inside and the outside of the tympanic bulla because of the presence of the residual air cavities. It is suggested that this pressure difference is adjusted by the enlargement of the corpus cavernosum.

The question naturally arises as to how the contained nitrogen in the sinuses is prevented from passing directly into the blood stream in correlation with the increased pressure as the animal sounds. The first consideration is that this gas is not free to circulate in the air sinuses but is imprisoned in bubbles, the walls of which are composed of a mucus-oil dispersion. Bearing in mind the high solubility rate of nitrogen in fat, as compared with that in blood, and the very large total surface area of the oil constituent presented to the gas, (for instance 100 cc of oil reduced to particle size of 1μ would present a surface area of 1,200 sq.m.), it is reasonable to conclude that the nitrogen would be absorbed into the fat before becoming available for absorption into the blood. Conversely, with diminution of pressure, nitrogen would be liberated into the sinus system to augment the foam volume. This liberation of nitrogen would invariably be slower than the rate of decompression in a rapidly surfacing whale, so that there would be an accumulation of dissolved nitrogen in the foam. There is evidence that this nitrogen-charged foam is blown out at expiration (Fraser & Purves 1955).

It would seem that at all times during swimming and diving an equilibrium is maintained between (*a*) the hydrostatic pressure, (*b*) the rigidity of the tissues, (*c*) the turgor pressure of the blood vascular system, (*d*) the viscosity of the foam and (*e*) the volume of the gas as determined by the gas laws and by solution of the contained gas in the oil and mucus. The relative extent to which each factor operates to produce the equilibrium is beyond the scope of the present paper.

Acoustic Function of the Air Sacs

As previously stated, the air sinus system surrounds the periotic and occupies the space between that bone and adjacent cranial bones, and the periotic is itself separated osseously from the adjacent bones of the skull. With these factors operating it is necessary to discover the most effective sound path to the cochlea. The transmission or reflection of sound energy at the interface between two media depends upon the ratio of their acoustic resistances, and to some extent upon the frequency of the vibrations. Since the periotic is virtually surrounded by air space, the conditions are such that the interface can be regarded as being infinite in area as compared with the wave length, therefore the normal conditions of reflection of sound waves apply. According to Wood (1955) " Whenever the radiation resistances (of two media) are widely different there is almost complete reflection. The difficulty of transmitting sounds from water e.g. the noise of a ship's propeller in the sea, to the air-filled ear-cavity of an observer will be apparent." In fig. 30, from Wood, the graph shows the percentage energy of a sound wave reflected from a mass of bubbles in water. The percentage energy reflected is plotted as a function of the proportion of air to water. " This curve illustrates the serious reduction of intensity when a sound wave encounters a mass of air bubbles in the sea. The noise of a ship's propeller is seriously reduced by the bubbly water in the wake. In such cases the incident energy is partially reflected and partially absorbed, the loss increasing rapidly as the proportion of air to water increases." The graph refers to a layer of bubbly water of semi-infinite dimensions, but Rayleigh, according to Wood, has produced a formula for the reflection of plane waves from a layer of finite thickness :

$$\frac{\xi r}{\xi i} = r = \left(\frac{R_1}{R_2} - \frac{R_2}{R_1}\right) \Big/ \left\{4 \cot^2 \frac{2\pi l}{\lambda} + \left(\frac{R_1}{R_2} + \frac{R_2}{R_1}\right)^2\right\}^{\frac{1}{2}}$$

where r and i refer to the reflected and incident amplitudes, R_1 and R_2 ($= \rho_1 c_1$ and $\rho_2 c_2$) are the acoustic resistences of the medium (1) and the layer (2), l is the thickness, and λ the wave-length of the sound in the material of the layer. On the observed indication that the proportion of liquid to gas in the whale's ear foam is somewhere in the region of one to over a thousand, in the following calculation the proportion 1 to 10 can be accepted. As calculated from the following formula :

$$R_2 = \rho_2 c_2 = \sqrt{\frac{E_1 E_2 \{x\rho_1 + (1 - x)\rho_2\}}{xE_2 + (1 - x) E_1}}$$

where E_1 and E_2 refer to the elasticity of the two media $E_1 = 1{\cdot}2 \times 10^6$ and $E_2 = 2{\cdot}25 \times 10^{10}$; ρ_1 and ρ_2 the mean densities $= 0{\cdot}0012$ for air and 1 for water and

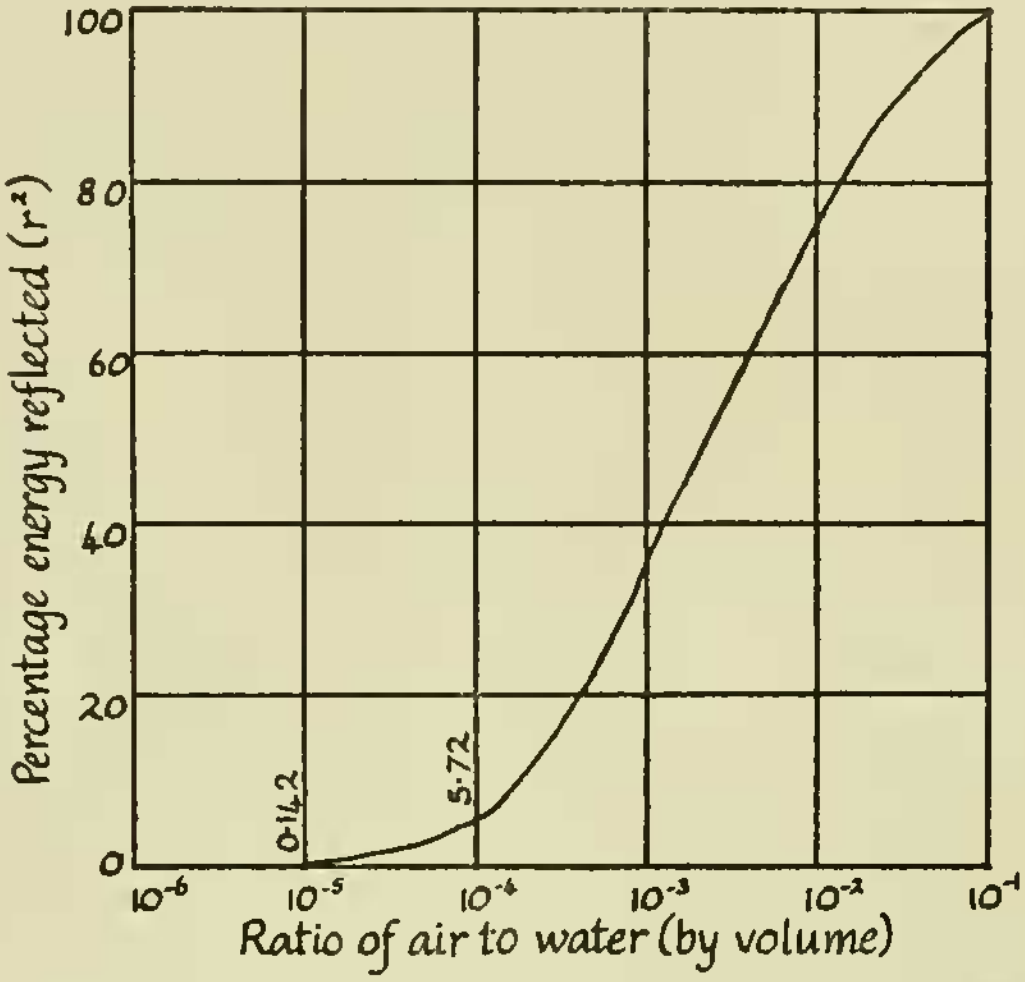

FIG. 30. Reflection of sound from air-water mixtures (after Wood, 1955).

x and $1-x$ refer to the proportions of the two constituents. The value for R_2 for a 1 in 10 mixture of water and air is then 348. If this figure is used in the first formula :

$R_1 = 1{\cdot}55 \times 10^5$ (for standard sea water)
$R_2 = 48$
$\lambda = 6{\cdot}8$ cm assuming a frequency of 50 kcs.
$l = 0{\cdot}5$ cm

the calculated result obtained is that 99·73% of the energy is reflected, that is assuming no loss through absorption. Since all sounds travelling in the direction of the cochlea by way of the bones of the skull and the soft tissues, with the exception of the meatus, must encounter the foam filled spaces, it is reasonable to assume that they must be almost completely reflected or absorbed.

Turning therefore to the meatus, in the Odontoceti it is open to the external surface of the tympanic ligament (which may be regarded as having the same acoustic resistance as the column of water filling the meatus) so that the first change of medium is that at the malleolar end of the ligament. The acoustic resistance of petrous bone must closely resemble that of ivory for which figures are available (Wood, 1955 p. 590). The velocity c_1 on a longitudinal bar is $2{\cdot}2 \times 10^5$ and the acoustic resistance $4{\cdot}1 \times 10^5$. The figure for the torsional velocity is not given but it may be assumed to be approximately a half the value for the longitudinal velocity. Employing the given figures for the acoustic resistance of water and ivory in the equation

$$r^2 = \left(\frac{\rho c_1 - \rho_2 c_2}{\rho c_1 + \rho_2 c_2}\right)^2$$

the result gives a figure of 45% reflection, but if the torsional velocity is used the figure will be 22% approximately. These figures refer to a bar of ivory of circular cross section, but the malleolar attachment to the tympanic ring is in the form of a channel girder with roughly half-tubular cross section, so that the rigidity coefficient, and hence the acoustic resistance, will be rather smaller than the figure quoted for ivory. Indeed it seems likely that the tympanic ligament transmits nearly all and reflects almost none of the incident energy. Assuming no slip at the incudo-malleolar joint, the molar vibrations of the malleus will be transmitted to the incus and thence to the stapes with very little loss of energy, since the incudal ligament is relatively minute in length and thickness. In the Mysticeti the inner part of the meatus is filled by the " ear plug " which consists of layers of cholesterol and keratinized epithelium (Purves 1955). It is an interesting fact that the acoustic resistance of paraffin wax is given as $1{\cdot}3 \times 10^5$ whereas that of sea water of 3·5% salinity is $1{\cdot}5 \times 10^5$ so that at the interface, the wax plug, if considered comparable, would form no appreciable barrier to sound waves.

It must be appreciated that the foregoing quantitative assessment is in the nature of an approximation, since all the formulae apply to simple, geometrical forms and not to a specialized, anatomical system adapted to a particular function. From these quantitative considerations, so far as sound reflection is concerned, there is no objection to accepting the meatus as the possible sound path.

Experimental Evidence of the Sound Conductivity of the Meatus

In order to test the relative suitability of the meatus from the absorption view point, a more precise experiment than that referred to in Fraser & Purves 1954, was carried out. A large portion of the squamo-mastoid region of a Fin Whale was obtained deep frozen and, when thawed, was dissected to expose the middle ear, the wax plug and meatus as far laterally as the blind portion. The blind portion was dissected to expose the cord connecting the inner part of the meatus with the external aperture. The output of a variable frequency oscillator was connected to a transducer by a concentric, screened cable. The transducer was in the form of a probe (see inset, Text-fig. 33), consisting of a steel cone cut transversely near its base for the insertion of a ceramic disc (barium titanate). A similar probe was connected to an amplifier and a cathode ray oscilloscope. The output of the oscillator was monitored by a rectifying voltmeter (see Text-fig. 32). A standard of reference was obtained by a calibrated deflection on the time base of the oscilloscope equivalent to 2 cm separation of the probes. The second probe was then moved in a mesial direction along the cord of the blind portion of the meatus and readings taken at 2 cm intervals (see Pl. 51). The readings consisted of increasing the volume ol the oscillator until the deflection on the oscilloscope reached the reference level. Similar readings were taken for the inner portion of the meatus, the wax plug, the tympanic ligament, wax plug to ligament and fibrous tissue parallel with the meatus. The attenuation in decibels is plotted against the distance in centimetres in Text-fig. 31. The values shown are much greater than the known attenuation of sound in sea-water (16 dbs per thousand yards at 100 kcs) but the probes were set in the tissue and moved along an axis which was at right angles to direction of propagation of the sound waves so that the attenuation rate was grossly exaggerated. The attenuation would be still further exaggerated by the presence of any gas bubbles produced by decomposition prior to freezing but the latter, if present, were assumed to have been uniformly distributed in the tissues.

The graphs show a general, comparative picture of the attenuation in the various tissues involved at three different frequencies. The lowest attenuation rate at 100 kc was obtained in the blind section of the meatus immediately internal to the blubber. (The external, open portion of the meatus was not tested as it was considered that it would be filled with water under natural conditions.) The figure for 2 cm of the corium of the lumen of the meatus was slightly below the reference for 2 cm of the blind section but the attenuation rate of the whole length of the corium was slightly higher than for the blind section, and was comparable with the rate of attenuation of wax plug—wax plug— tympanic ligament. The curve for the fibrous tissue was based on readings taken 4 cm posterior to the lumen of the meatus. The initial power factor required for 2 cm of this tissue was 12 decibels above reference and the attenuation considerably higher than that for the lumen of the meatus. The attenuation for the corium through a distance of 8 cm to the end of the tympanic ligament was roughly comparable with the figure for an equivalent distance of the blind section. The attenuation of a transmission from the tympanic ligament to the thin end of the bulla, the distance being about 3 cm (i.e. 1 cm above the reference distance) was about 13·5 dbs, or equivalent to ca. 8 cm of the blind section. The attenuation between the corium of the meatus, adjacent to the wax plug and the end of the tympanic ligament, a distance of approximately 8 cm, was ca. 16 dbs.

From these qualitative results it would appear that any vibrations transmitted by the meatus, blind section, lumen or wax plug would be received at the malleolar end of the ligament at an intensity greater than that of vibrations from the same source transmitted simultaneously by the surrounding fibrous tissue. Underlying bone transmissions, conveyed through tissues further away from the meatus, would suffer reflection at the bulla-tympanic cavity interface. Since the sound transmitted by the meatal path would be dominant at any level of intensity, the animal must be subject to an intensity and/or phase difference at the two cochleae, due to the screening effect of the head and distance apart of the two meatal openings.

The graphs B and C show that the attenuation is rather lower at the lower fre-

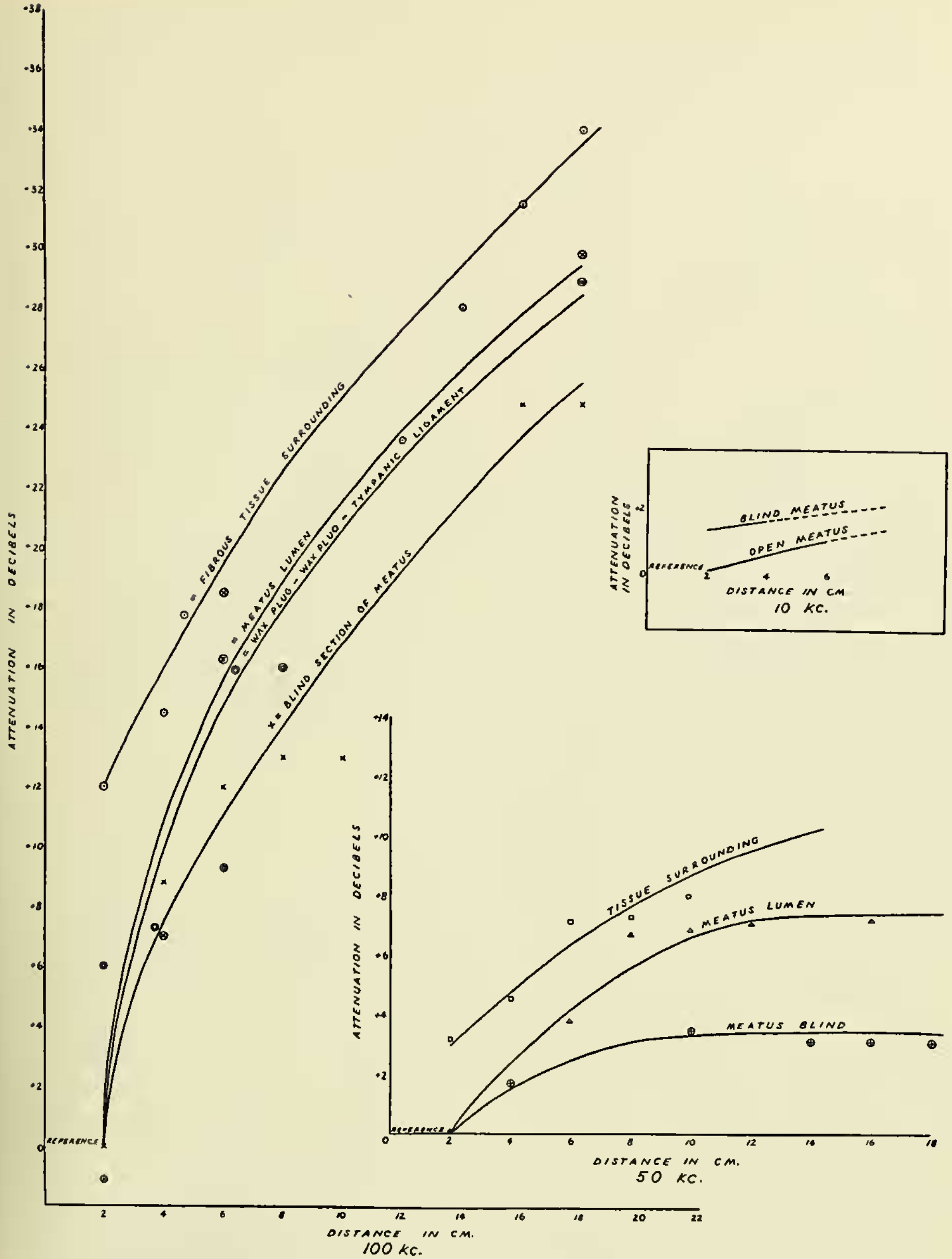

FIG. 31. Graph showing the attenuation of sound waves of 10–100 Kc in meatal and adjacent tissues of the ear of a Fin Whale.

quencies, a normal feature in sound vibrations. The reference level was adjusted to the reduced performance of the crystal at lower frequencies.

Similar tests to those just described were made on the external end of the external auditory meatus of a Sperm Whale. The results are compared with those obtained from the inner part of a Fin Whale meatus and are shown in Text-fig. 32.

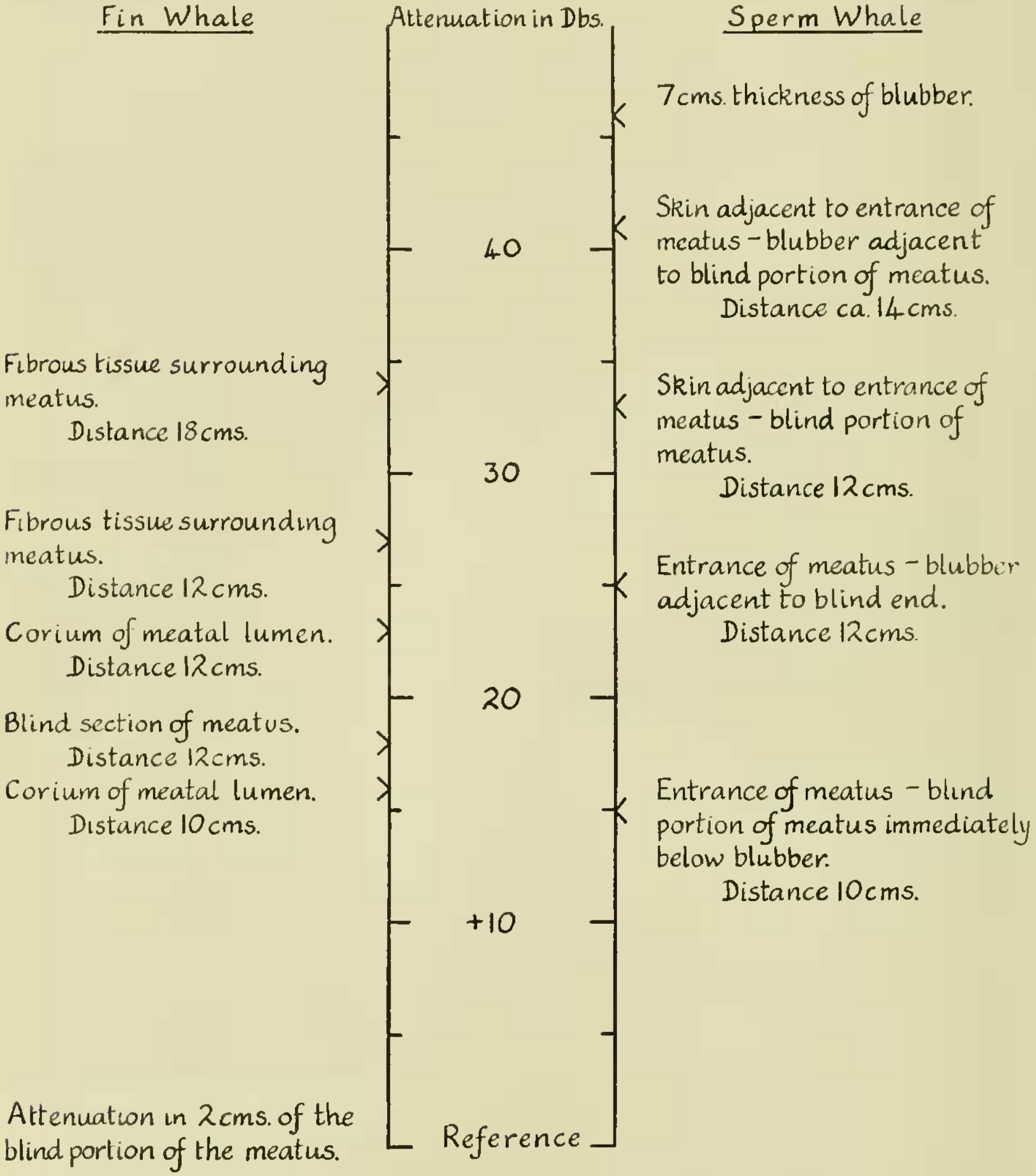

FIG. 32. Comparison of the sound conductivity of the external portions of the ear of a Sperm Whale with those of the inner portion of the meatus of a Fin Whale.

They indicate that the meatal lumen in both is similar in sound conductivity, and both are greatly superior to the adjacent blubber and fibrous tissue. It will be seen that 7 cm thickness of Sperm Whale blubber has a sound attenuation of 45 dbs above reference.

As previously described, the external surface of the tympanic bulla is encased in a closely adherent, fibro-elastic capsule some 10 cm. thick in a large whale. A slice of this tissue was tested for its sound conductivity. With 10 cm. of the tissue at 100 kc, the attenuation was approximately 8 dbs. above the reference, a figure some 5 dbs below that for 10 cm. of the blind section and approximately half that for 10 cm of the meatal lumen. This indicates that the acoustic impedance of the material of the capsule is high relative to that of the meatal tissue, and must have a highly damping effect on molar vibrations of the tympanic bulla, such vibrations being a characteristic of the function which some authors have assigned to this bone. It is submitted that one of the effects of the great weight and density of the tympano-periotic bones is the avoidance of forced oscillations of the bones within the frequency band of the animal's normal auditory range. It is clear, from the experiment described below, that the fused malleus is capable of undergoing high frequency oscillations up to 100 kc. It was found experimentally that these oscillations were transmitted to the thin involucral edge of the bulla, near the point of attachment of the malleus, but were subject to a power loss double that for an equivalent extent of meatal tissue. From this it would appear that vibrations transmitted from meatus to malleus would be greater in intensity than those transmitted from bulla to malleus. No signal could be obtained experimentally between malleus and periotic. It was proved experimentally that the malleus can undergo torsional vibrations independently of the bulla. Any molar, resonant vibrations of the latter would only vitiate the efficiency of the signal.

Experimental Evidence of Acoustic Matching

The question arises of the manner in which pressure amplitude is maintained and displacement amplitude increased. For the investigation of this problem, a thin steel wire was soldered to the end of one of the transducers, and the other end attached to the tip of the manubrium of the malleus at the normal point of attachment of the tympanic ligament, so that it simulated the latter in length and position (Text. fig. 33). The angle of attachment of the wire could be altered by raising or lowering the transducer, relative to the position of the manubrium, over a friction-free pulley, while the tension was kept constant by attaching a small weight to the cable connecting oscillator and transducer. The incus was allowed to rest on the malleus in its natural position, separated from the latter by a thin film of petroleum jelly. The stapes was simulated by the stylus of a micro-groove, crystal pick-up, which was connected to an amplifier and oscilloscope. The frequencies used in this experiment lay between 10 and 100 kc. A considerable difference was noted in the height of the deflection of the time base in relation to the angle which the wire made with the long axis of the manubrium mallei. When the wire was pulling at a sharp angle, approximately 5°, the deflection was about ten times the height attained when the wire was pulling at right angles to the manubrial axis. The only acceptable interpretation of this evidence is that the malleus was being thrown into torsional vibrations, and that the manubrium was behaving like a crank, actuated by the piston-like movements of the crystal face. When the wire was pulling at right angles to the manubrium, the relationship between the pressure-displacement amplitudes of the crystal face and the manubrium would be approximately unity ; whereas, when the wire was pulling at a sharp angle to the manubrium, the displacement ratio would be increased. Thus in the middle ear of the cetacean there exists a mechanism for the increase of displacement amplitude of water-borne sounds. It might be pointed out that this method of amplification is self-compensating, since the smaller the displacement amplitude of the sound wave the greater the relative amplification.

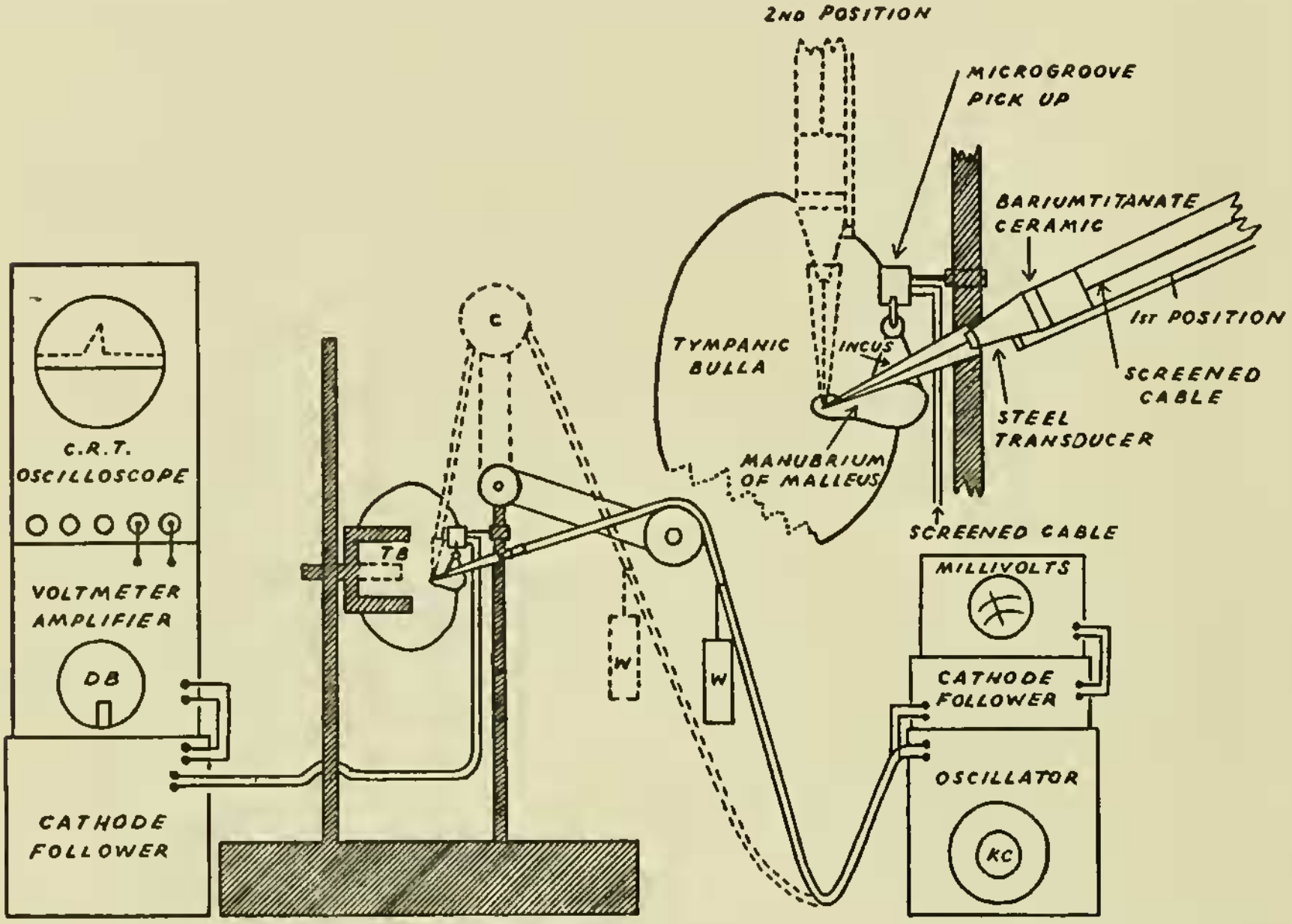

FIG. 33. Diagram of apparatus for demonstrating changes in the amplitude of torsional oscillations of the malleus when actuated by a simulated tympanic ligament vibrating longitudinally at various frequencies and angles of traction.

Text-fig. 34*a* shows the relationships of the tympanic membrane and auditory ossicles in a terrestrial animal such as man. Assuming the ratio of manubrium of the malleus to the long process of the incus as 2 : 1, then the displacement amplitude ratio between the tympanic membrane and the stapes is also 2 : 1. Text-fig. 34*b* shows the arrangement in the cetacean. The manubrium is shortened, so that its length is approximately that of the long process of the incus ; the tympanic membrane is closed up into a flat ligament which pulls at a sharp angle to the axis of the manubrium. In this case there is an amplification factor dependent upon the length of the manubrium and the angle of attachment of the ligament (Text-fig. 34*c*). Assuming this amplification factor to be 30 : 1, then the displacement amplitude at the stapes of a sound wave in water (of which the displacement amplitude for the same intensity and frequency is 1/60 that of the same sound air-borne) would be equal to that experienced by the terrestrial mammal.

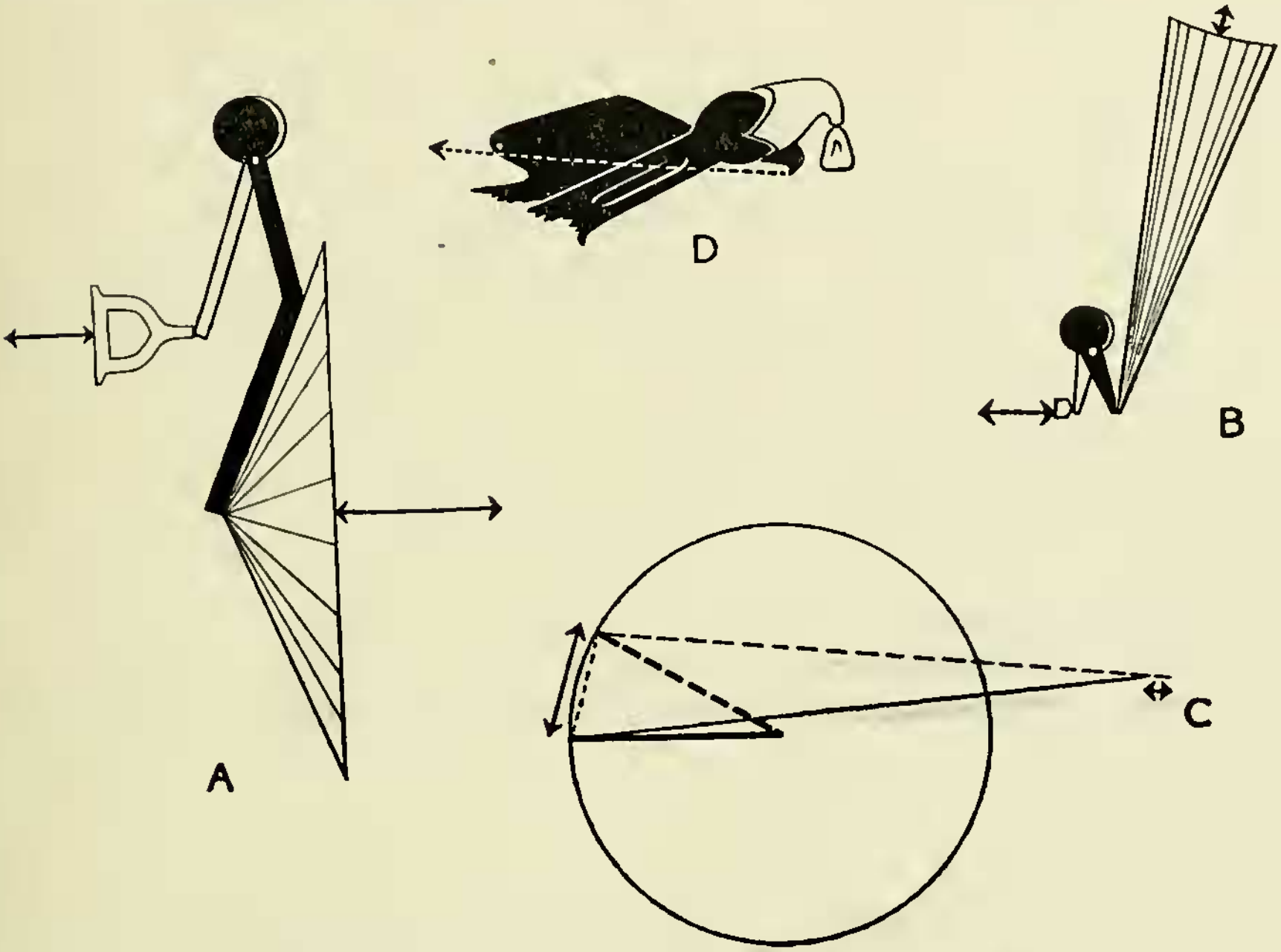

FIG. 34. Schematic representation of the ossicular mechanism.

a. Terrestrial mammal in antero-posterior view.

b. Cetacean ,, ,, ,, ,,

c. The mode of amplification of lateral displacement of the tympanic ligament by means of a crank system.

d. The buttressing function of the sigmoid process against lateral movement of the malleus, and the articulation of the latter with the incus.

In man, the pressure at the oval window of the inner ear is determined by the ratio between the area of the ear drum and that of the foot of the stirrup bone, as well as by the leverage of the auditory ossicles. The ratio is 30 : 1, the leverage approximately 2 : 1 giving a pressure ratio between the stapes and drum of about 60 : 1, which is approximately the same pressure amplitude ratio between a sound wave of the same intensity and frequency in water and air.

In order that the pressure amplitude at the cochlea in the cetacean be the same as that in terrestrial mammals, some compensation has to be made for the reduction in pressure due (*a*), to the 30 : 1 displacement amplification factor described above, and (*b*), to the reduction in area of the tympanic membrane resulting from its modification from the membranous, drum-like structure of terrestrial mammals into the ligament of the cetacean. It is submitted that the compensation is achieved by the reduction in the cross-sectional area of the stapes, so that the ligament-stapedial area relationship remains approximately 30 : 1 as in terrestrial mammals. Inspection of dissected specimens indicates that the ratio in the cetacean is of that order (see Pls. 49, 50 and 53).

For the same intensity and frequency, the pressure amplitude of water-borne sounds is 60 times greater than in air. Accepting the ligament-stapedial area ratio as 30 : 1, and the reduction in pressure due to the leverage at the manubrium as 1 : 30, then the pressure of a water-borne sound at the cochlea is also 60 times greater than a sound of the same intensity and frequency in air. This is the calculated pressure increase experienced in man. In the experiment described on p. 128 the minimum angle of attachment of the wire to the manubrium mallei was about 5°. In order to obtain the amplification factor required in the cetacean ear the angle would require to be approximately 2°. It can be seen from Pls. 49, 50 and 53 that the angle is of that order.

Since the pressure amplitude of sound presented at the fenestra ovalis of terrestrial animals is the same as that received at the inner ear of aquatic lower vertebrates, the evolution of the cochlea would seem to be linked with the increased displacement amplitude of air-borne sounds.

Discrimination and Directionality

Text-fig. 34*d* shows schematically the attachment of the processus gracilis of the malleus to the sigmoid process of the bulla and the articulation of the malleus with the incus. It will be noted that the processus gracilis is of a channel-girder construction; its attachment to the sigmoid process is of extremely thin bone. The arrow indicates the direction of the long axis of the tympanic ligament. Traction or pressure along the line of this axis would result in rotation of the head of the malleus about the long axis of the processus gracilis, since lateral movement is prevented by the buttressing effect of the sigmoid process. The rotation imparts a 'screw-driver' movement to the incus which in turn rotates about its forwardly projecting, short process (not shown in figure). That is to say, it is exactly the same as in terrestrial mammals. If, in spite of the buttressing effect of the sigmoid process, the malleus were to undergo lateral movement, the articular facets of malleus and incus would simply slide over one another without imparting any movement to the incus. If oscillatory movements in either of the directions at right angles to the axis of the ligament are assumed, then positive movement of the incus is possible in the first phase of the first oscillation only. In the second phase the bones would be partially disarticulated, so that the movement of the malleus would be expended in taking up the gap between the facets. It will be recalled that the short process of the incus is attached by a ligament to the periotic, so that vibrations of the bulla (to which the malleus is attached), resulting in movements of the malleus in any of the directions other than the rotational one, would not be transmitted to the incus. This has been proved experimentally by subjecting a large working model of the auditory ossicles and their attachments to the types of vibration described above. The unique effectiveness of the rotational movement of the malleus is one of the fundamental reasons why theories involving vibrations of the tympanic bulla (e.g. the resonance theories of Lillie & Kellogg and the seismic theory of Yamada) are not accepted by the present writers, who believe that the comparable articulation in man and other mammals serves the same function of preventing resonant vibrations of the bulla and/or adjacent bones from reaching the cochlea. Transmission to the cochlea of vibrations of the bones of the skull or the bulla, and of all parts with the exception of the tympanic membrane, would be accompanied by loss of directionality of hearing.

The conditions of sound transmission in water are such that cetaceans must normally be subjected to noise intensity levels quite outside the experience of terrestrial mammals, and yet the construction of the cochlea is such that the ear must be sensitive to the same threshold levels as those experienced by land mammals. For example, Fletcher & Wegel according to Wood (1955) have found that at a frequency of 2000–2500 p.p.s. the human ear can respond to a pressure amplitude of the order of 10^{-3} dyne/cm^2 or 10^{-9} of an atmosphere. He states that in air this corresponds to a displacement amplitude of 10^{-9} cm which is about 1/30 of the diameter of a molecule of oxygen, or 10^{-4} of the mean free path of the molecules in air at N.T.P.

In view of the high noise intensity in water and the great sensitivity of the cochlea, it is not surprising that the cetacean meatus is of very small calibre. It is almost certain that a mechanism exists to protect cetaceans against the harm that excessive noise can cause.

Most mammals are provided with muscles for closing the meatus, and even in man the vestiges of these remain and may be stimulated by electrical current (Beattie 1932). In the Cetacea, although the pinna has disappeared, its cartilages and muscles are to a greater or lesser degree present beneath the blubber. The m. occipito-auricularis profundus and the m. zygomatico-auricularis described and figured by Boenninghaus in *Phocaena* (Pl. 1, D) seem suitably placed to control the tension and aperture of the external meatus in the Odontoceti. In the Mysticeti, Denker (1902) described a number of muscles attached to the blind portion of the meatus which presumably have the function of increasing or relaxing the tension of this part of the tube (see also p. 135).

It is concluded that the meatus is the most favourable sound path as in terrestrial mammals, and, as in the latter, the same conditions for directional hearing obtain, which are—the degree of separation of the ears, the screening effect of the head and the association that these have with phase and intensity differences. In terrestrial mammals such phase and intensity differences can quickly be assessed by the animal, even when in motion, by adjustments in the orientation of the ears and head. The Cetacea, lacking external ear pinnae and the degree of freedom of orientation of the head which a well-defined neck gives, might be expected to have some kind of compensating facility. Essentially, directionality is obtained by equating the sound intensity at the two cochleae. It was found experimentally that the sound conductivity of the cetacean meatus could be increased or decreased by varying its tension. It is suggested that this equation of pressure at the cochlea is achieved by the traction of the auricular muscles on the meatal tube. The great development of the pterygoid muscles, despite the reduced lateral mobility of the lower jaw, and the mode of attachment of these and the tensor palati muscles into the walls of the air sacs, seem to suggest that they have a second function related to the air sac system. As already suggested (Fraser & Purves, 1953), the arrangements which exist in terrestrial mammals for making small, temporary adjustments to the tension of the tympanic membrane are also present in the Cetacea but, due to the large adjustments required for the rapid changes of pressure with changes of depth, it is doubtful if the tensor tympani muscle is as effective in this respect as it is in terrestrial mammals. It is suggested that this function might well be performed by the palatal and pterygoid muscles. It is interesting to note that when humans are subjected to abnormal pressures, whether in diving or in aircraft, adjustment of the pressure in the middle ear is obtained by swallowing, in which both pterygoid and palatal muscles are brought into operation. The general arrangement of the air sac system could also be of value in direction finding.

THEORIES OF CETACEAN HEARING

Dr. Yamada's contribution to the *Anatomy of the Organ of Hearing in Whales* (1953) was received while the present paper was in preparation. Among other conclusions reached by him are that the external meatus is vestigeal, that the auditory bones are not acoustically isolated, and that the tympano-periotic bone is " a dynamic unit of seismographic principle ".

Yamada's conclusion that the external meatus is vestigeal is based on the unjustifiable assumption that it is unable to transmit sound vibrations. He assumes that the sound waves to be transmitted have the same physical properties as those received by terrestrial mammals. In all specimens examined by him he has found a continuous cord of tissue from the external to the internal portion of the meatus, and it has been proved experimentally by the present writers that this path is an efficient conductor of longitudinal vibrations. This was also proved for the tympanic ligament, contrary to Yamada's conclusions (p. 46). In order to justify the refutation of the acoustic isolation theory he cites the case of *Platanista* in which, according to Hyrtl, the tympano-periotic is fused to adjacent skull bones. As previously pointed out (p. 43) all the specimens of *Platanista gangetica* available for examination in connection with the present paper had tympano-periotic bones which were not thus fused, in this agreeing with other cetaceans. Yamada also points to the strong, fibrous connection of the periotic in *Balaenoptera physalus* which passes through a canal bordered by the pterygoid and squamosal bones. The feature referred to in his fig. 18, p. 44 is the foramen ovale and the course he describes for the ligament to lower jaw is that followed by the mandibular branch of the 5th nerve. He states that the fibrous connections negative the idea of acoustic isolation, but it may be pointed out that the only fibrous connections are those derived from the periosteum of resorbed bones of the tympano-periotic hiatus. This periosteum sheathes the periotic and thus is very unfavourably situated for the transmission of vibrations to the petrous bone. The acoustic resistance of the two substances are such that on theoretical grounds about 50% of the incident energy would be reflected, assuming the most favourable conditions of vibrations normal to the surface of the bone.

With regard to Boenninghaus' Schalltrichter theory, it has already been stated by Fraser & Purves (1955) that sound waves could not be transmitted to the funnel of the bulla by way of the air in the pterygoid sinuses because of the presence of the albuminous foam in the sinuses. Considering the possibility of transmission of vibrations from the lateral wall of the sinuses through the mucous membrane of the tympanic funnel to the tympanic ligament, sound waves emanating from a source lateral to the body of the animal would have to pass through the thickness of blubber, muscles, mandible, intra-mandibular fatty tissue, vascular networks and subsequently be transmitted in a direction at right angles to that of the original direction. This would involve shearing stresses on the mucous membrane which are much more easily damped out than longitudinal ones. When there exists a simple, direct sound path, from the external meatus to the tympanic membrane, of a homogeneous histological structure, and of which the ligament is a prolongation, it is difficult to accept an explanation which involves an extremely tortuous path with powerful acoustical barriers.

The adaptation of the sound path normal to terrestrial mammals is, on the face of it, more acceptable than any *de novo* method of sound conduction in mammals.

With reference to Yamada's criticism of Boenninghaus' Schalltrichter Theory, while not accepting the latter, it is possible to reply to Yamada's unanswered question "How can the vibration of the malleus alone be undamped in spite of its rigid connection with the bulla?" The functioning of the malleus is stated in Fraser & Purves (1954) p. 110, where it is also shown that vibrations of the bulla cannot be transmitted beyond the malleus.

Yamada summarizes his seismographic explanation by stating that the heavy involucrum (of the tympanic bulla) is the weight of a pendulum, in relation to which the malleus is motionless, so that vibrations of the involcrum are conveyed to the essential organ of hearing. Essentially this idea differs little from that of Kellogg (1938) or from the original explanation of Lillie (1915). The objections to it are that (*a*) if the bulla did act like a pendulum and undergo total vibrations, the axis of rotation would be through the two thin, supporting pedicles mentioned by Kellogg. It has been shown (Fraser & Purves, 1953) that the articulation between the malleus and incus is specifically arranged to avoid such vibrations, being transmitted beyond the junction of the malleus and incus; (*b*) it is well known that all pendulums oscillate at a fixed frequency depending on the length of the lever. It is difficult to understand how a heavy pendulum of the magnitude of the bulla could (with the limit of power available in a sound transmitted in water) be forced to vibrate at a frequency of 100,000 cycles per second a frequency to which at least one kind of cetacean (Schevill & Lawrence, 1953) is known to be sensitive.

In another paper (Schevill & Lawrence, 1953), received while the present work was in preparation, it was noted that in the authors' hearing experiments on *Tursiops truncatus* there was a marked drop in positive response at 120 kc and final lack of response to frequencies above 130 kc per sec. These authors assumed that the mode of hearing in their experimental animal was by bone conduction, yet they themselves mentioned the fact that there is no evidence of an upper frequency limit to bone conducted sound in man ; the highest pitch that is normally audible continues to be heard even when the subject is exposed to much higher frequencies. They quote Kunze & Kietz (1849) as having published curves reaching 128 kc for man without any sign of a break in the upper end of the curve. They consider, in the light of the bone conduction evidence when man is the subject, that there should be no upper limit to hearing in cetaceans, but their experimental findings provide sufficient evidence to suggest that bone conduction is not involved. It has previously been pointed out that it would be very undesirable to have this mode of hearing from the point of view of its lack of directionality.

In a recently published, very comprehensive work on hearing in whales, Reysenbach de Haan (1957) has shown by experimental and quantitative treatment of the anatomical data that the conclusions reached by the writers (Fraser & Purves, 1955) are in almost every respect in agreement with his own. He does not however concur with the hypothesis that the sound is conducted to the middle ear by the external auditory meatus. His work was received some time after the completion of this paper, and because of the disagreement referred to above it will be necessary to supplement the observations on the external meatus already referred to (pp. 108–112 *supra*) by additional evidence obtained from a gross dissection of the ear of a Fin Whale.

Before proceeding with this account, it is necessary to refer to a disparity between the present writers' and Reysenbach de Haan's interpretation of the Schalltrichter Theorie of Boenninghaus. It is evident from Reysenbach de Haan's conclusions that he regards " schalltrichter " as being synonymous with " tympanic annulus " but this is not so. Quoting from Boenninghaus " the whole processus anterioris of the tympano-periotic is in the shape of a funnel the anterior diameter of which is about 1 cm . . . also quite remarkable is the anteriorly concave hearing wall and the sigmoid process which bounds the funnel from behind ". It will be seen from this that the entrance to the funnel or " shell " as he subsequently calls it lies at the anterior end and not lateral to the tympanic bulla.

In addition, the tympanic annulus of *Delphinus* is never as large as 1 cm in diameter and the sigmoid process lies anterior to, and is not " behind ", the annulus. Boenninghaus goes on " the funnel has through the aforesaid turning of the tympanic bulla been turned forward so that sound waves from the rear do not strike it. . . . The bony sound funnel is now to be regarded as the functioning substitute of the pinna and auricular passage of land mammals ". Boenninghaus' sound path is stated as follows—" Sound waves from the side and front pass through skin, fat, tongue and jaw bone musculature—through the anterior opening of the bulla to the anterior process of the malleus thence through the immovable incus and stapes to the fenestra ovalis ."

Pl. 51 shows a dissection of the auditory apparatus of a 60-ft Fin Whale caught near Steinshamn, Norway, 1956. It will be noticed that the whole external meatus is stretched tightly and lies on an approximately straight, horizontal axis from the middle ear to the external aperture. The feature is not an artifact of preservation but was found to be the condition in all the freshly killed whales examined at Steinshamn. The attenuated, distal, closed end of the meatus passes through a conspicuous auricular cartilage to which are attached five robust, auricular muscles none of which is less than 5 cm in diameter. Dorsal to these muscles is an extensive retial mass of blood vessels which probably indicates that the muscles are functional. The proximal portion of the meatus, the corium of which contains the ear-plug, lies in a deep groove between the exoccipital and squamosal bones and in life was surrounded by loose connective tissue and oil sinuses. Enveloping the whole of this area, and adhering to the bones, there was in life, a great mass of dense, white, fibrous tissue about 30 cm in thickness and with tough unyielding fibres forming a close reticulum throughout the entire mass. The meatus was thus enclosed in a tunnel formed dorsally by bone and ventrally by the white fibrous tissue. In these circumstances any contraction of the auricular muscles would result in considerable stretching of the meatal wall and of its closed, distal extremity.

Turning now to the proximal end of the meatus, the same dissection, Pl. 52, shows that the ear-plug, which fills the lumen of the meatus, is closely applied to the external surface of the " glove finger ". In the dissection the plug has been bisected to show the " annual rings " but in life it would completely envelop the " glove-finger ". Owing to decomposition, the ear-plug has become detached from the stratum germinativum, but in life it forms the zona cornea of the " glove-finger " and meatal epidermis and is consequently very firmly attached to the latter structures. Pl. 53 shows the middle ear after removal of part of the bulla and periotic. Originating on the mesial aspect of the internal face of the bulla anterior to the tympanic annulus, there is a short, stout muscle the insertion of which merges into the fibrous matrix of the internal wall of the glove finger opposite the tympanic ligament. Contraction of this muscle would result in movement of the whole of the " glove-finger ", and of the ear-plug assembly, as far as the lateral, blind end of the meatus. In this respect the auricular muscles and the small muscle referred to above would act antagonistically. Mobility of the external meatus implied in the anatomical arrangement would be superfluous if the meatus were non-functional.

In terrestrial mammals the special senses, of hearing, scent and sight are all available for the perception of the animal's environment. In the Toothed Whales the olfactory sense is wanting, and in the Baleen Whales, if present at all, it is very greatly reduced. However efficient the eyes may be, their function must be limited by conditions of turbidity of the water and by depth. Some River Dolphins may be totally blind. In all cetaceans the sense of hearing is the most important of the special senses.

CONCLUSIONS

It is concluded from the examination of specimens, from the evidence of existing literature and from the results of experiments that:

(1) the configuration of the ventral aspect of the cetacean skull, which is associated

with the development of air spaces, provides a fairly reliable guide to the systematic arrangement of the Order Cetacea.

(2) The Mysticeti as a whole are more primitive than the Odontoceti.

(3) In the Odontoceti there is a gradation of development and specialization of the sinus system within the sub-order as a whole, from the relatively primitive River Dolphins through the estuarine forms to those which are pelagic. There are distinct series of gradations within the sub-divisions of the hierarchy, intra-generic as in the species of *Lagenorhynchus*; within the sub-family, as in the genera included in the Delphininae; within the family, as in sub-families included in the Delphinidae; and within the super-family, as in the families represented in the Delphinoidea.

(4) The systematic arrangement of the order in the present paper fits basically into the framework of Simpson's (1945) classification, but has been extended in detail.

(5) A notable exception is in the elevation of the Monodontinae to super-family rank.

(6) The elaborate sinus system of the Cetacea consists almost entirely of an extension of the middle ear cavity into the lamina of the pterygoid bone involving invagination, distension and extension of the latter.

(7) The peribullary sinus is derived from the invasion of the basioccipital crest and squamosal bone by the tympanic cavity after dissociation of the tympano-periotic from the adjacent cranial bones.

(8) Hearing is by way of the external auditory meatus as in terrestrial mammals.

(9) Hearing is precisely discriminative and directional, and the ear is sensitive to a wide range of frequencies.

(10) The qualities of hearing referred to have been achieved by modification of typically mammalian auditory structures; so far from being non-functional, the meatus, the tympanic membrane, the auditory ossicles, tympanic bulla, the cochlea, the tympanic cavity and sinus system are all perfectly adapted for underwater hearing.

ACKNOWLEDGMENTS

Grateful acknowledgments are made to the following for the use of apparatus and for technical advice: Professor A. J. E. Cave, Mr. R. W. Fraser, Mr. G. R. M. Garratt, Mr. M. G. Holloway, Dr. T. C. S. Morrison-Scott, Professor D. M. Newitt, F.R.S., Dr. H. W. Parker and Mr. C. Urwin. The writers are particularly indebted to Mr. C. Cropper and his colleagues for their generous and enthusiastic help. They wish also to acknowledge the great help in the translation of papers given to them by Commander J. M. Chaplin, R.N. (Rtd.).

KEY

A —Artery.
AAS —Accessory air sinus.
AC —Auricular cartilage.
ACE —External carotid artery.
ACI —Internal carotid artery.
AL —Lachrymal artery.
ALS —Alisphenoid bone.
ALS(LL)—Lateral lamina of alisphenoid.
ALT —Anterior ligament.
AM —Mandibular artery.
AMI —Internal maxillary artery.
AO —Orbital artery.
AOF —Antorbital foramen.
AP —Anterior pedicle.
APPB —Palato-pharyngeal branch of internal maxillary artery.
APT —Pterygoid artery.
APTMB —Arterial branches to internal pterygoid muscle.
AS —Anterior sinus.
AT —Temporal artery (deep).

B —Bone.
BC —Calcified element of bone.
BL —Blubber.
BO —Basioccipital bone
BOC —Basioccipital crest.
BR —Resorbed element of bone.
BS —Basisphenoid bone.

C —Cochlea.
CAP —Capillary.
CC —Corpus cavernosum.
CF —Fat cells.
CRH —Cranial hiatus.

DMU —Mucous duct.

EAM —External auditory meatus.
ECI —Ciliated epithelium.
ECO —Columnar epithelium.
EP —Ear-plug.
ET —Eustachian tube.
EXO —Exoccipital bone.

FEO —Fenestra ovalis.
FER —Fenestra rotunda.
FG —Fat globules.
FO —Foramen ovale.
FOI —Infundibulum of foramen ovale.
FP —Falciform process.
FR —Frontal bone.
FR(OR) —Orbital process of frontal bone.
FR(PO) —Post-orbital process of frontal bone.
FR(PR) —Pre-orbital process of frontal bone.
FT —Fatty tissue.
FVP —Fibro-venous plexus.

GL —Glove-finger.
GMU —Mucous gland.
GOC —Goblet cell.

I —Incus.
ILS —Interlaminar space.
IMFB —Intra-mandibular fatty body.

JU —Jugal bone.

LA —Lachrymal bone.
LI —Ligamentum incudis.
LS —Lymph space.

M —Muscle.
MA —Malleus.
MAS —Mastoid process.
MD —Mandible.
MEP —External pterygoid muscle.
MFS —Striped muscle fibres.
MIP —Internal pterygoid muscle.
MLO —Longitudinalis oesophagi muscle.
MLP —Levator palati muscle.
MM —Masseter muscle.
MO —Orbital muscle.
MOO —Orbicularis-oris muscle.
MPP —Palato-pharyngeus muscle.
MPP(E) —Palato-pharyngeus muscle (pars externa).
MPP(I) —Palato-pharyngeus muscle (pars interna).
MPP(S) —Palato-pharyngeus sphincter.
MS —Middle sinus.
MSC —Superior constrictor muscle.
MSP —Salpingo-pharyngeus muscle.
MT —Temporal muscle.
MTHP —Thyro-palatinus muscle.
MTP —Tensor palati muscle.
MUM —Mucous membrane.
MX —Maxilla.
MAX —Maxilla (figs. 15–21).
MXC —Maxillary crest.
NA —Auditory nerve.

NM —Mandibular branch of trigeminal nerve.
NO —Optic nerve.
OC —Occipital condyle.
OF —Optic foramen.
OI —Optic infundibulum.
OS —Orbitosphenoid bone.

P —Periosteum.
PA —Palatine aponeurosis.
PAL —Palatine bone.
PAL(LL)—Lateral lamina of palatine bone.
PAO —Paroccipital process.
PAR —Parietal bone.
PBS —Peribullary sinus.
PE —Periotic.
PG —Processus gracilis.
POS —Posterior sinus.
PP —Posterior pedicle.
PRS —Presphenoid bone.
PS —Periosteal sheet.
PT —Pterygoid bone.
PTF —Pterygoid fossa.
PTH —Pterygoid hamulus.
PT(IL) —Inferior lamina of pterygoid bone.
PT(LL) —Lateral lamina of pterygoid bone.
PT(ML) —Mesial lamina of pterygoid bone.
PTS —Pterygoid sinus.
PTS(PO)—Post-orbital lobe of pterygoid sinus.
PTS(PR)—Pre-orbital lobe of pterygoid sinus.
PI(SL) —Superior lamina of pterygoid bone.

S —Air sinus.

SB —Secondary bone.
SC —Semicircular canal.
SM —Stapedial muscle.
SO —Supraoccipital bone.
SP —Sigmoid process.
SQ —Squamosal bone.
SQZ —Zygomatic process of squamosal.
ST —Stapes.

TA —Tympanic annulus.
TB —Tympanic bulla.
TB(PA) —Posterior aperture of tympanic bulla.
TC —Tympanic cavity.
TF —Fibrous tissue.
TL —Tympanic ligament.
TM —Tympanic membrane.
TP —Tympano-periotic bones.
TSQR —Tympano-squamosal recess.
TT —Tensor tympani muscle.

V —Vomer.
VIJ —Internal jugular vein.
VIM —Internal maxillary vein.
VM —Mandibular vein.
VN —Vein.
VP —Venous plexus.
VPT —Pterygoid vein.
VTEP —Ventral tendon of external pterygoid muscle.

ZA —Zygomatic arch.

BIBLIOGRAPHY

Anderson, J. 1879. *Zoological Results of the two Expeditions to Western Yunnan* 1868–75. First volume. London. Quaritch.

Anthony, R. & Coupin, F. 1930. Recherches anatomiques sur le Vestibule de l'appareil respiratoire (Poche gutturale-Hyoide-Larynx) du *Mesoplodon*. *Mem. Inst. Esp. Oceanogr. Madrid Mem.* **14** : 1–40, 2 pls., 22 figs.

Beattie, R. T. 1932. *Hearing in Man and Animals*. xi, 227 figs. London.

Beauregard, H. 1894. Recherches sur l'appareil autitif chez les Mammifères. *J. Anat. Paris* **1894** : 367–413, 3 pls.

Boas, J. E. V. 1912. *Ohrknorpel und äusseres Ohr der Säugetiere*. 1–225, 25 pls., 21 figs. Copenhagen.

Boenninghaus, G. 1902. Der Rachen von *Phocaena communis* Less. Eine biologische studie. *Zool. Jahrb.* **17** : 1–92, 1 pl.

—— 1903. Das Ohr des Zahnwales, zugleich ein Beitrag zur Theorie der Schalleitung. *Ibid.* **19** : 189–360, 28 fifs., 3 pls.

Buchanan, T. 1828. *Physiological Illustrations of the Organ of Hearing*. London.

Camper, P. 1777. Verhandeling over de Zitplaats van det Beenig Gehoorting . . . in de Walvischen. *Verh. Holland. Maatsch.* **17** : Pt. 2, 157–200, 2 Pls.

Carte, E. & Macalister, A. 1868. On the Anatomy of *Balaenoptera rostrata*. *Phil. Trans.* **158** : 210–261, 5 pls.

Clarke, R. H. 1948. Hearing in Cetacea. *Nature, London*, **161** : 979–980.

Denker, A. 1902. Zur Anatomie des Gehörorgans der Cetacea. *Anat. Hefte.* **19** : 424–448, 2 pls., 6 figs.

Flower, W. H. 1867. Description of the skeleton of *Inia geoffrensis* and the skull of *Pontoporia blainvilli* with remarks on the systematic position of these animals in the Order Cetacea. *Trans. Zool. Soc.* **6** : 87–116, 4 pls.

—— 1868. On the Osteology of the Cachalot or Sperm Whale *Physeter macrocephalus*. *Ibid.* **6** : 309–372, 7 pls., 13 figs.

Fraser, F. C. 1956. A new Sarawak Dolphin. *Sarawak Mus. Journ.* **7** : N.S. No. 8, 478–503, 5 pls., 2 figs.

Fraser, F. C. & Purves, P. E. 1953. Fractured Earbones of Blue Whales. *Scott. Nat.* **65** : No. 3, 154–156, 1 pl.

—— —— 1954. Hearing in Cetaceans. *Bull. Brit. Mus.* (*N.H.*), **2** : No. 5, 103–116, 2 pl.

—— —— 1955. The 'Blow' of Whales. *Nature*, **176** : 1221–1222.

Hanke, H. 1914. Ein Beitrag zur Kenntnis der Anatomie des äusseren und mittleren ohres der Bartenwale. *Jenaische Zs. Natw.* **51** : (1914), 487–524, 3 pls.

Home, E. 1812. An account of some Pecularities in the Structure of the Organ of Hearing in *Balaena mysticetus* of Linnaeus. *Phil. Trans.* **102** : 83–88, 2 pls.

Howell, A. B. 1930. *Aquatic Mammals : their adaptation to Life in the Water.* pp. vii : 338. Springfield, Illinois.

Hunter, J. 1787. Observations on the Structure and Oeconomy of Whales. *Phil. Trans.* **77** : 371–450, 8 pls.

Hyrtl, J. 1845. *Vergleichend-Anatomische untersuchungen über das Innere Gehörorgan des Menschen und des Säugethiere* viii, 139, 9 pls. Prag.

Johnston, T. B. & Whillis, J. (Editors). 1946. *Gray's Anatomy* 29th ed. 1–1,597 figs. London.

Kellogg, R. 1398. Adaptation of Structure to Function in Whales. *Publ. Carneg. Instw.*, **501** : 649–682.

Kernan, J. D. 1916 [In Schulte H. von W.] Anatomy of a foetus of *Balaenoptera borealis*. *Mem. Amer. Mus. Nat. Hist.* n.s. **1** : Part IV, 389–502, 15 pls.

Knox, R. 1859. Contributions to the Anatomy and Natural History of the Cetacea. *Journ. Linn. Soc. London* [1857], **3** : 63–76.

Kolmer, W. 1907. Über das häutige Labyrinth des Delphins. *Anat. Anz.* **32** : 295–300, 3 figs.

Kunze, W. & Kietz, H. 1949. Ueber Horempfindungen im Ultraschallgebiet bei Knochenleitung. *Archiv. f. Ohren. Nasen, Kehlkopfheikunde*, **155** : 683–692.

Lillie, D. G. 1910. Observations on the anatomy and general biology of some members of the larger Cetacea. *Proc. Zool. Soc.* **1910** : 769–792, 1 pl. 10 figs.

—— 1915. Cetacea. Brit. Antarctic " Terra Nova " Expedition 1910. *Nat. Hist. Report. Zool.* **1** : No. 3 ; 85–124, 8 pls, 14 figs.

Monro, A. 1785. *The Structure and Physiology of Fishes.* 1–128. 44 pls. Edinburgh.

Murie, J. 1873. On the Organization of the Caa'ing Whale, *Globicephalus melas*. *Trans. Zool. Soc.*, **8** : 235–301, 9 pls.

Purves, P. E. 1955. The Wax Plug in the external auditory meatus of the Mysticeti. *Discovery Reports*, **27** : 293–302, 5 pls., 1 fig.

Rapp, W. 1837. *Die Cetaceen zoologisch-anatomisch dargestellt.* VI, 182, 8 pls. Stuttgart and Tübingen.

Ridewood, W. G. 1922. Observations on the skull in foetal specimens of Whales of the genera *Megaptera* and *Balaenoptera*. *Phil. Trans.* ser. *B.* **211** : 209–272, 16 figs.

Rondelet, G. 1554. *Libri de Piscibus marinis, in quibus verae Piscium effigies expressae sunt.* Lugduni.

REYSENBACH DE HAAN, F. W. 1957. Hearing in Whales. *Acta oto-Laryngologica*: Supplementum 134, 1–114, 41 figs. Stockholm.

SCHEVILL, W. E. & LAWRENCE, B. 1953*a*. Auditory Response of a Bottlenosed Porpoise, *Tursiops truncatus*, to frequencies above 100 Kc. *Journ. Exp. Zool.* **124**: No. 1, 147–165, 2 figs.

—— —— 1953*b*. High frequency auditory response of a bottle-nosed porpoise, *Tursiops truncatus* (Montagu). *Journ Acoust. Soc. America*, **25**: 1016–1017.

SCHEVILL, W. E. & LAWRENCE, B. 1956. Food-finding by a captive Porpoise (*Tursiops truncatus*). *Breviora*, No. 52, 1–15.

SCHOLANDER, P. F. 1940. *Experimental Investigations on the Respiratory Function in Diving Mammals and Birds.* Hval. Skrift. No. 22: 1–131, 88 figs.

SIMPSON, G. L. 1945. The Principles of Classification and a Classification of Mammals. *Bull. Amer. Mus. Nat. Hist*, **85**: i–xvi, 1–114.

SLIJPER, E. J. 1936. *Die Cetaceen—Vergleichend-Anatomisch und Systematisch.* i–xv, 590. 251 figs. Utrecht.

STANNIUS, A. 1841. Ueber den Verlauf der Arterien bei *Delphinus phocaena*. *Arch. Anat. Physiol Jg.*

—— 1849. Beschreibung der Muskeln des Tümmlers. *Ibid.*

TYSON, E. 1680. Phocaena, *or the Anatomy of a Porpess.* London, 4to.

WEINMANN, J. P. & Sicher, H. 1947. *Bone and Bones. Fundamentals of Bone Biology.* 1–464, 389 figs. London.

WOOD, A. B. 1955. *A Text-book of Sound, being an account of the physics of vibration with special reference to recent theoretical and technical developments.* 1–610, 159 figs, tables and plates. London.

YAMADA, M. 1953. Contribution to the Anatomy of the Organ of Hearing of Whales. *Sci. Rep. Whales Research Inst.* (*Japan*), No. **8**: 1–79, 29 figs.

EXPLANATION OF PLATES

PLATE 1

Phocaena phocoena (from Boenninghaus, 1903, his Plate 12, figs. 3, 4, 5 and 2).

(A) Ventral view of the soft parts of the pterygoid region.
(B) Ventral view of the right side of the pterygoid region 1 cm deep to figure A.
(C) Same view 1 cm deep to figure B.
(D) View of the right side of head after removal of subcutaneous muscle and fat.

The numerals used in the figures are referred to in the text.

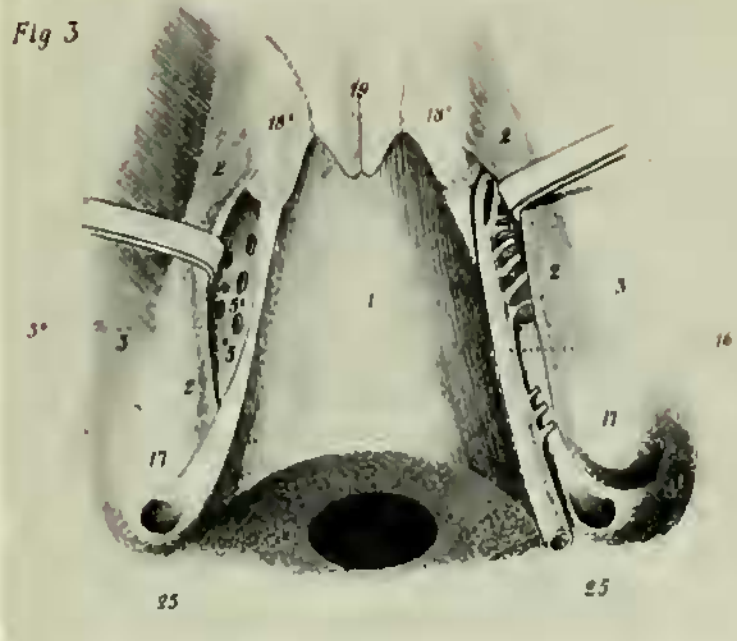
Fig 3
19
18'
18'
2
2
1
3
3'
3
5'
2
2
3
16
17
17
25
25

A

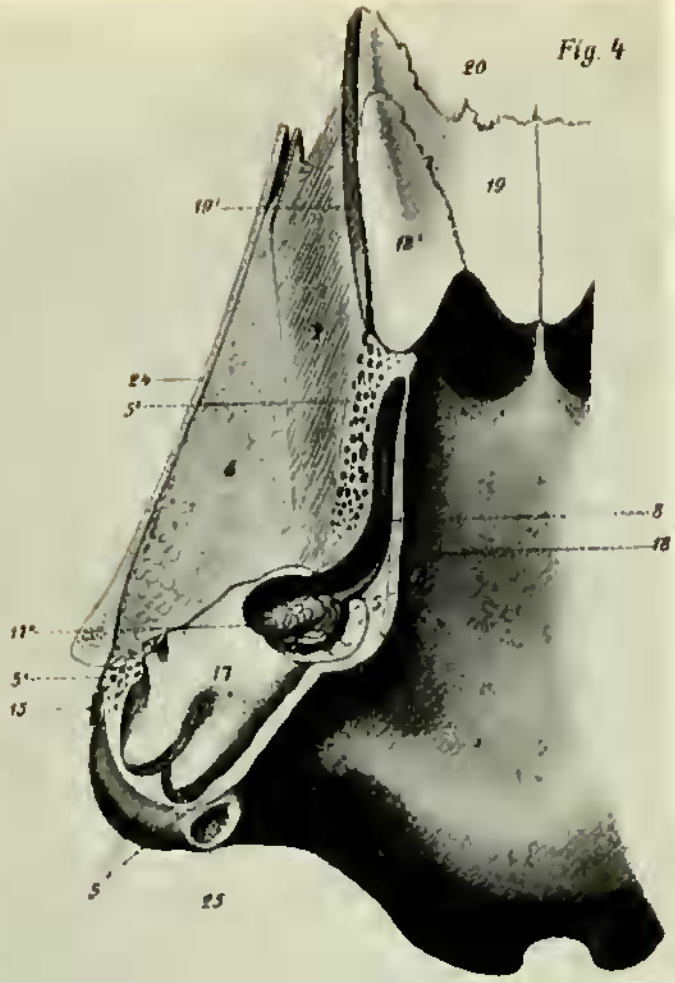
Fig. 4
20
19
18'
18'
24
5'
6
8
18
17
11'
5'
13
5
25

B

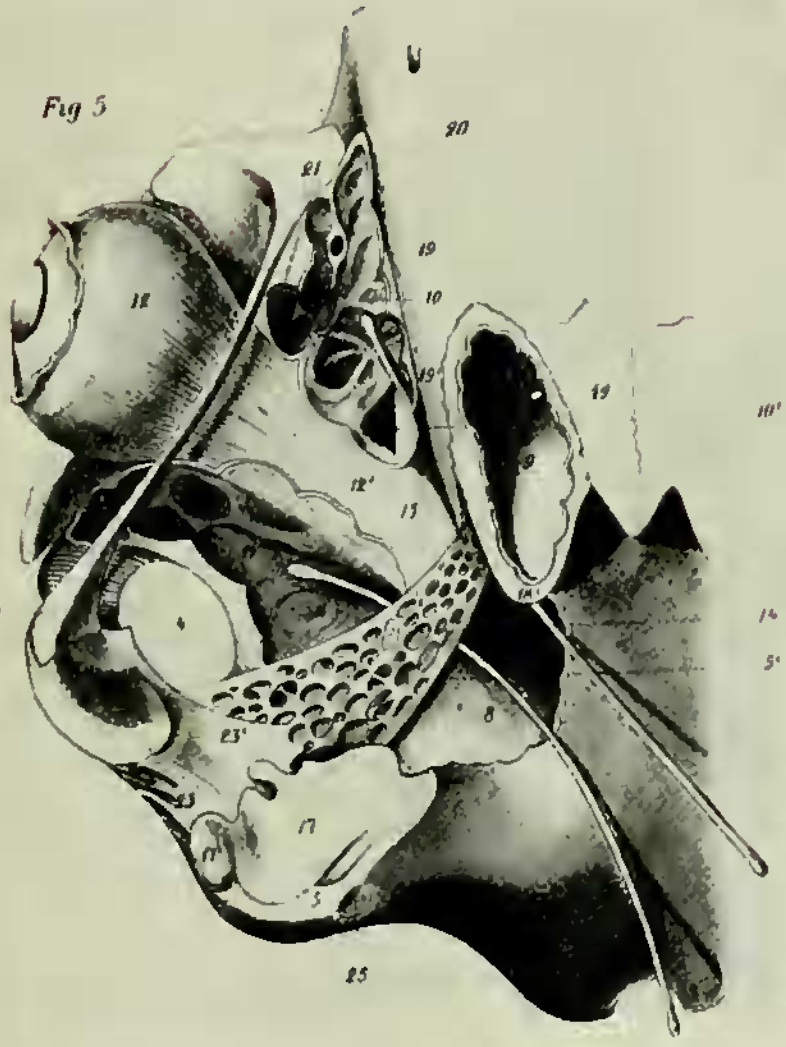
Fig 5
20
21
19
10
12
19'
19
10'
12'
13
22
21
14
5'
23'
8
17
5
25

C

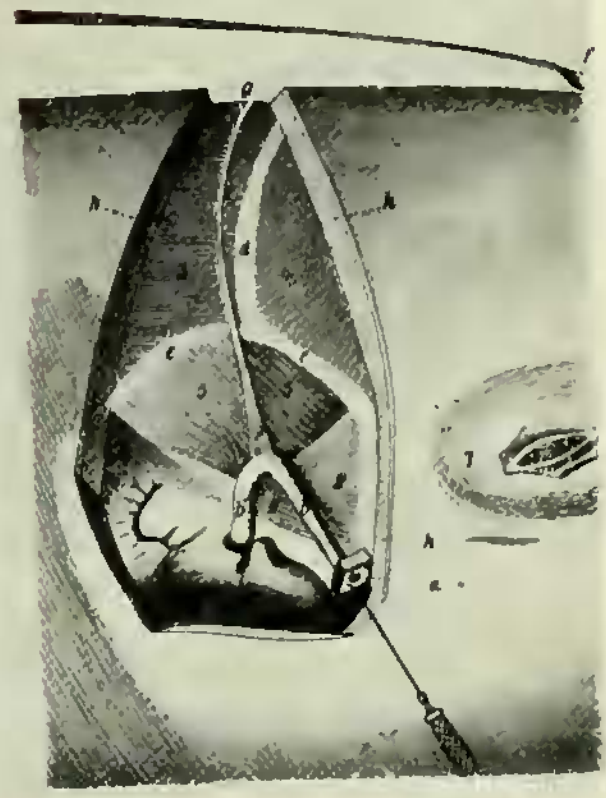
f
g
h
h
d
d
c
5
5
g
7
h
a

D

PLATE 2

Sections of the mucous membrane of the pterygoid sinus of *Globicephala melaena.*

(A) Section cut in a plane parallel with and near to the surface of the mucous membrane (× 50).

(B) Longitudinal section of the pterygoid sinus lateral wall (× 160).

(C) Enlarged portion of mucous gland shown in figure B (× 600).

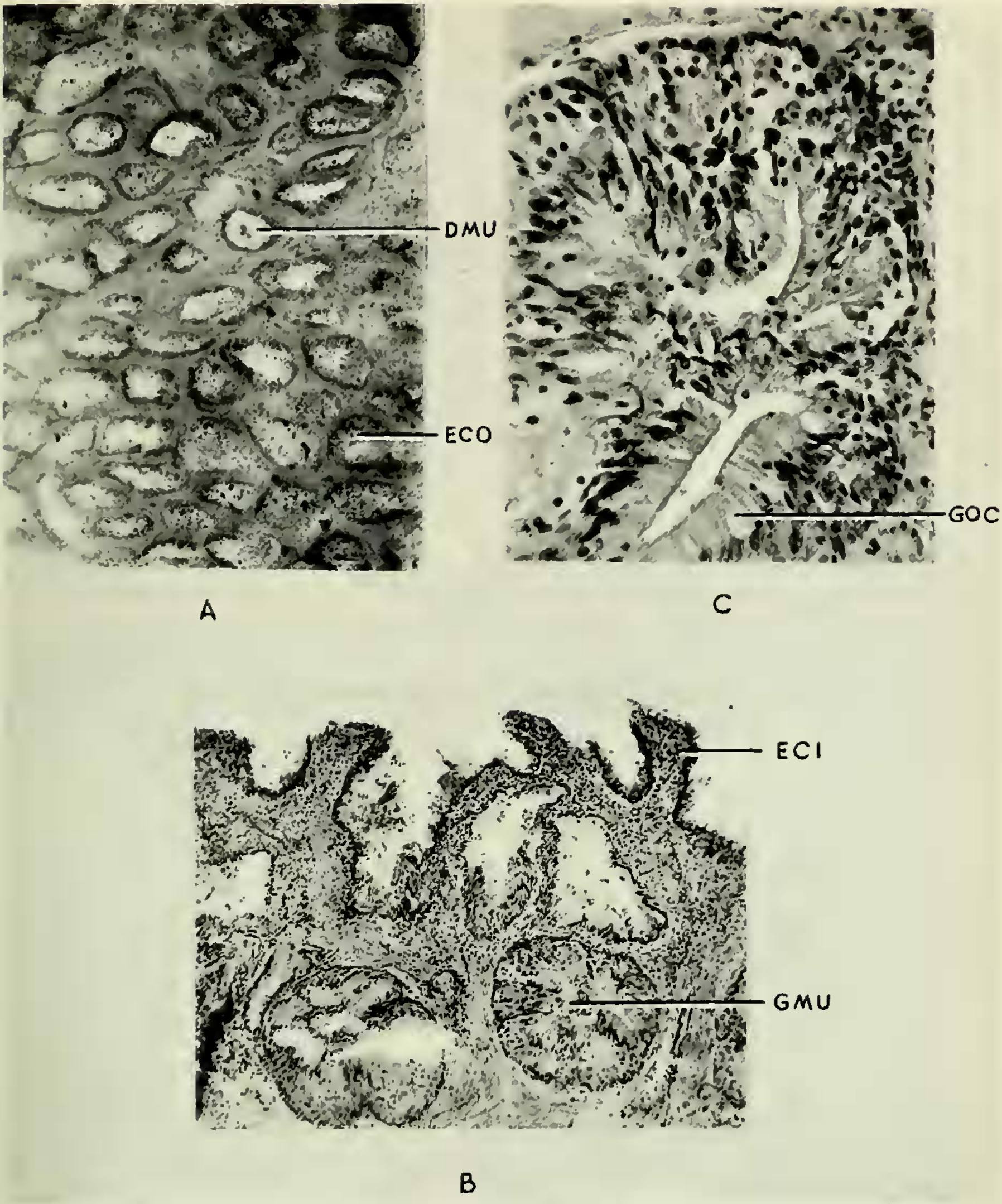
DMU
ECO
A
GOC
C
ECI
GMU
B

PLATE 3

(A) Longitudinal section through the lateral wall of the pterygoid sinus (× 8).

(B) Longitudinal section through the mesial wall of the pterygoid sinus (× 8).

(C) Section cut in a plane parallel with [and deep to that shown in] Plate 2, figure A (× 100).

(D) Section showing contents of lymph spaces (LS) (× 1000).

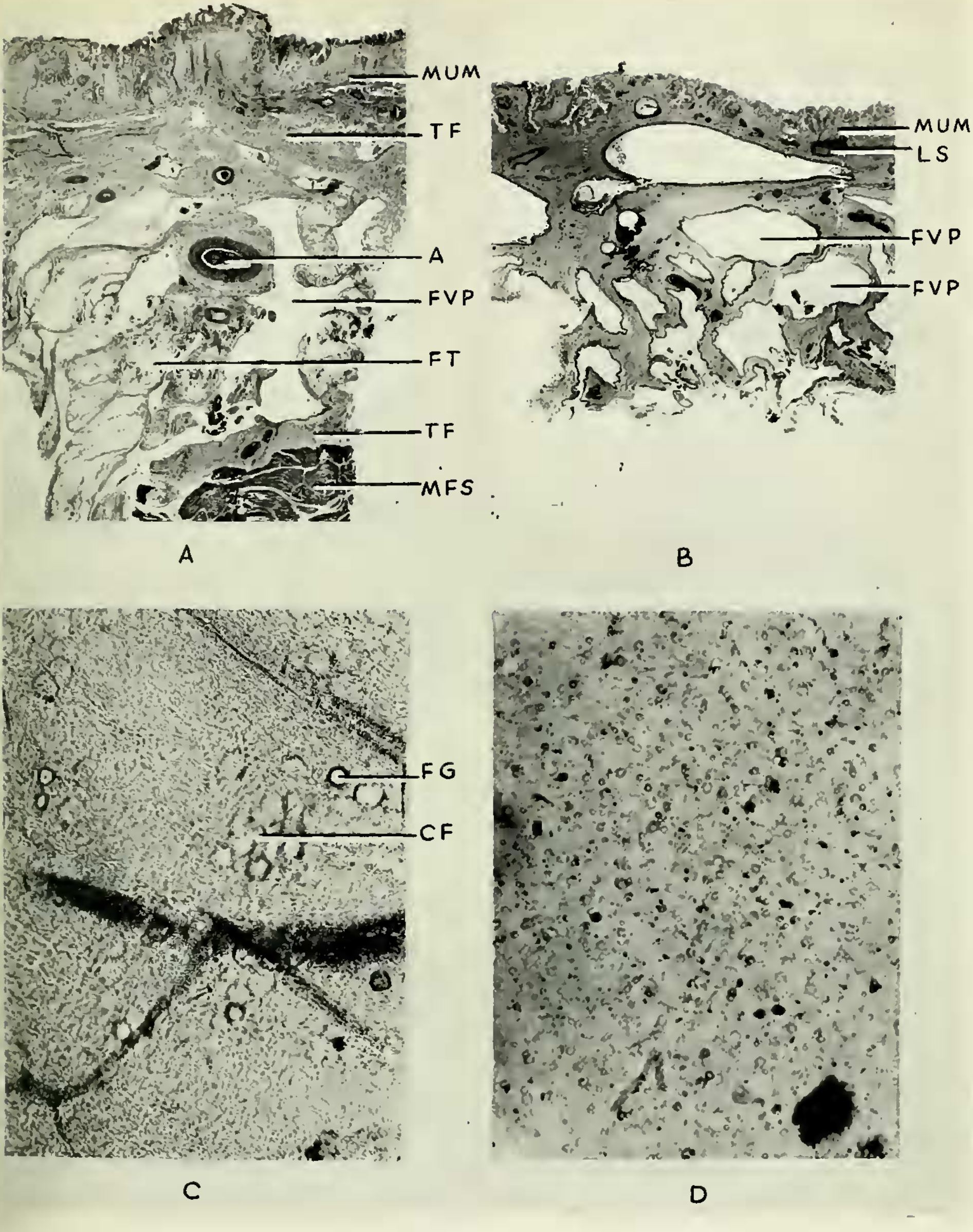
MUM
TF
A
FVP
FT
TF
MFS
A
MUM
LS
FVP
FVP
B
FG
CF
C
D

PLATE 4

(A) Section at right angles to Plate 3, figure A (× 8).

(B) Section through lateral wall of the pterygoid sinus in the region anterior to the tympanic bulla (× 4).

(C) Transverse section of the intra-mandibular fatty body (× 8).

(D) Transverse section of fat external to mandible (× 8).

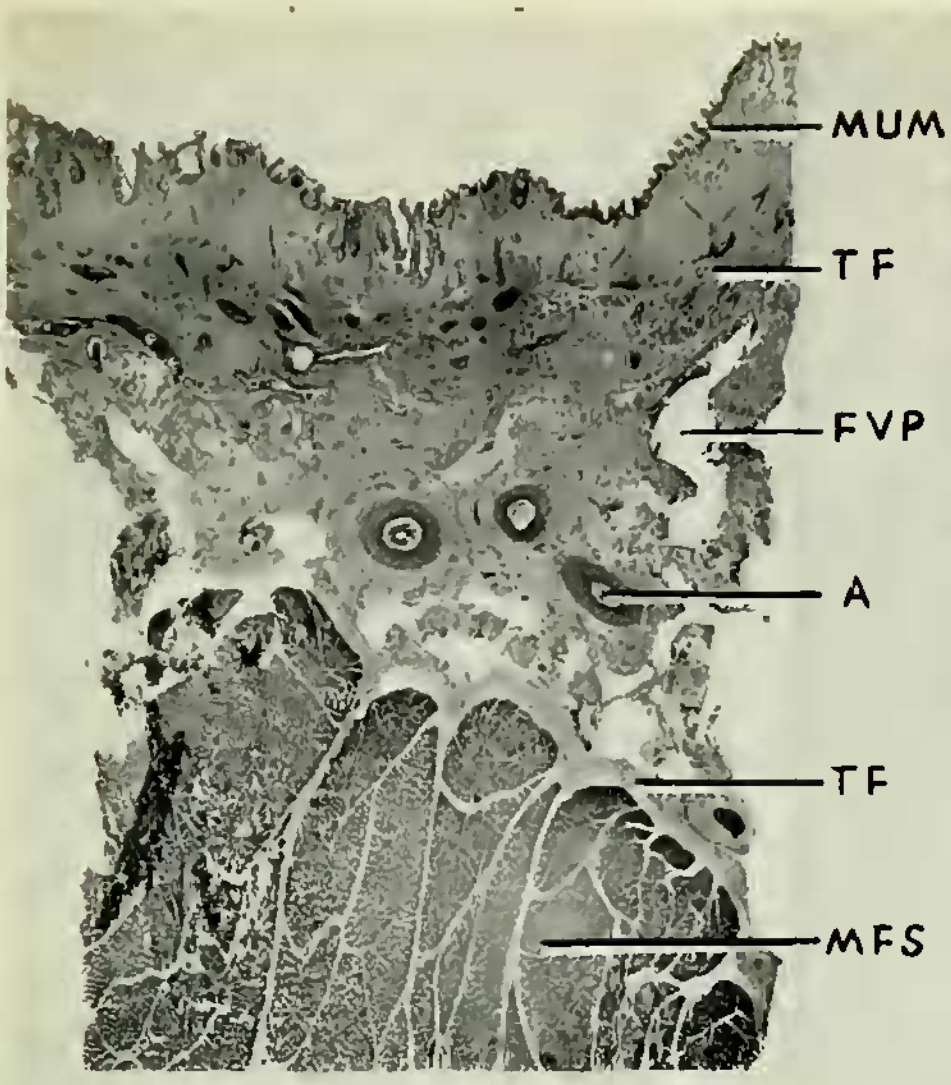

A

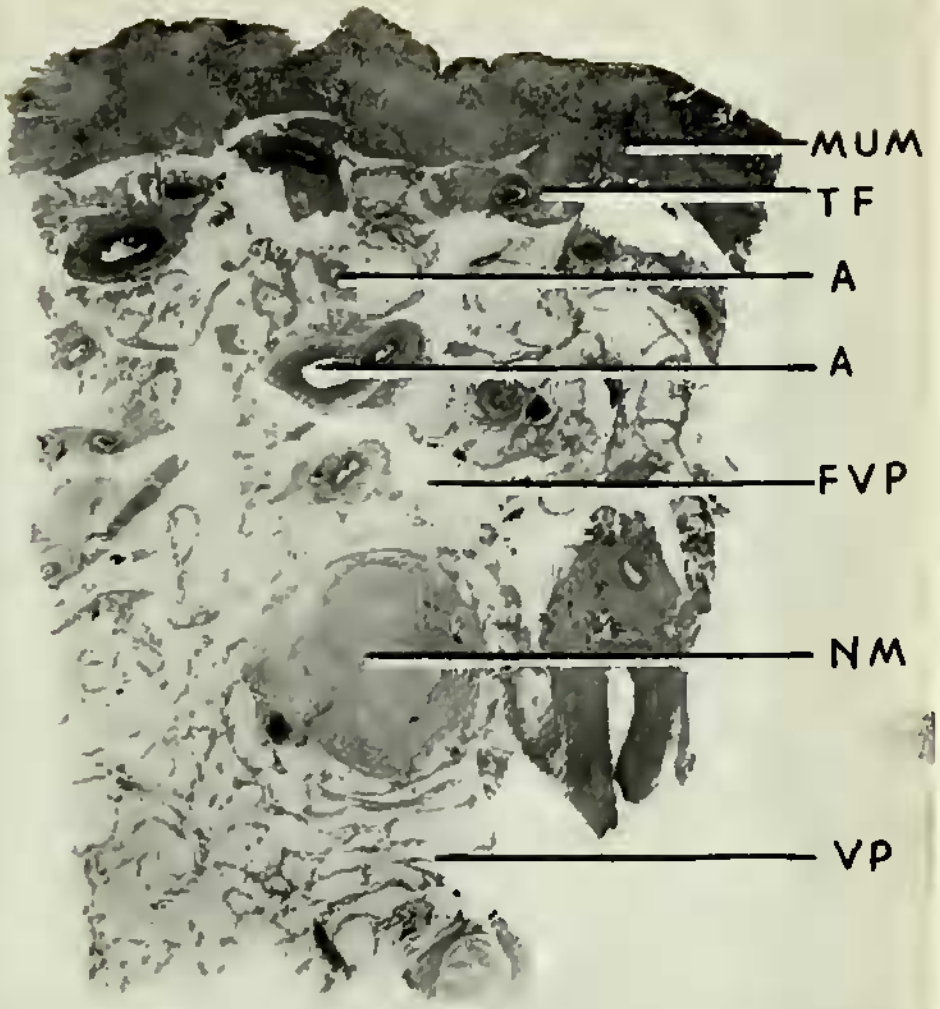

B

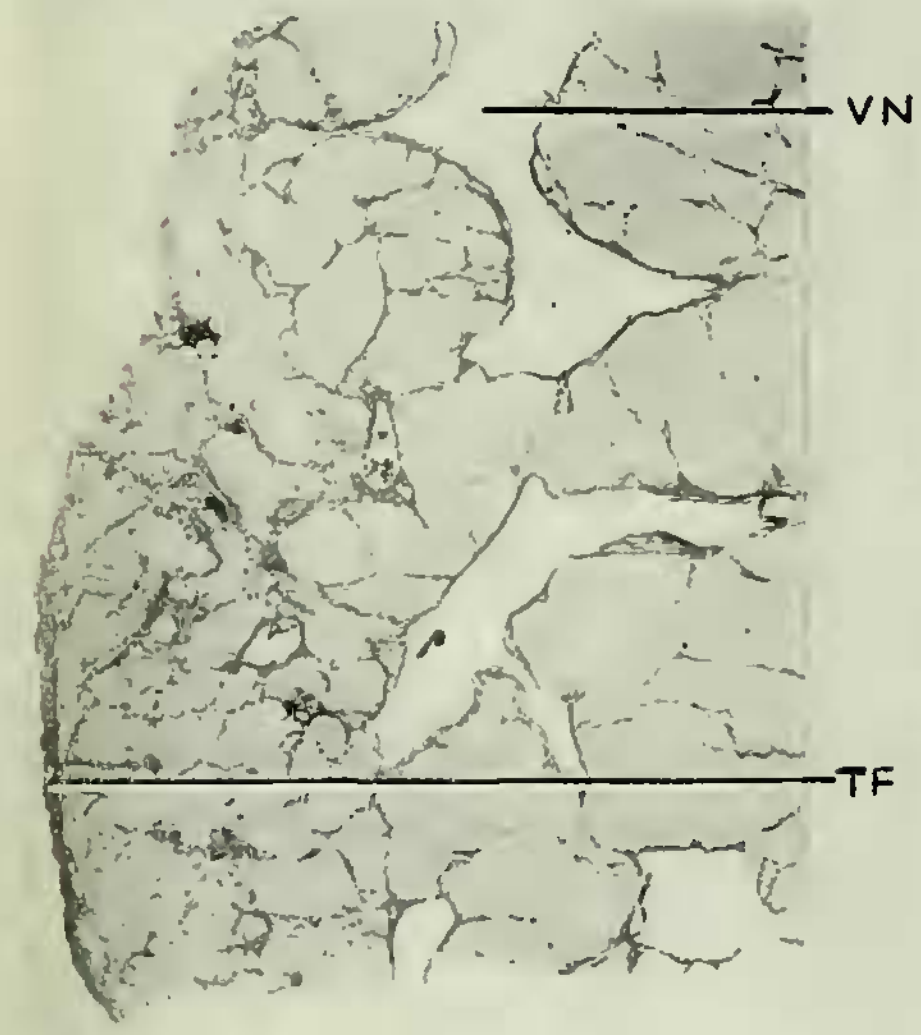

C

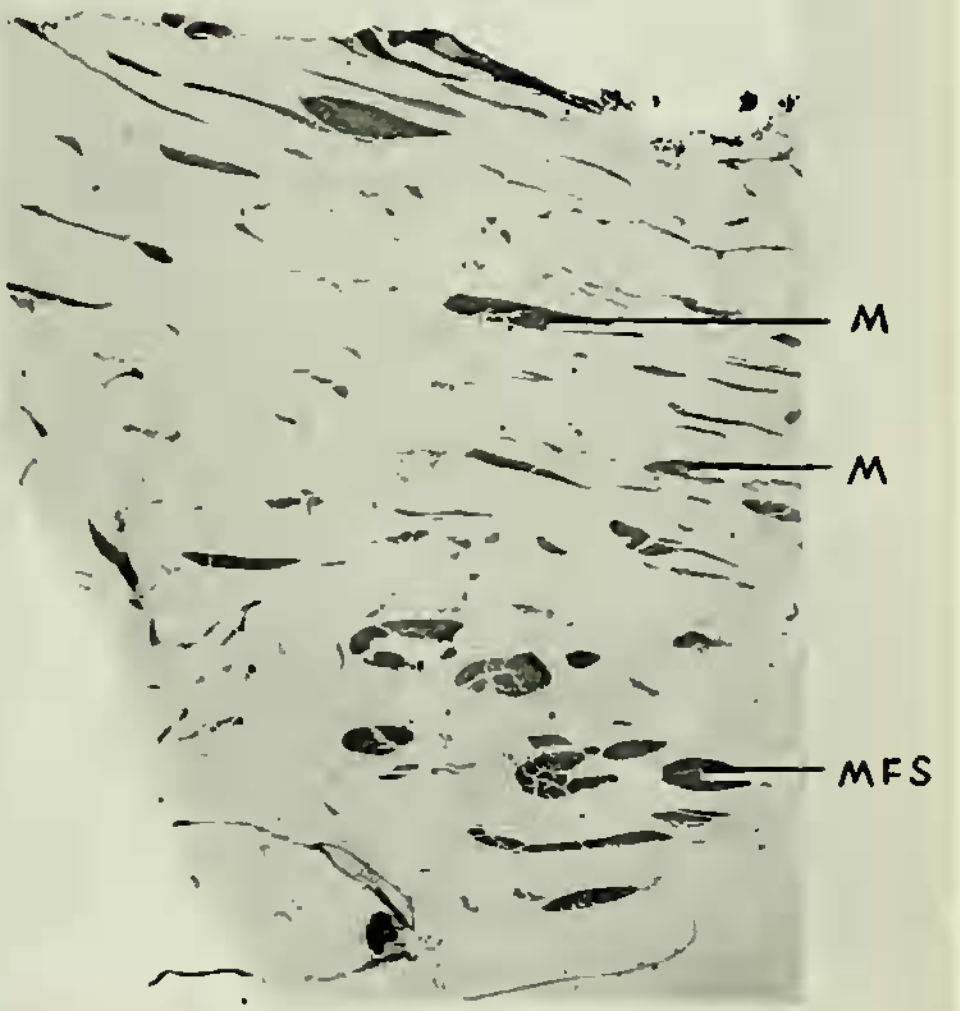

D

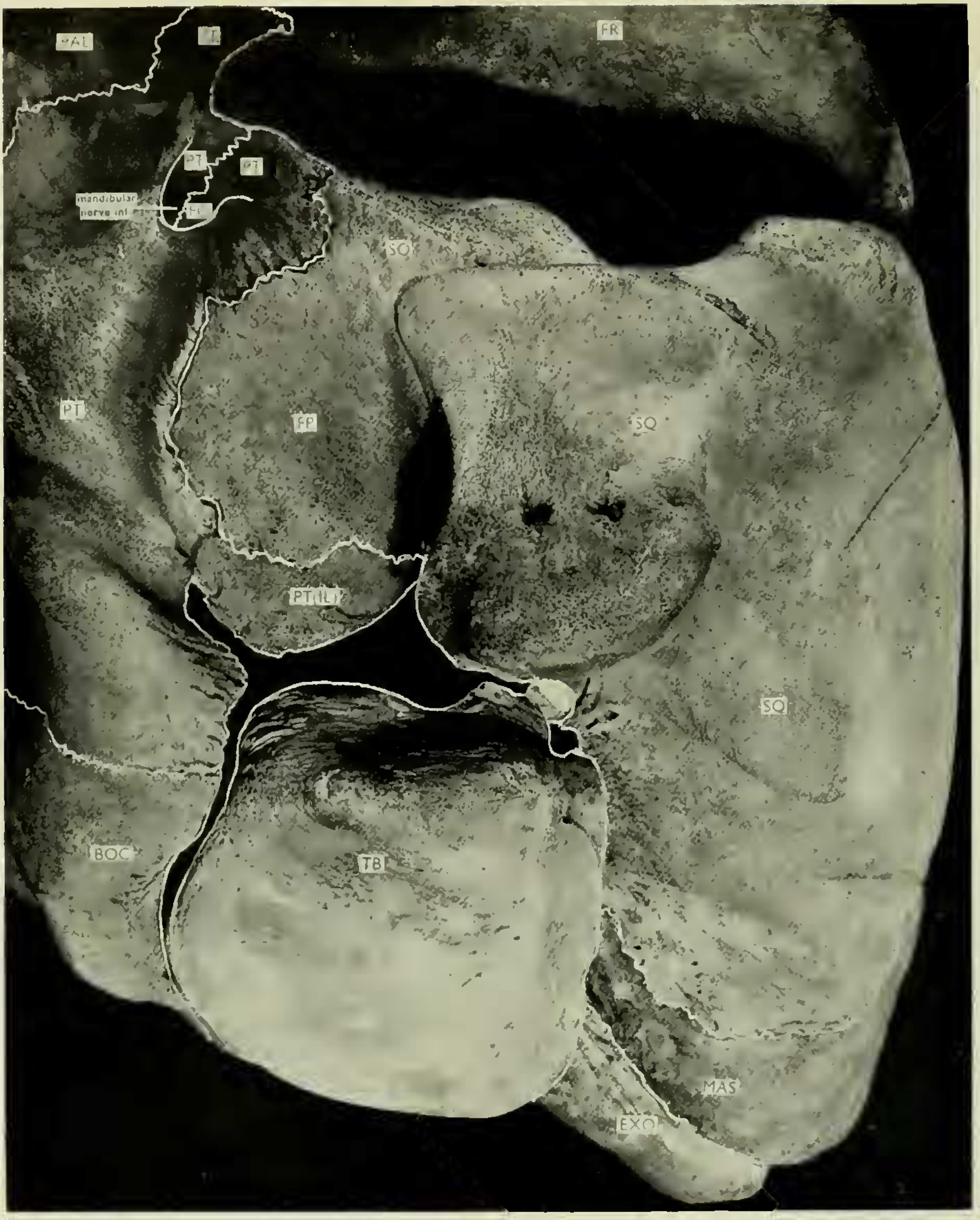

PLATE 5

Caperea marginata (Reg. No. 1876.2.16.1)
Ventral view of postero-lateral region of the skull, left side.

PLATE 6

Caperea marginata (Reg. No. 1876.2.16.1)
Ventral view of postero-lateral region of the skull, right side with tympanic bulla removed.

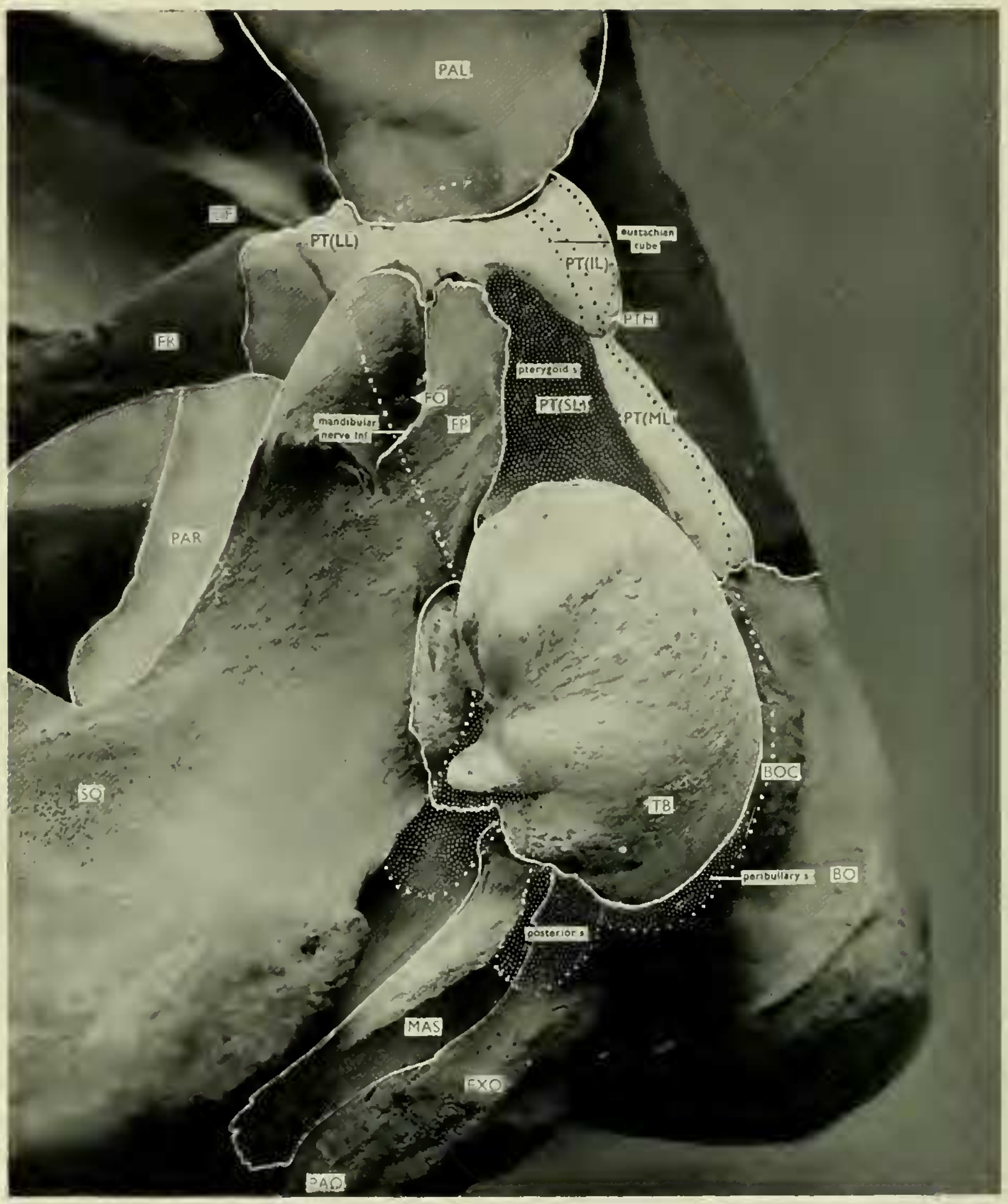

PLATE 7

Balaenoptera acutorostrata (Reg. No. S.W. 1926/33)
Ventro-lateral view of the pterygoid and adjacent regions of the skull.

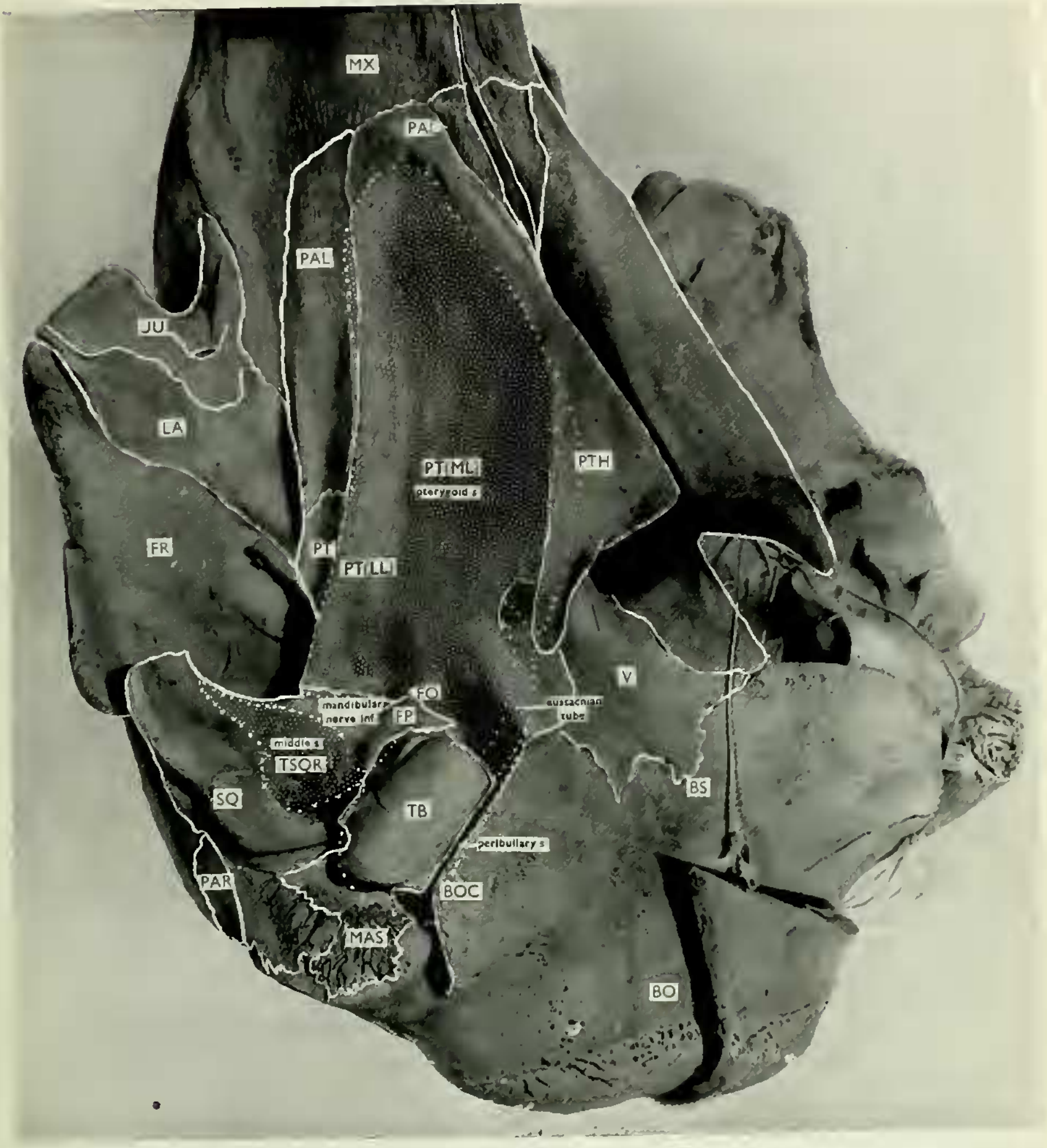

PLATE 8

Hyperoodon ampullatus (Reg. No. S.W. 1938/40)
Ventro-lateral aspect of the skull base.

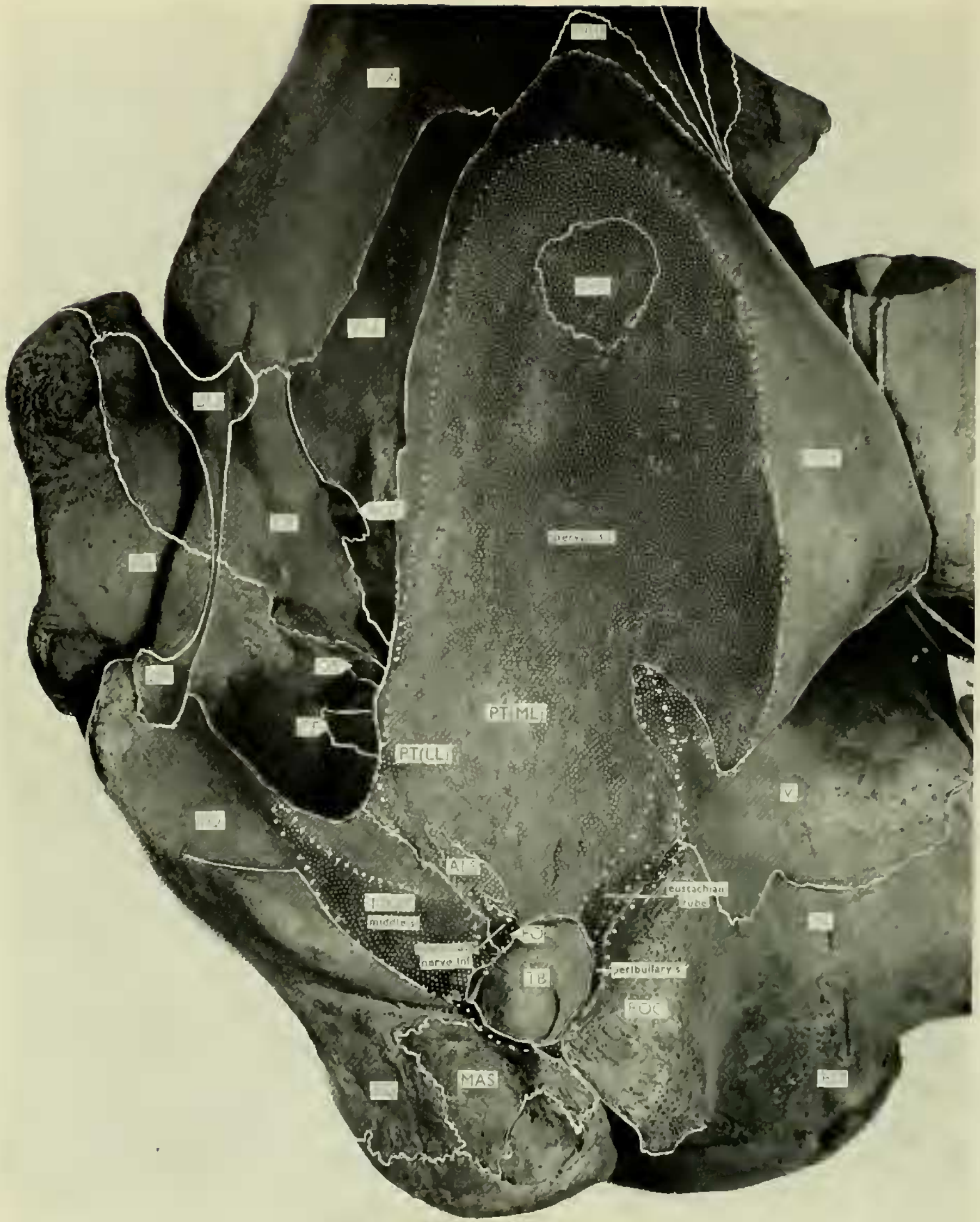

PLATE 9

Berardius arnuxi (Reg. No. 1923.11.16.1)
Ventro-lateral aspect of the skull base.

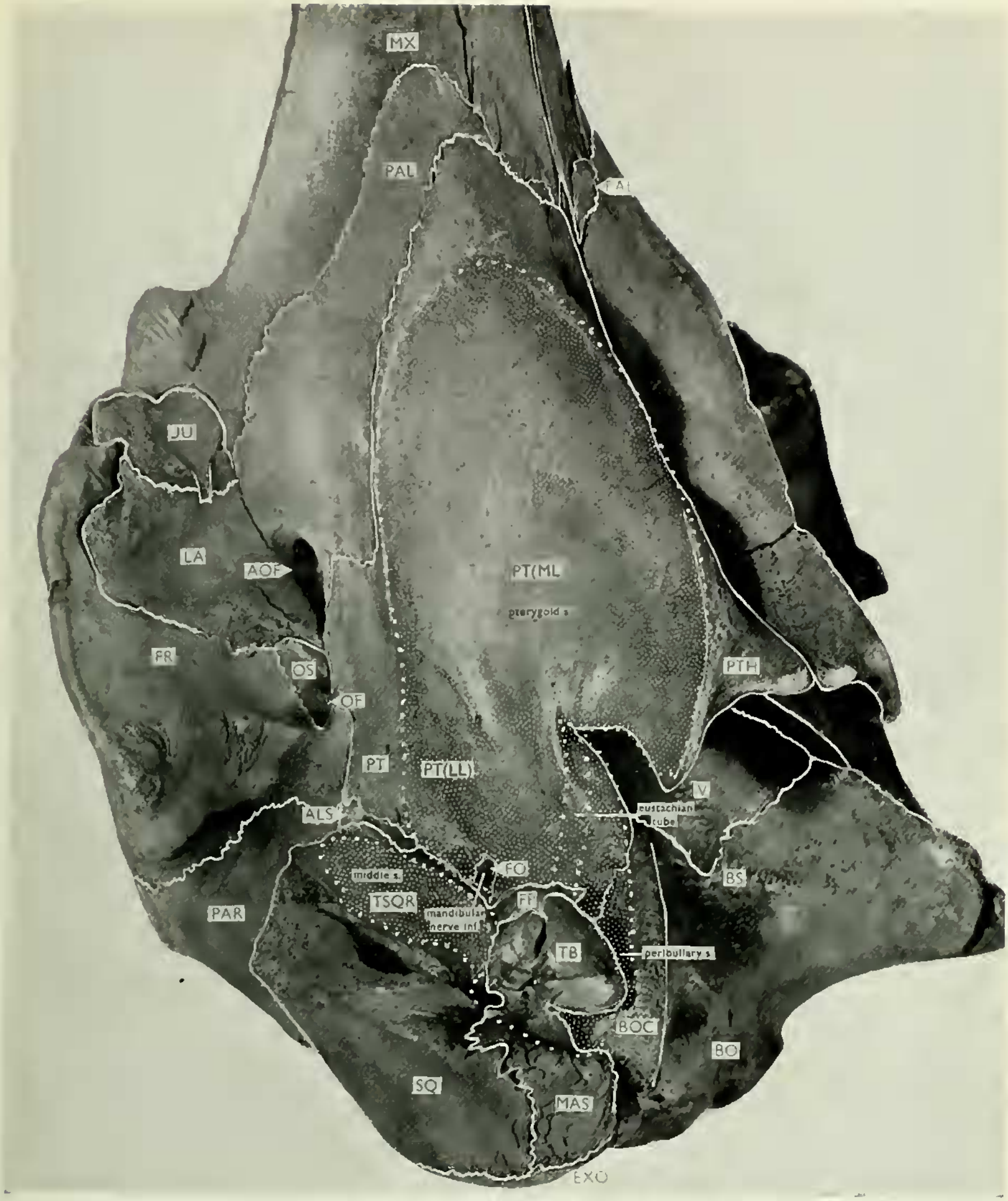

PLATE 10

Ziphius cavirostris (Reg. No. 1920/9)
Ventro-lateral aspect of the skull base.

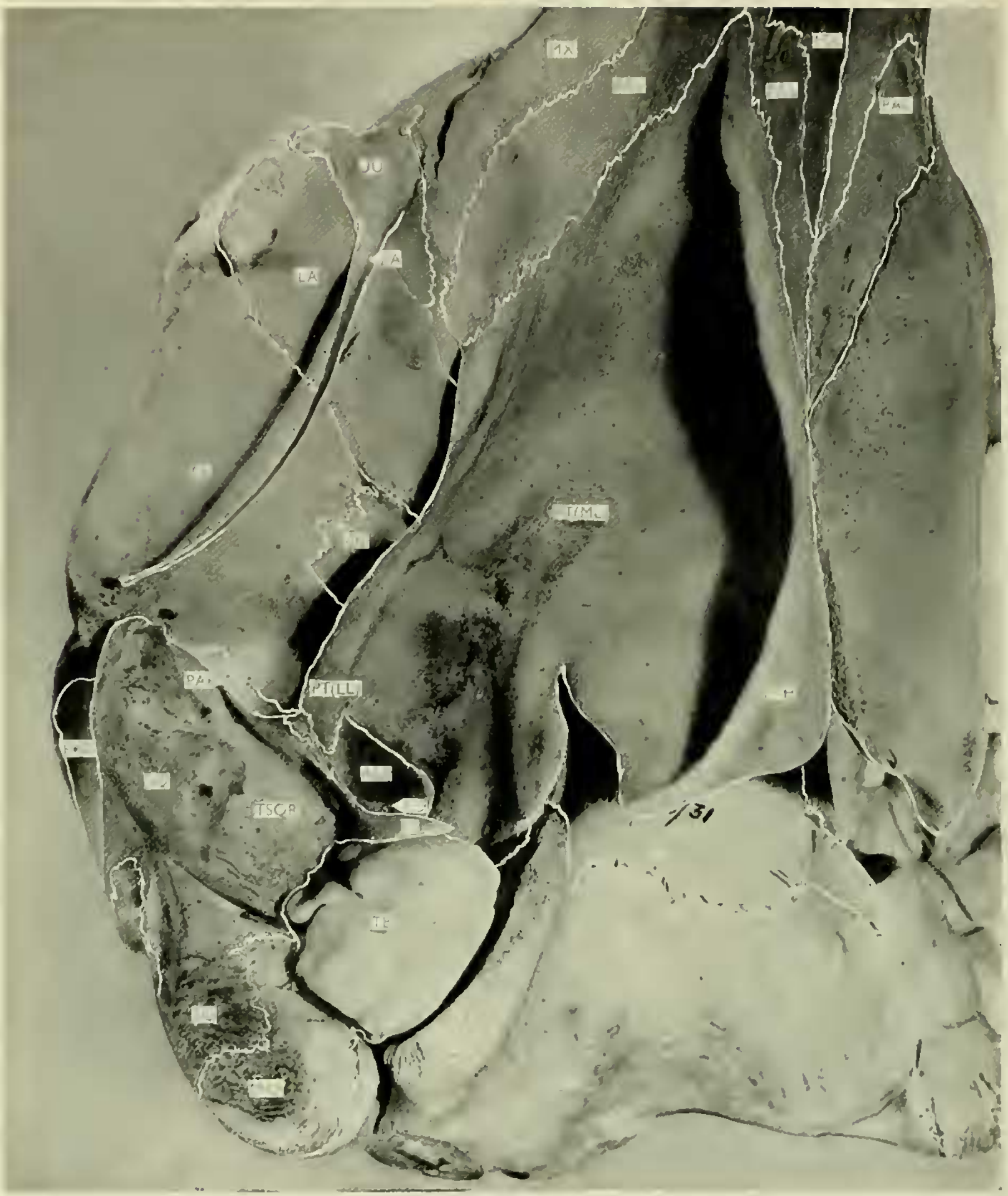

PLATE 11

Mesoplodon bidens (Reg. No. S.W.1938/31)
Ventro-lateral aspect of the skull base.

PLATE 12

Mesoplodon bidens (Reg. No. S.W. 1949/26)
Skull showing internal cast of air sinuses.

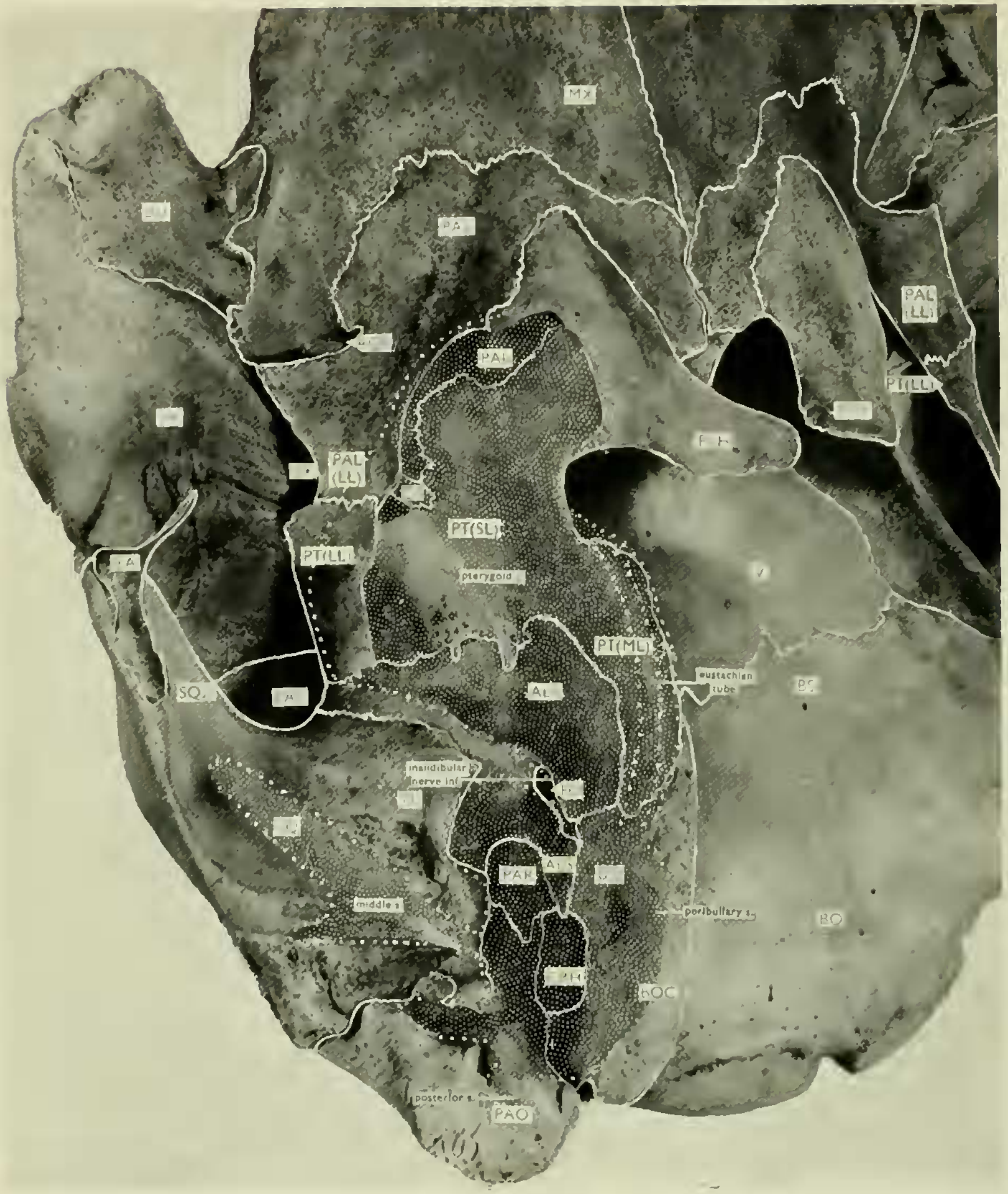

PLATE 13

Monodon monoceros (Reg. No. 1949.11.2.1)
Base of skull of adult ventro-lateral aspect.

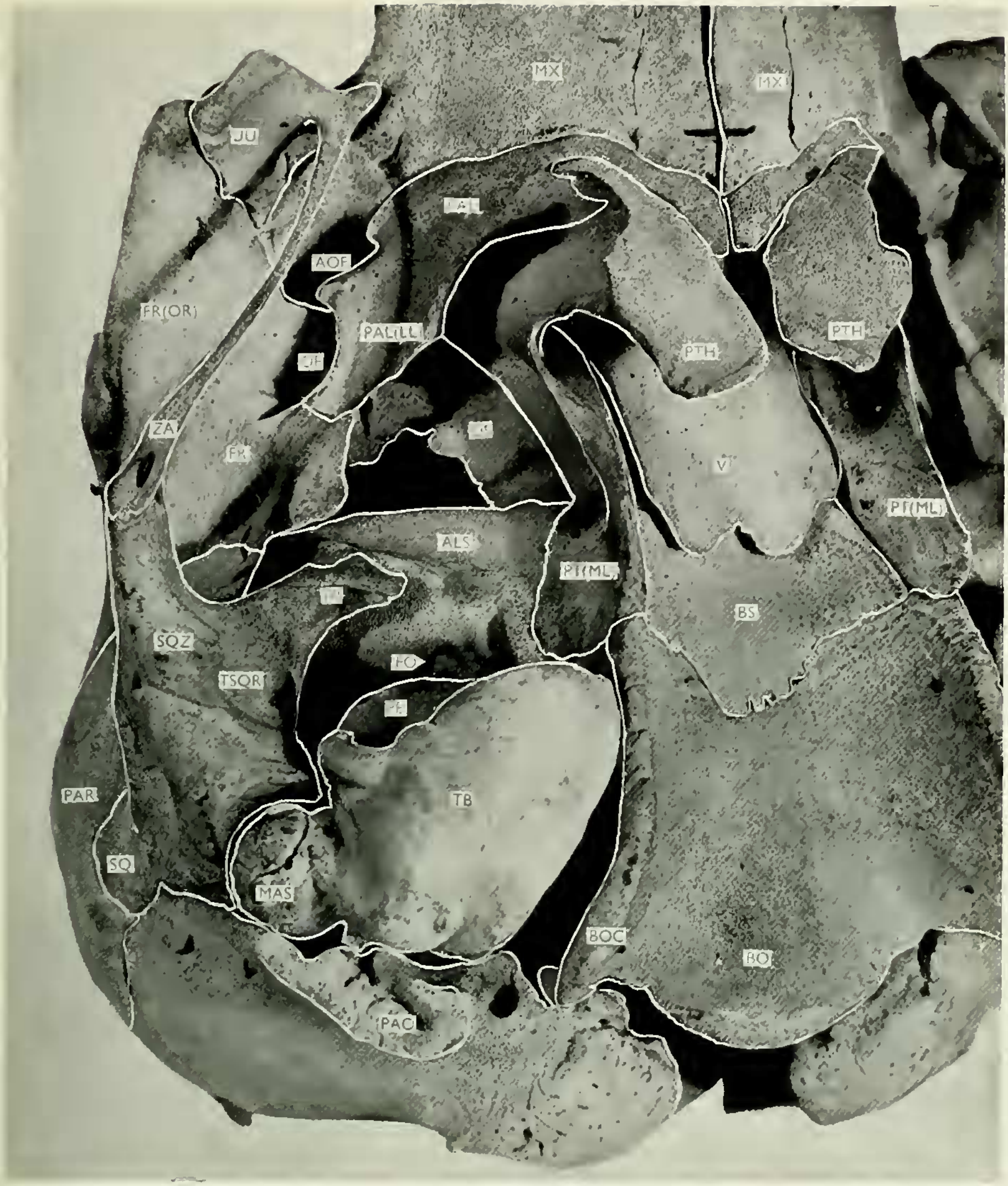

PLATE 14

Monodon monoceros juv. (Reg. No. 1887.9.8.1)
Ventro-lateral aspect of skull base.

PLATE 15

Delphinapterus leucas (Reg. No. 1933.10.13.1)
Ventro-lateral aspect of skull base.

PLATE 16

Kogia breviceps (Reg. No. 1952.8.23.1)
Ventro-lateral aspect of the skull base.

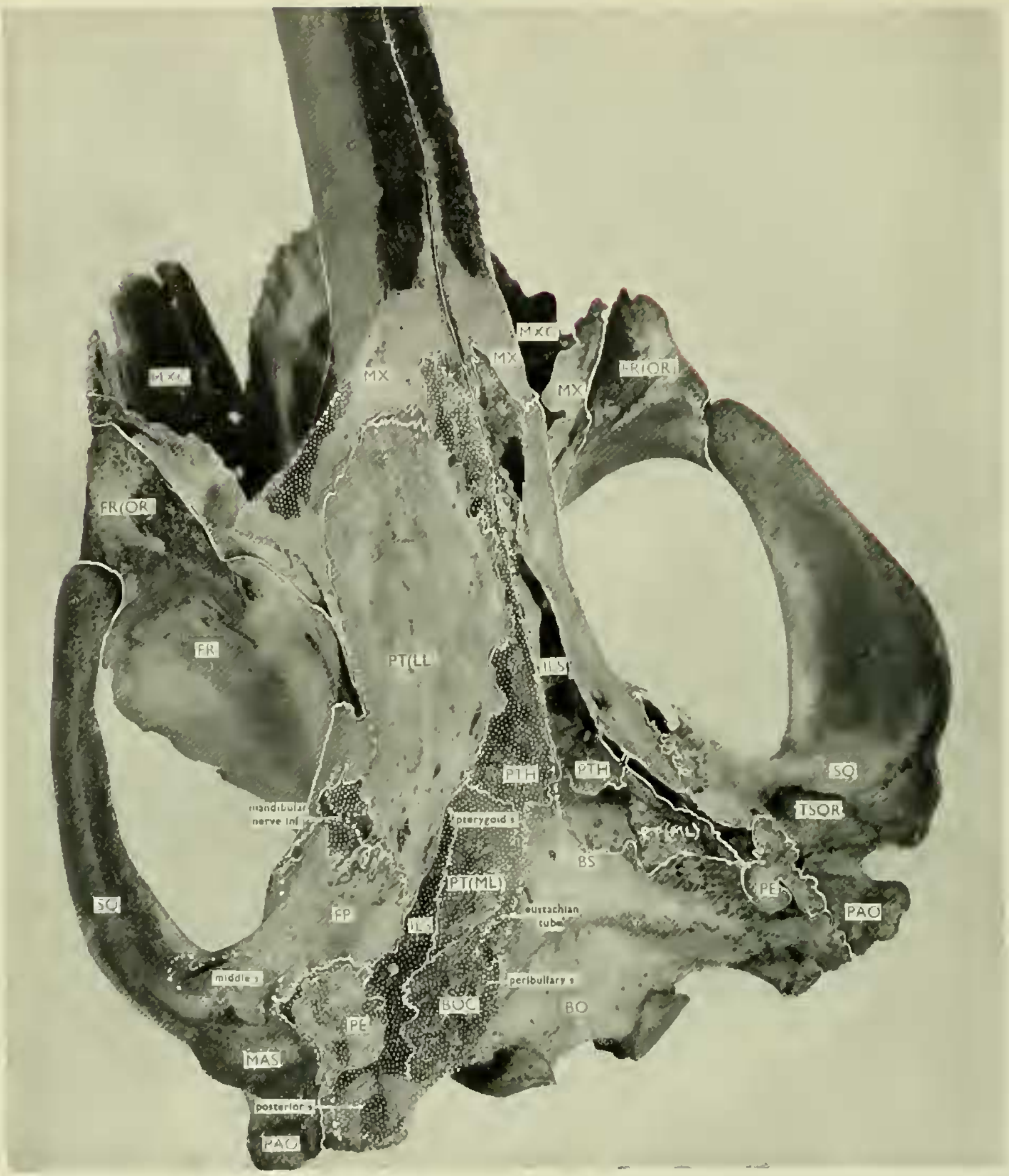

PLATE 17

Platanista gangetica, adult (Reg. No. 1843.8.18.5)
Ventro-lateral aspect of the skull base.

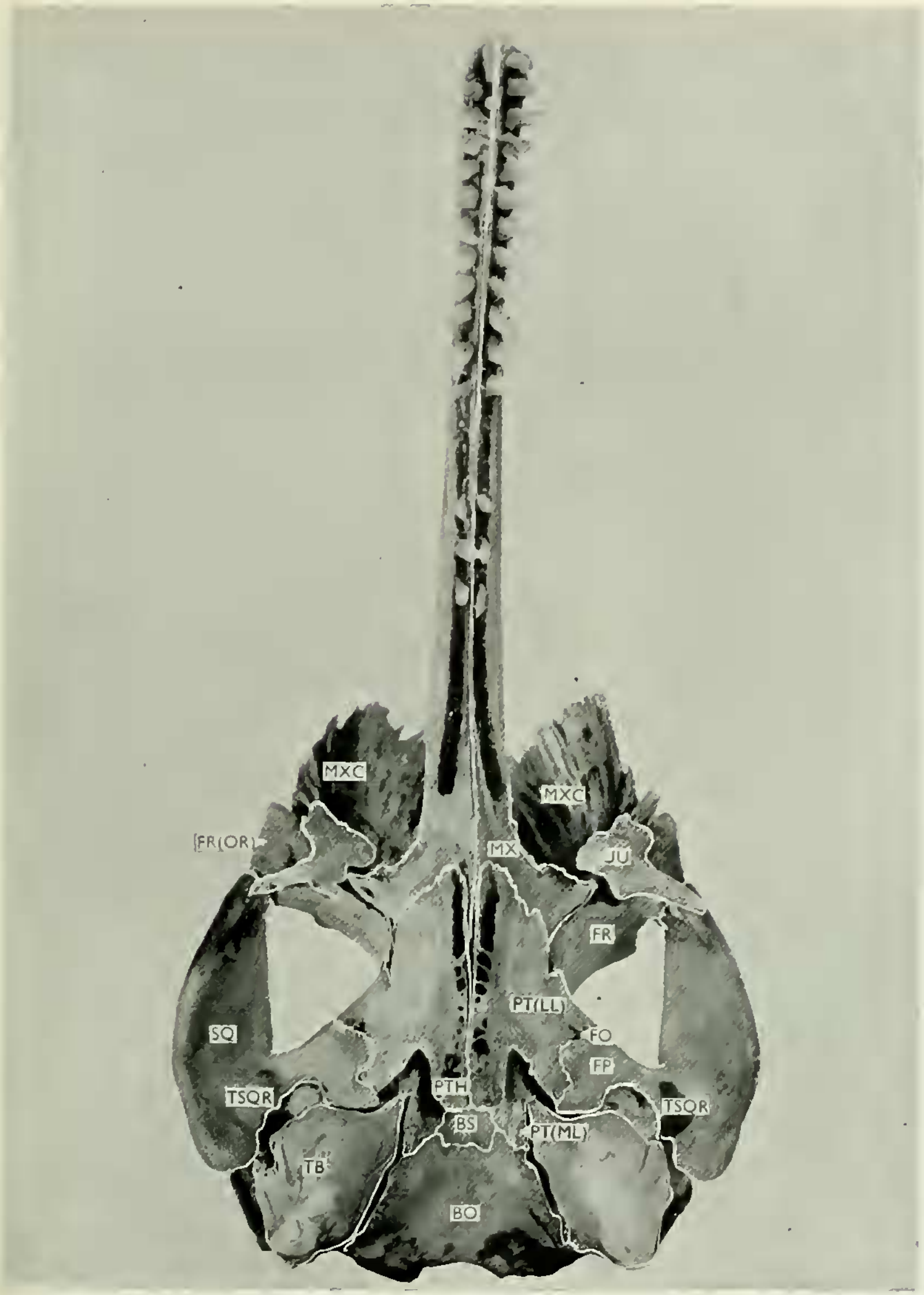

PLATE 18

Platanista gangetica, juv. (Reg. No. 1646A)
Ventral aspect of skull.

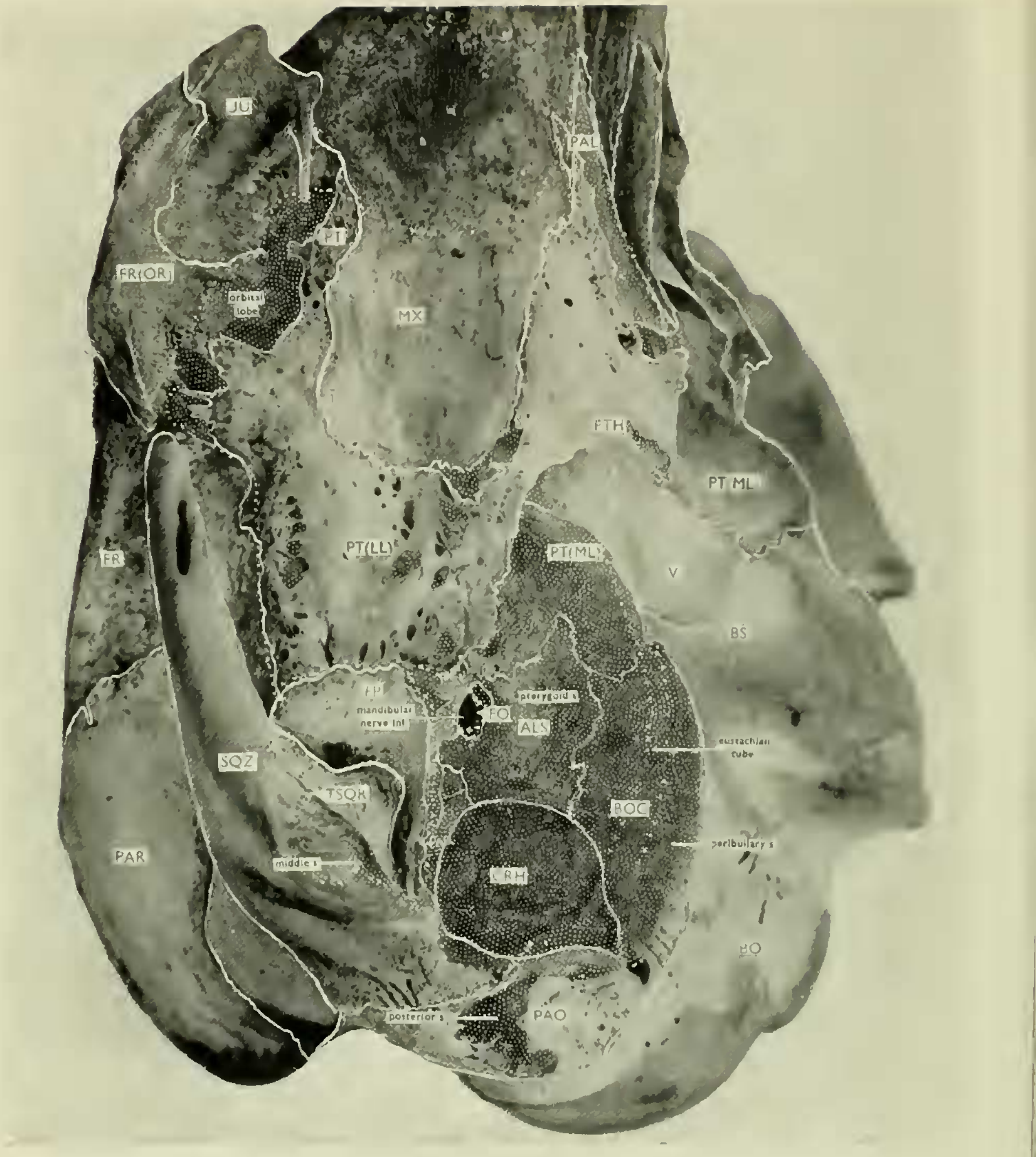

PLATE 19

Stenodelphis blainvillei (Reg. No. 1925.11.20.1)
Ventro-lateral aspect of skull base.

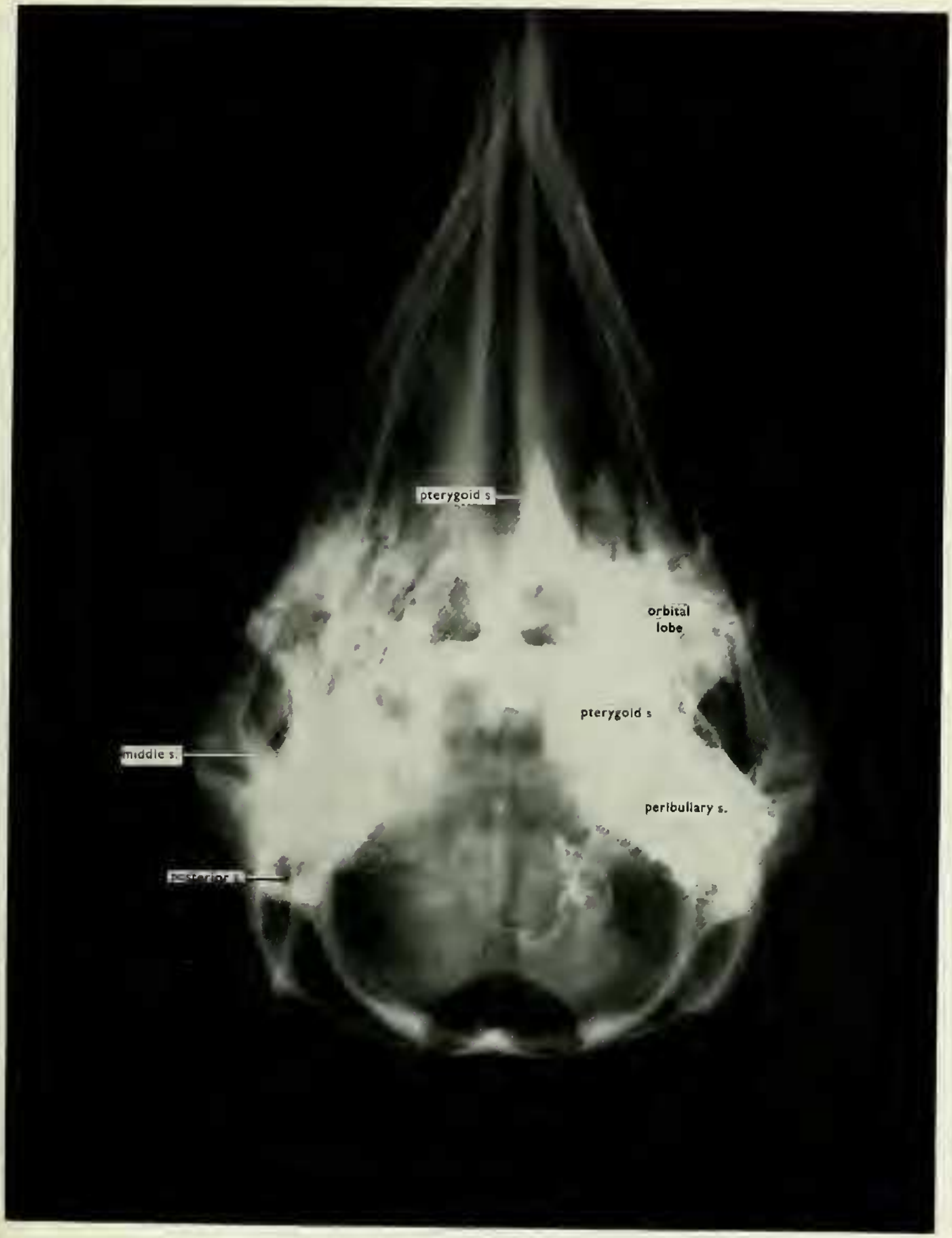

PLATE 20

Stenodelphis blainvillei (no history)
Radiograph of head, sinuses injected with iodized oil.

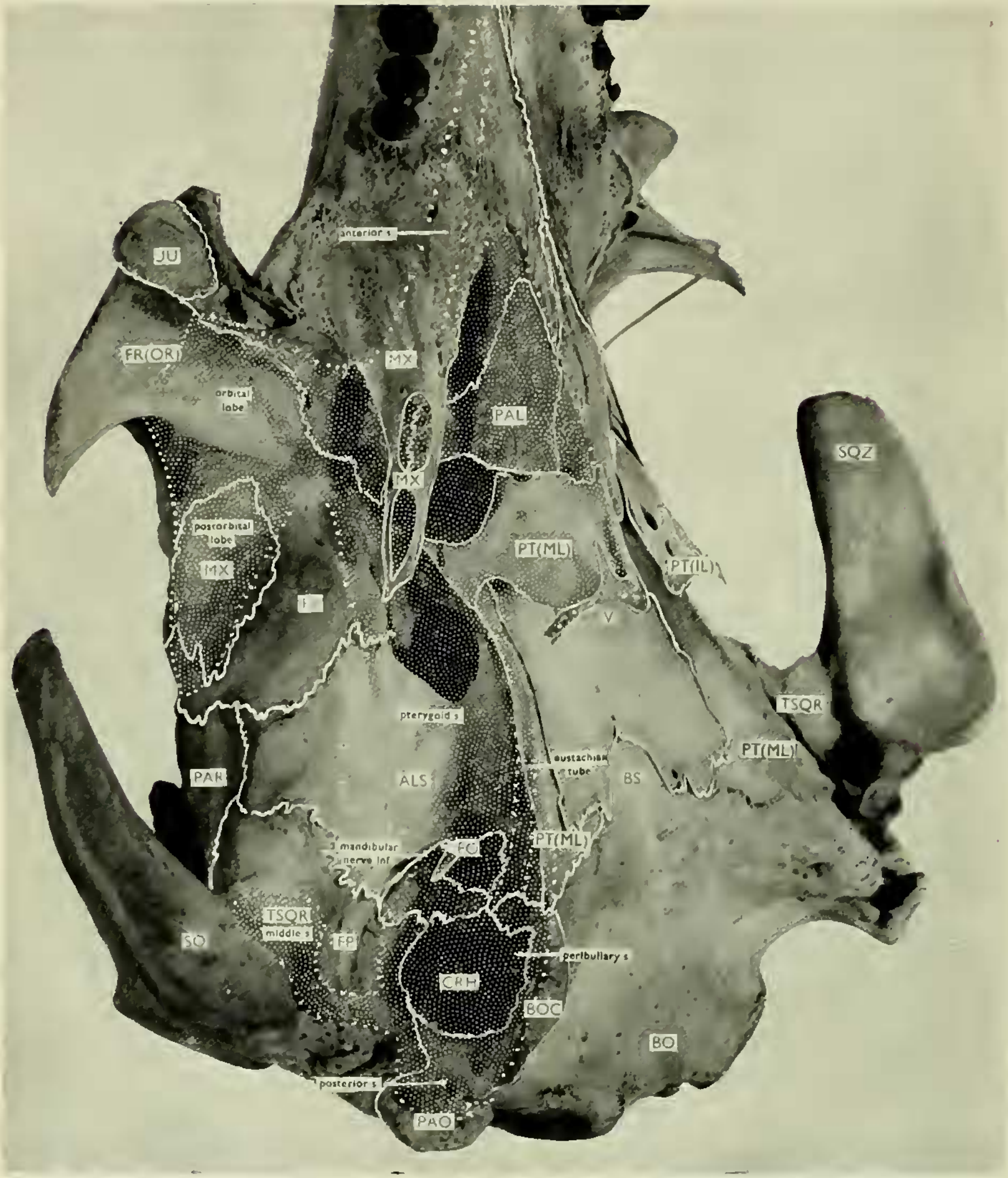

PLATE 21

Inia geoffrensis (Reg. No. 1939.5.13.1)
Ventro-lateral aspect of skull base.

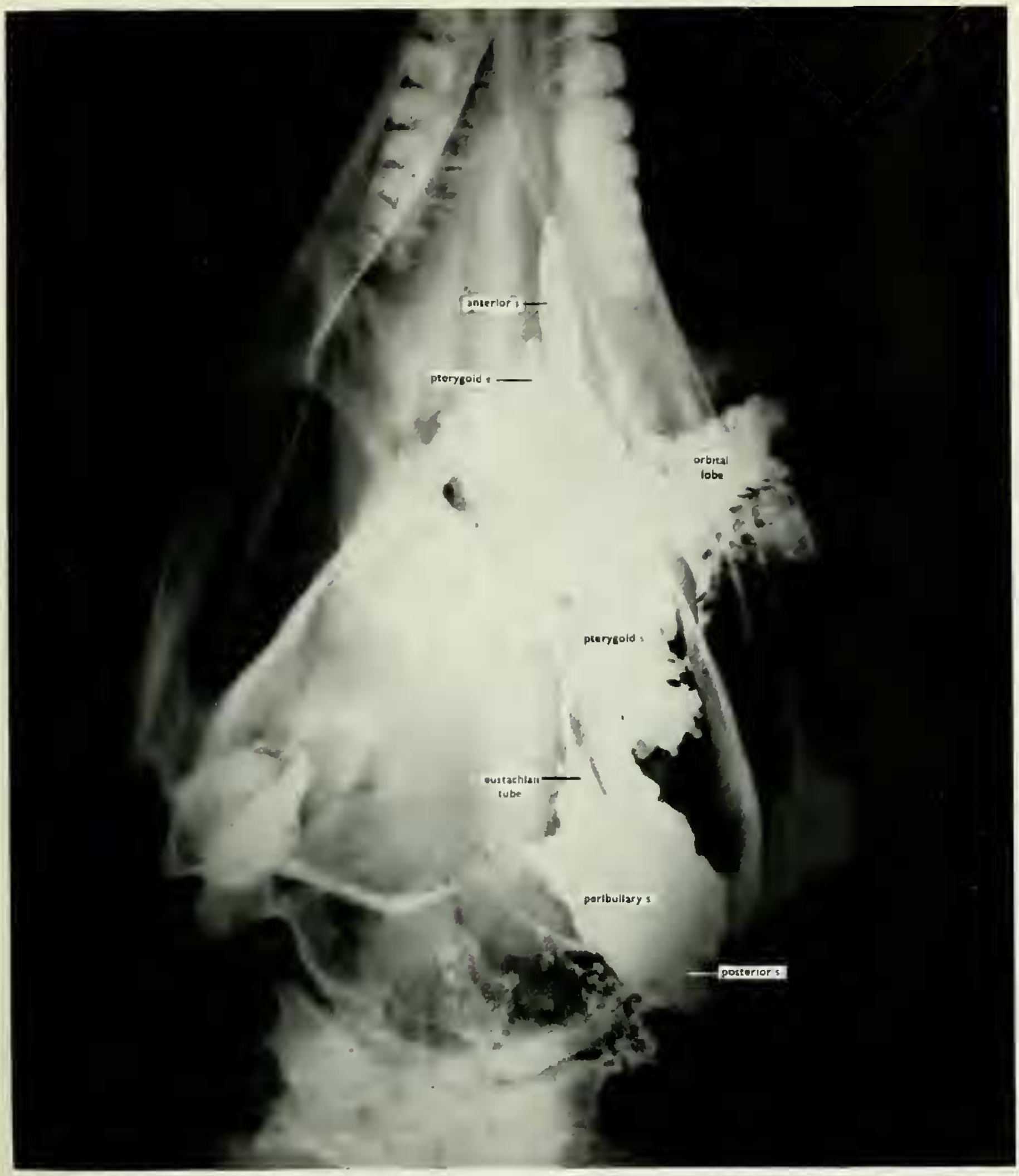

PLATE 22

Inia geoffrensis (Reg. No. 526.12.8.25)
Radiograph of head, sinuses of one side injected with iodized oil.

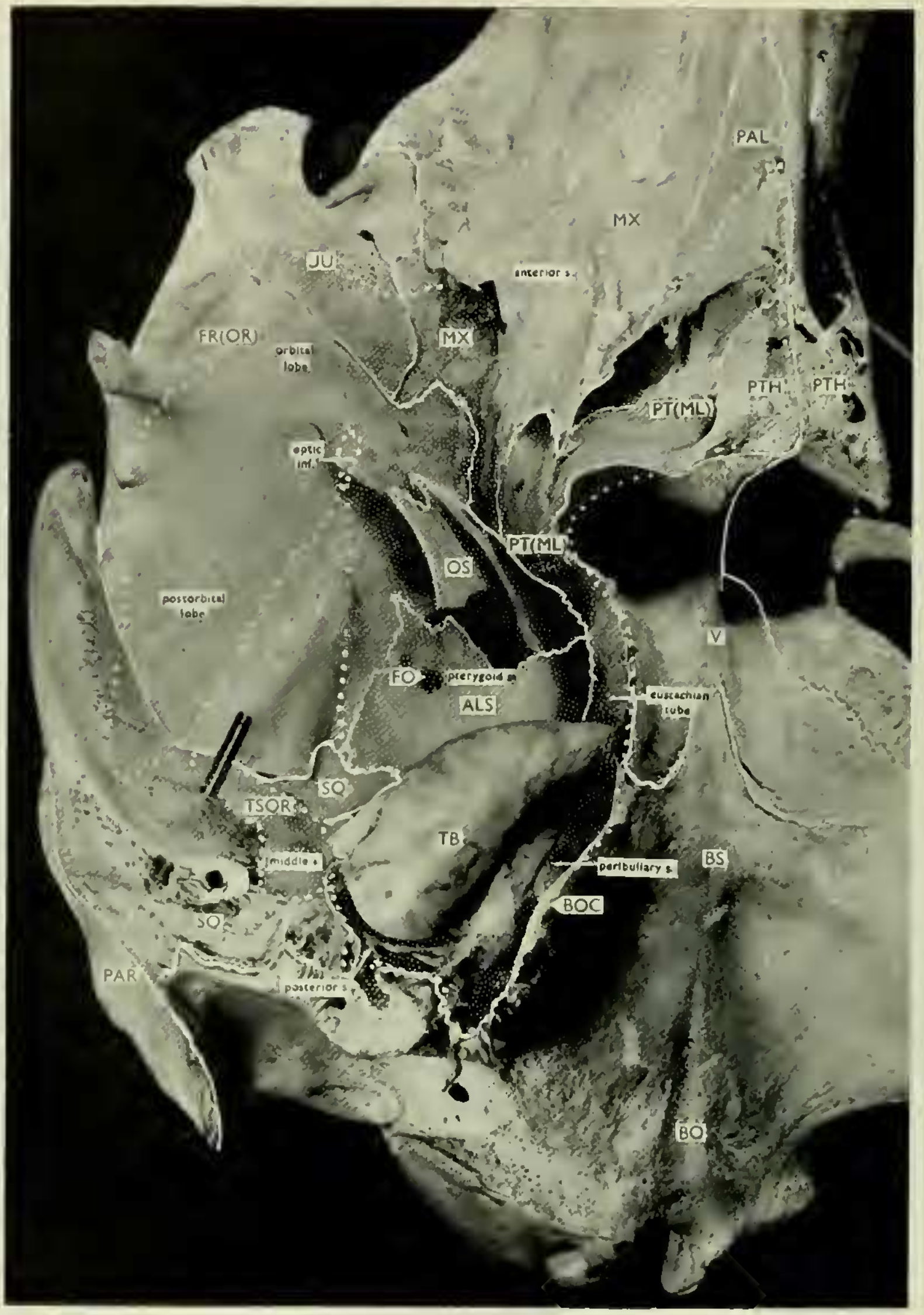

PLATE 23

Lipotes vexillifer (Reg. No. 22.6.22.1)
Ventro-lateral aspect of skull base.

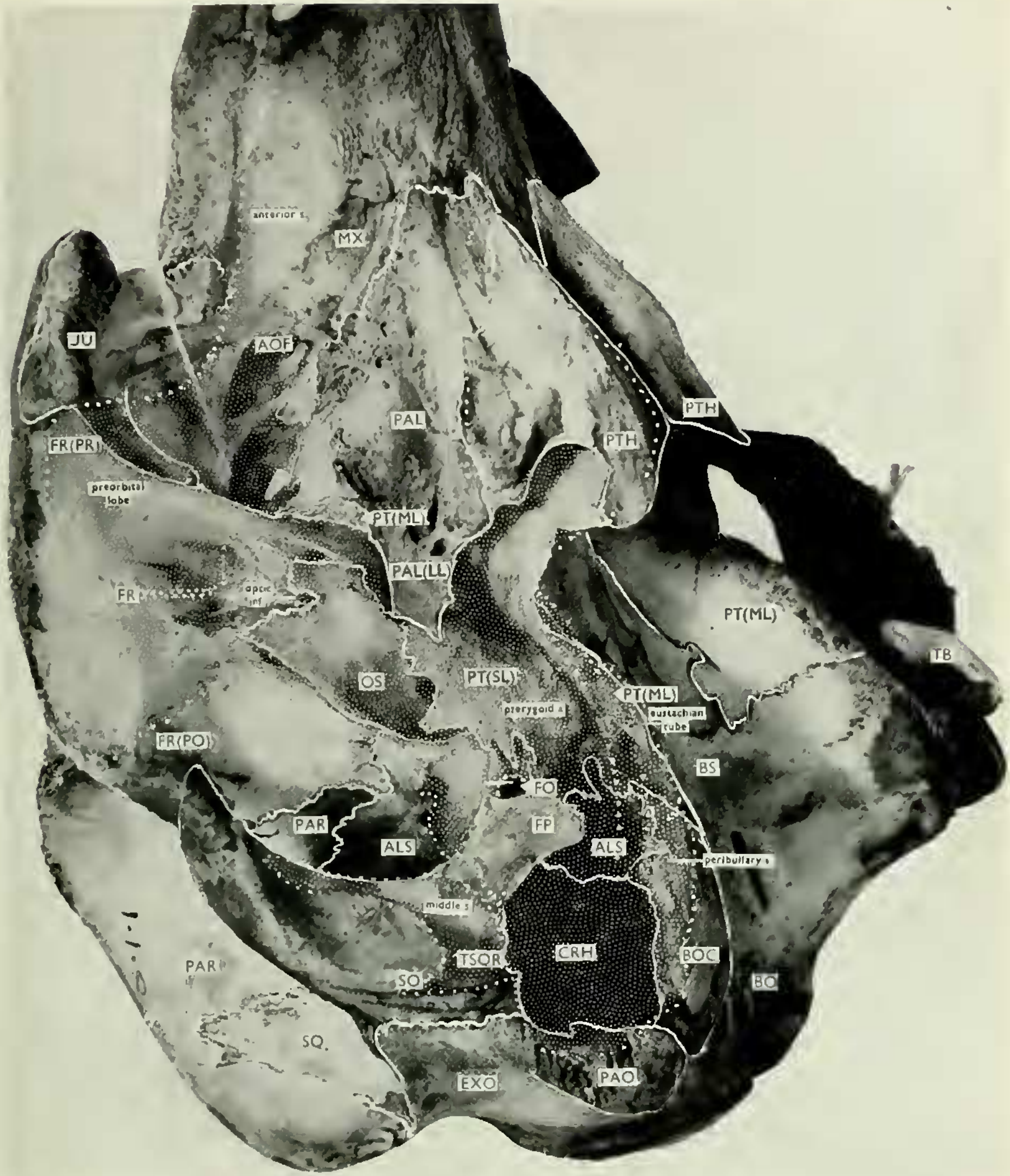

PLATE 24

Steno bredanensis (Reg. No. 1952.8.1.1)

Ventro-lateral aspect of skull base.

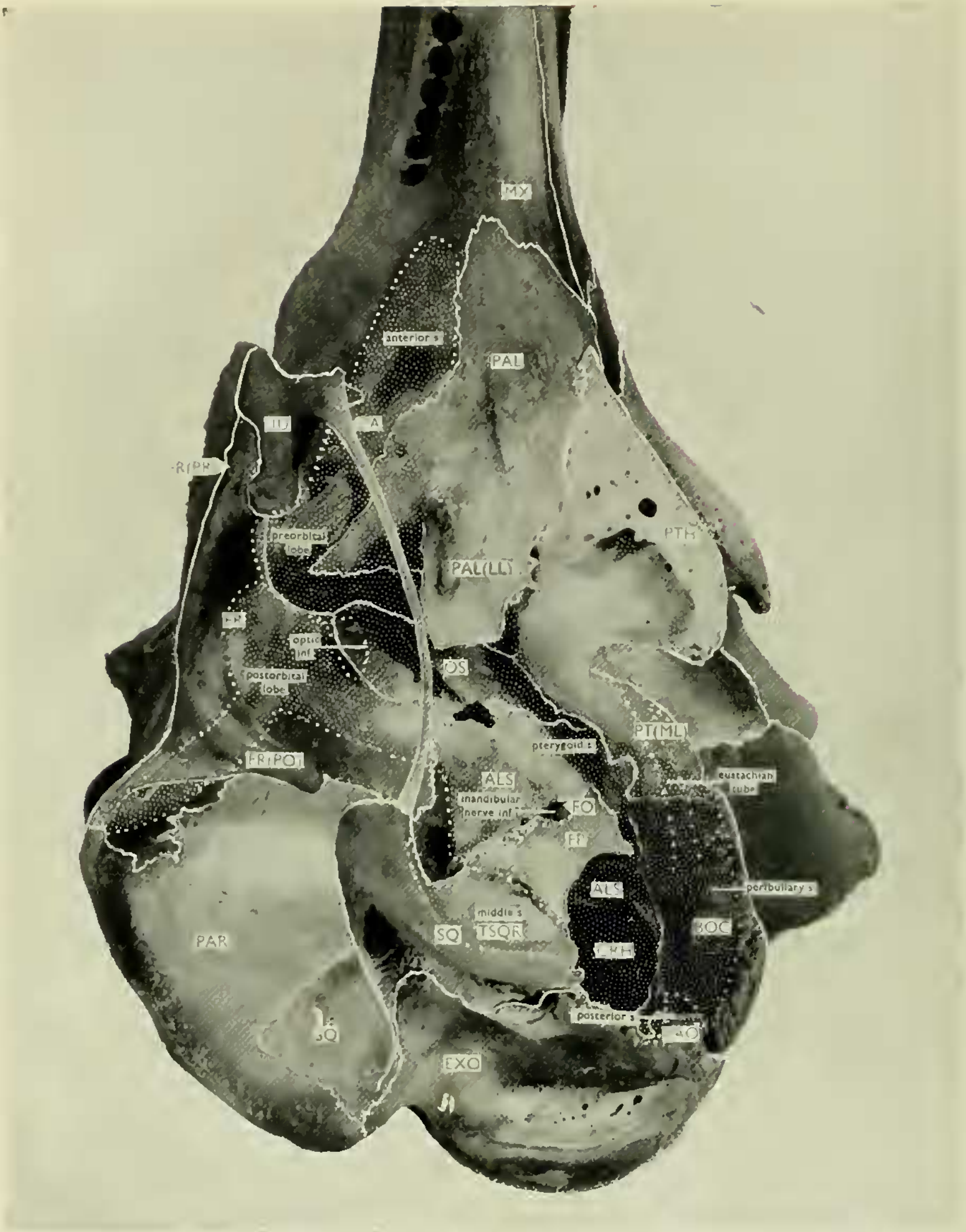

PLATE 25

Sousa borneensis (Reg. No. 1914.1.14.1)
Ventro-lateral aspect of skull base.

PLATE 26

Phocaena phocoena (Reg. No. S.W. 1950/15)
Ventro-lateral aspect of skull base.

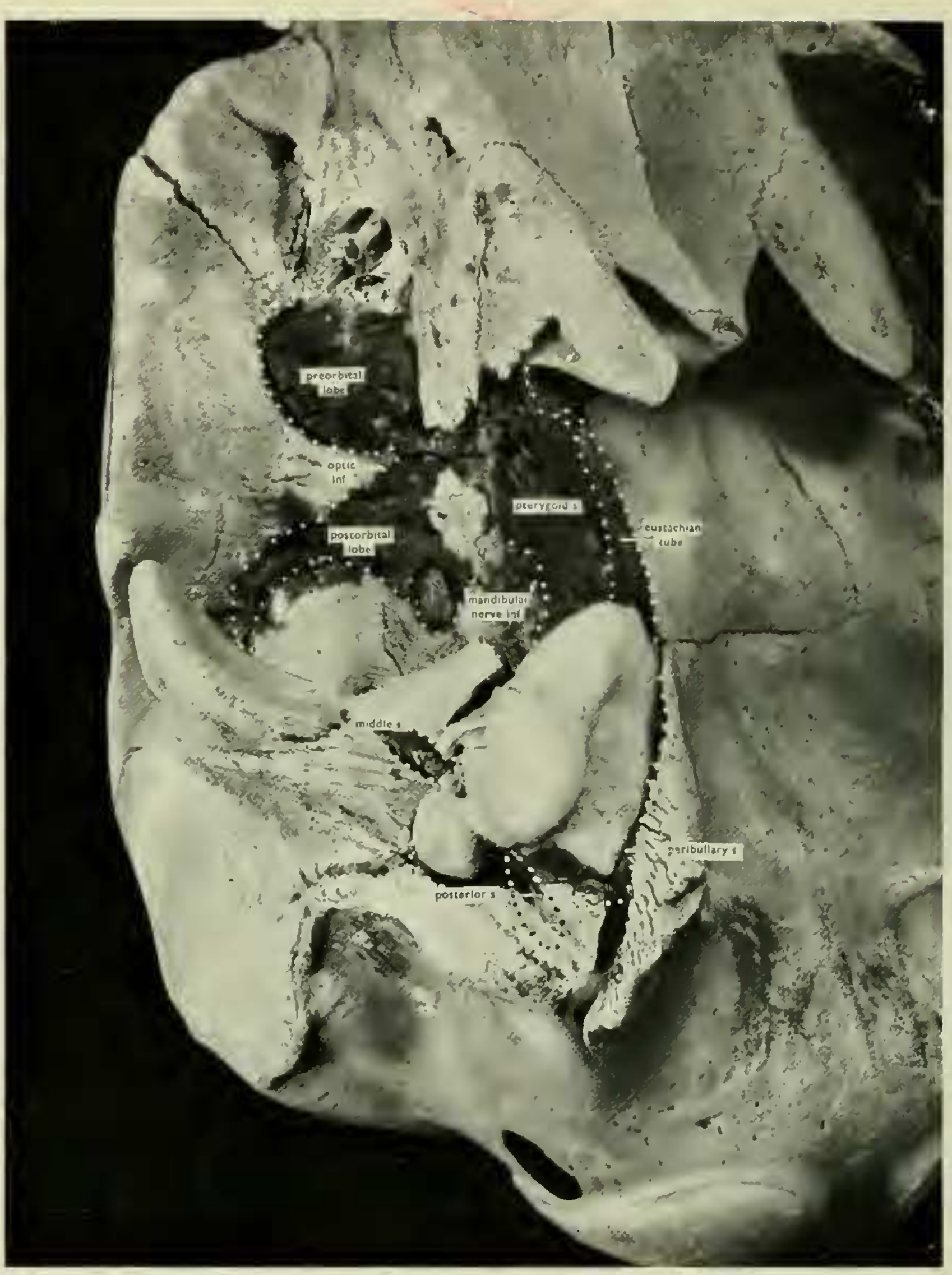

PLATE 27

Phocaena phocoena (Reg. No. S.W.1950/28)
Skull showing internal cast of air sinuses.

PLATE 28

Neomeris phocaenoides (Reg. No. 1903.9.12.3)
Ventro-lateral aspect of skull base.

PLATE 29

Pseudorca crassidens (Reg. No. S.W.1927/31)
Ventro-lateral aspect of skull base.

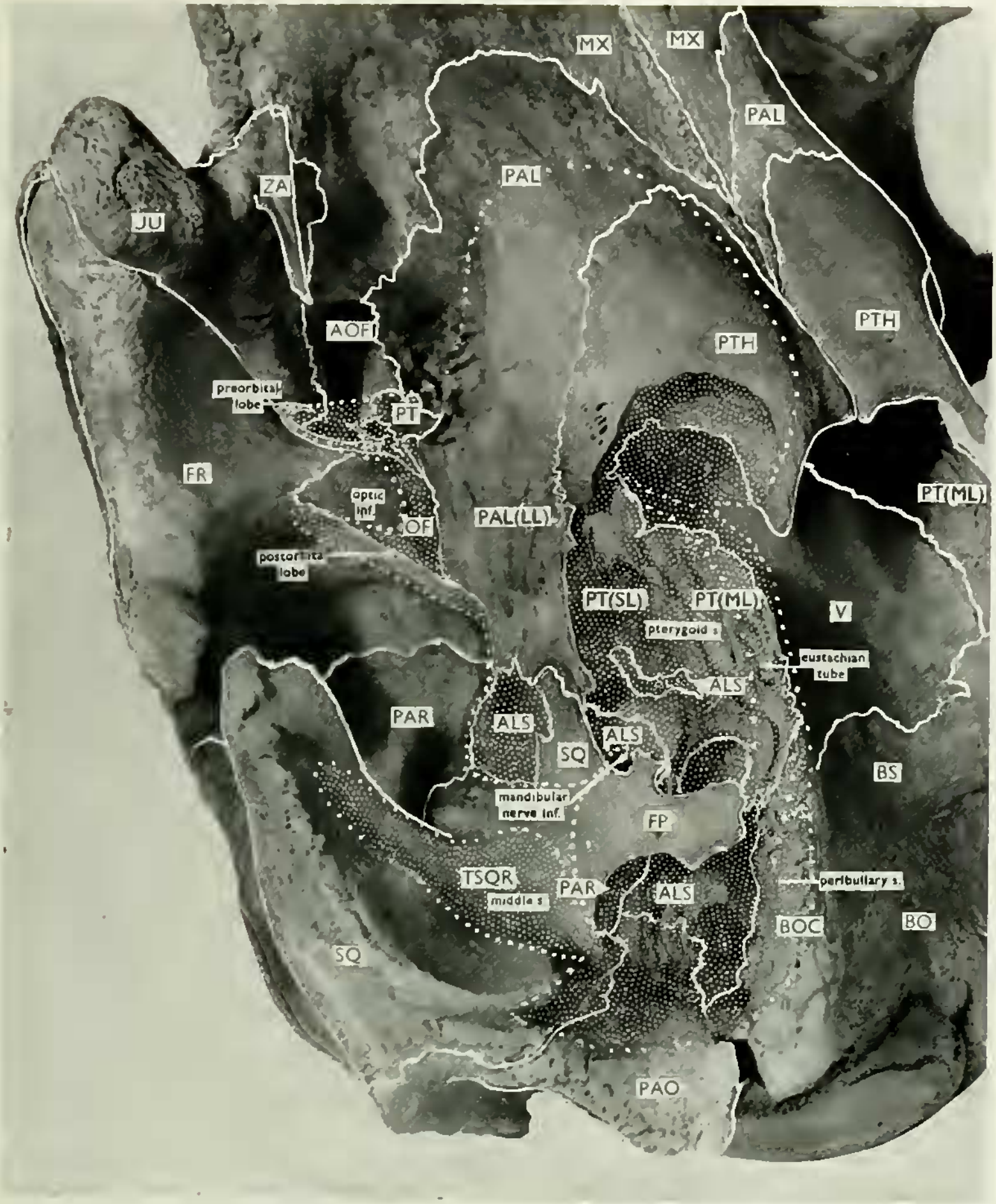

PLATE 30

Pseudorca crassidens (Reg. No. 1936.6.23.1)
Ventro-lateral aspect of skull base (for comparison with Plate 29).

PLATE 31

Orcinus orca (Reg. No. S.W. 1932/13)
Ventro-lateral aspect of skull base.

PLATE 32

Orcaella brevirostris (Reg. No. 1883.11.20.2)
Ventro-lateral aspect of skull base.

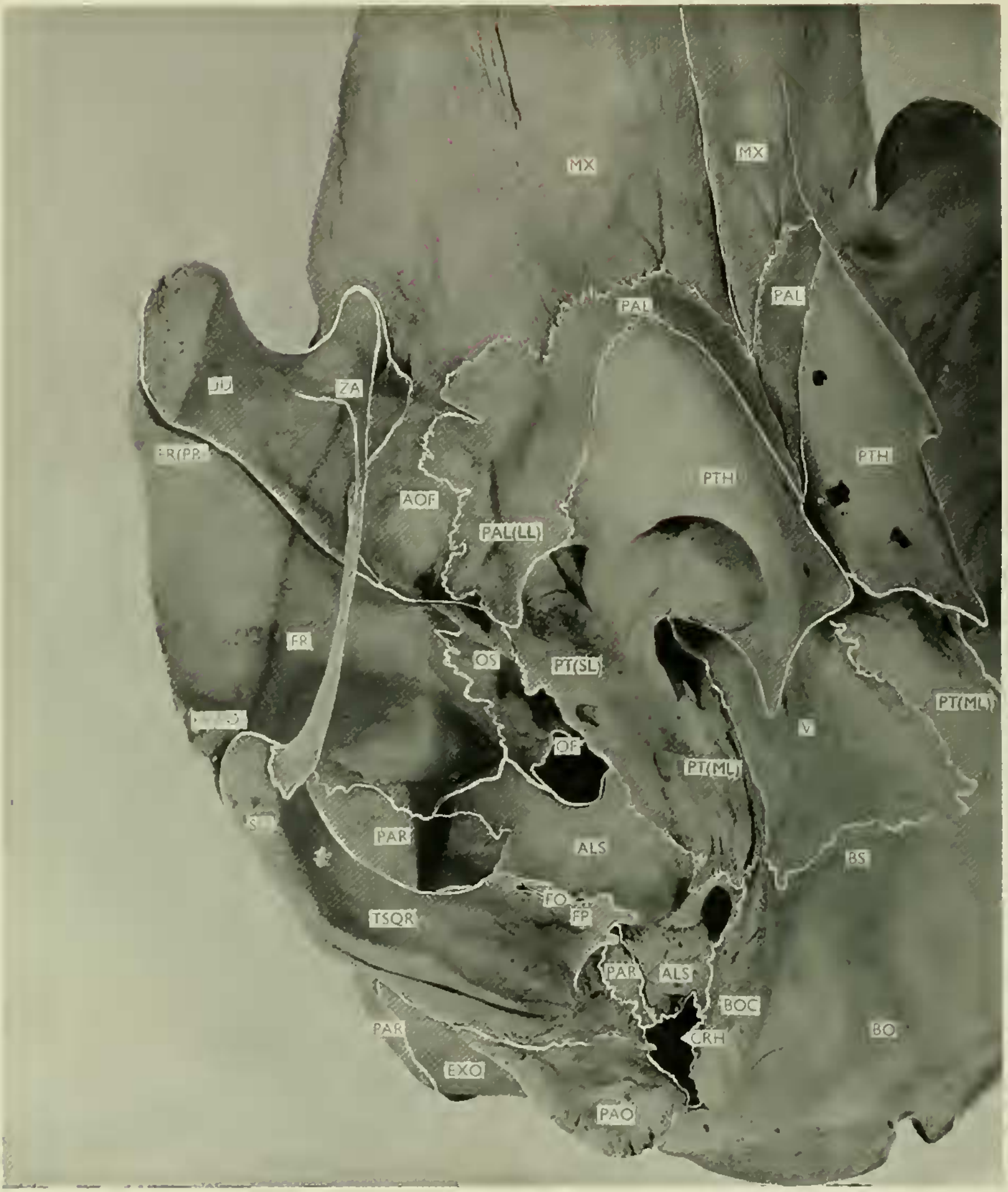

PLATE 33

Globicephala melaena (Reg. No. S.W.1932/1)
Ventro-lateral aspect of skull base.

PLATE 34

Globicephala melaena (Reg. No. 1950/7)
Skull showing internal cast of air sinuses

PLATE 35

Feresa intermedia (Reg. No. 1874.11.25.1)
Ventro-lateral aspect of skull base.

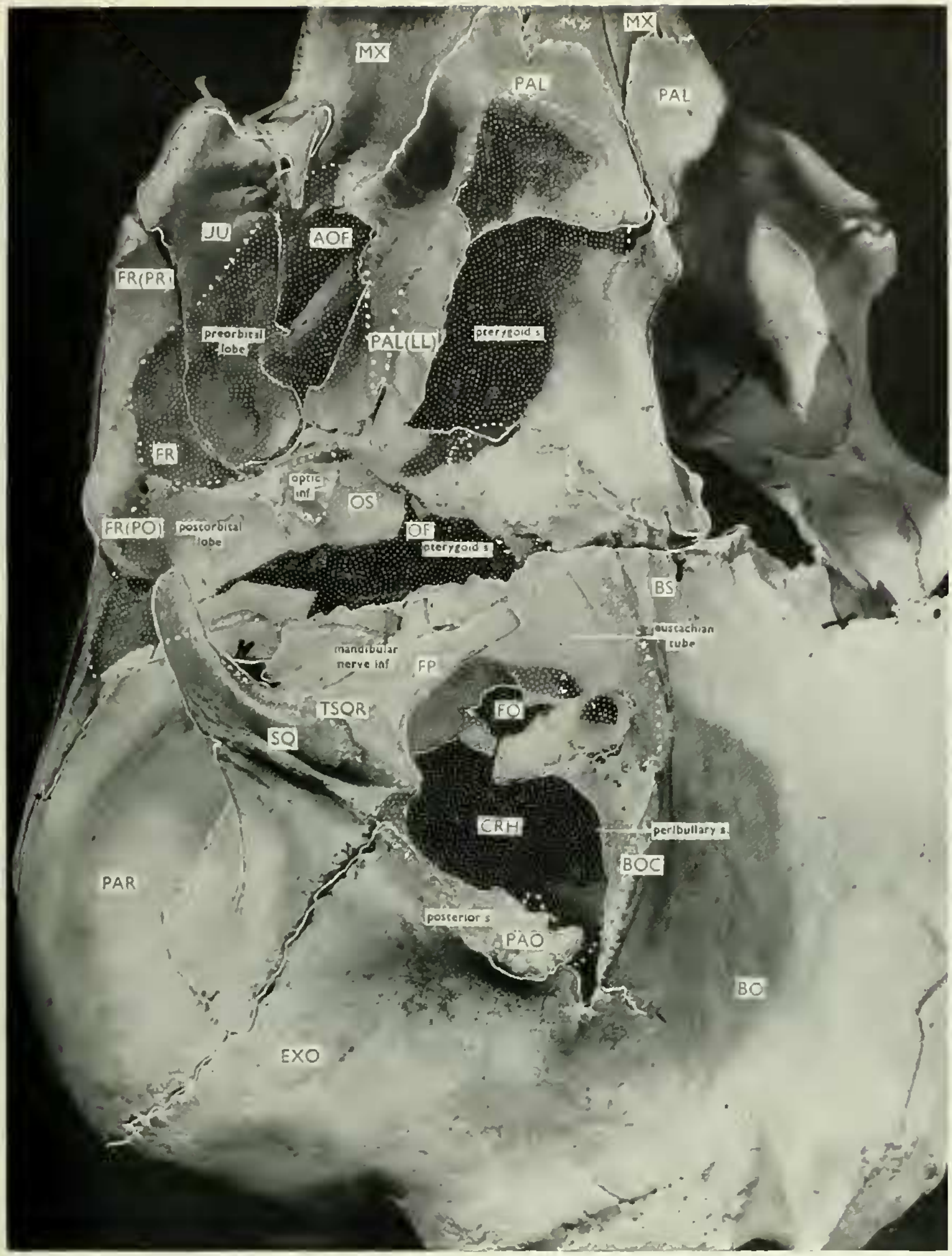

PLATE 36

Cephalorhynchus heavisidei (Reg. No. 1948.7.27.1)
Ventro-lateral aspect of skull base.

PLATE 37

Lagenorhynchus albirostris (Reg. No. S.W.1947/14)
Ventro-lateral aspect of skull base.

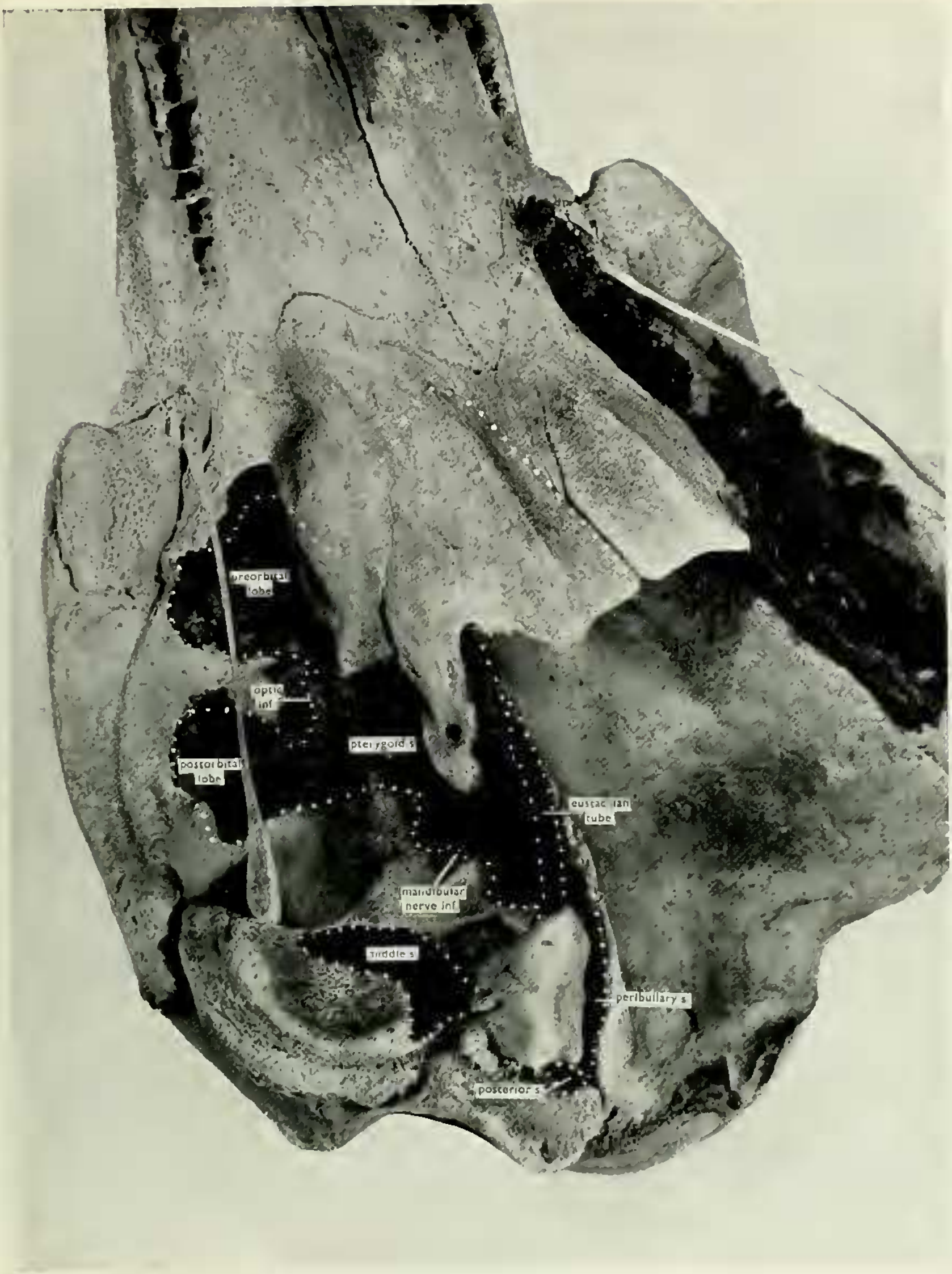

PLATE 38

Lagenorhynchus albirostris (Reg. No. S.W. 1951/9)
Skull showing internal cast of air sinuses.

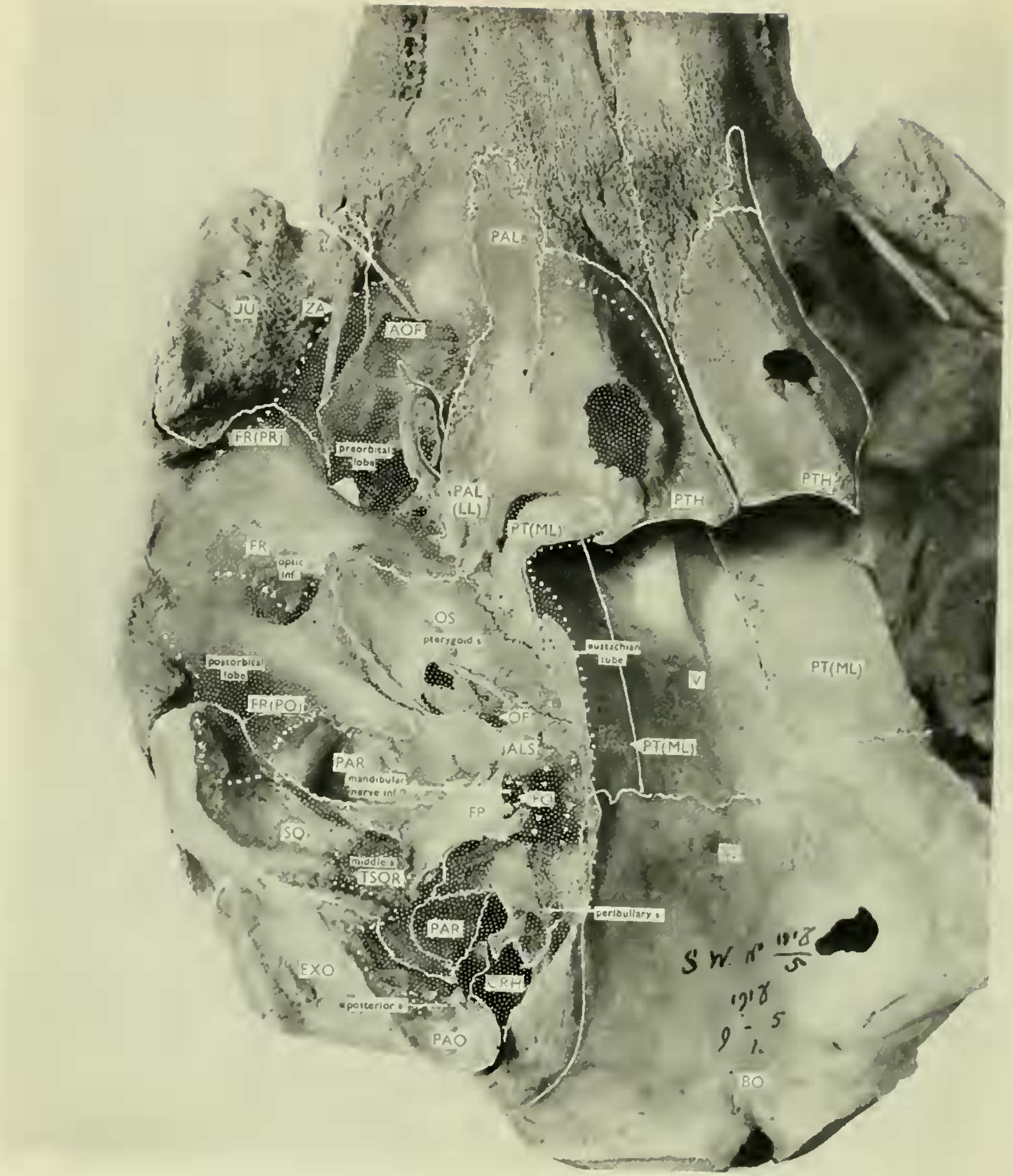

PLATE 39

Lagenorhynchus acutus (Reg. No. 1917.9.5.1)
Ventro-lateral aspect of skull base.

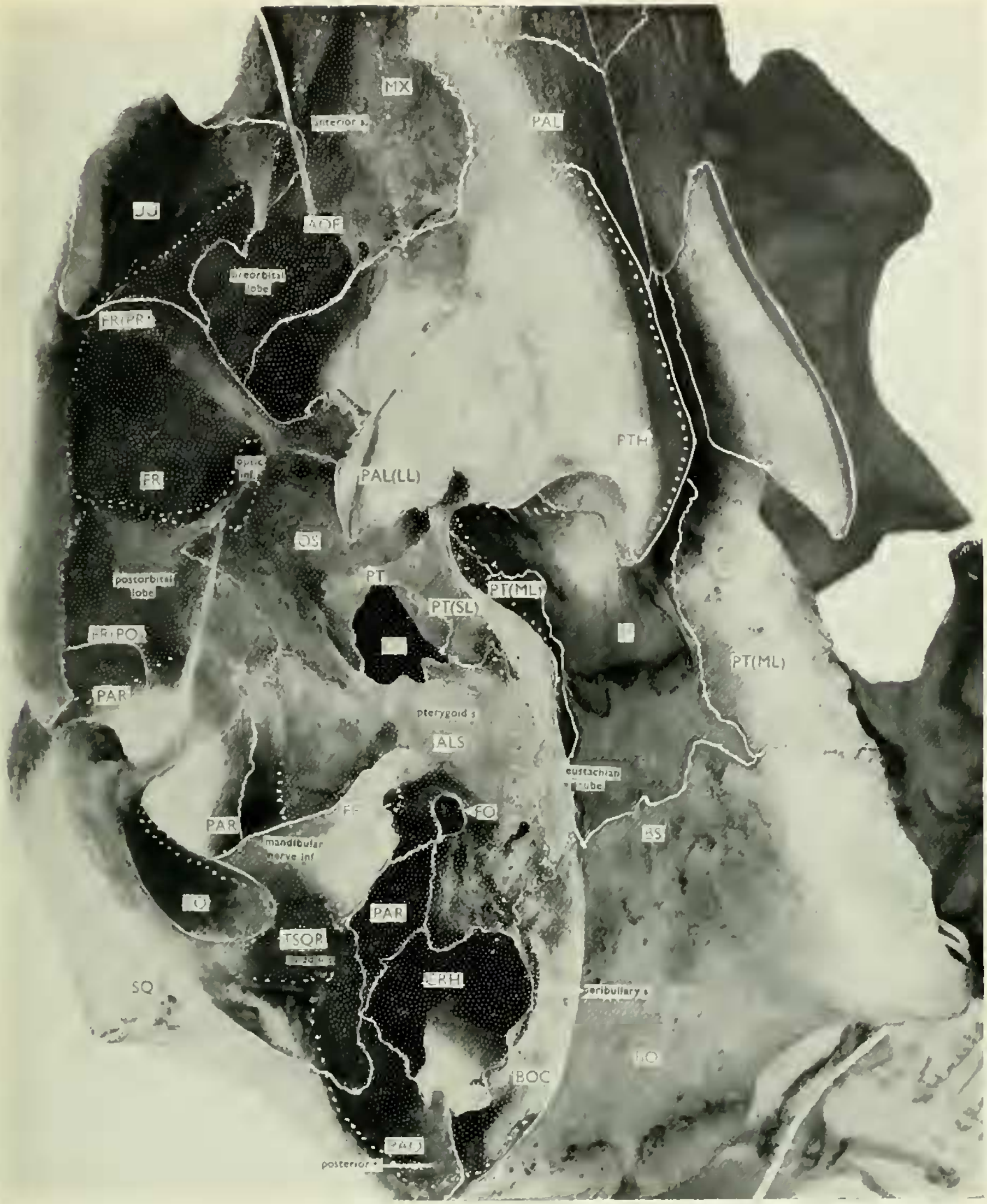

PLATE 40

Lagenorhynchus obscurus (Reg. No. 1944.11.16.1)
Ventro-lateral aspect of skull base.

PLATE 41

Grampus griseus (Reg. No. S.W.1922/7)
Ventro-lateral aspect of skull base.

PLATE 42

Grampus griseus (Reg. No. S.W.1951/3)
Skull showing internal cast of air sinuses.

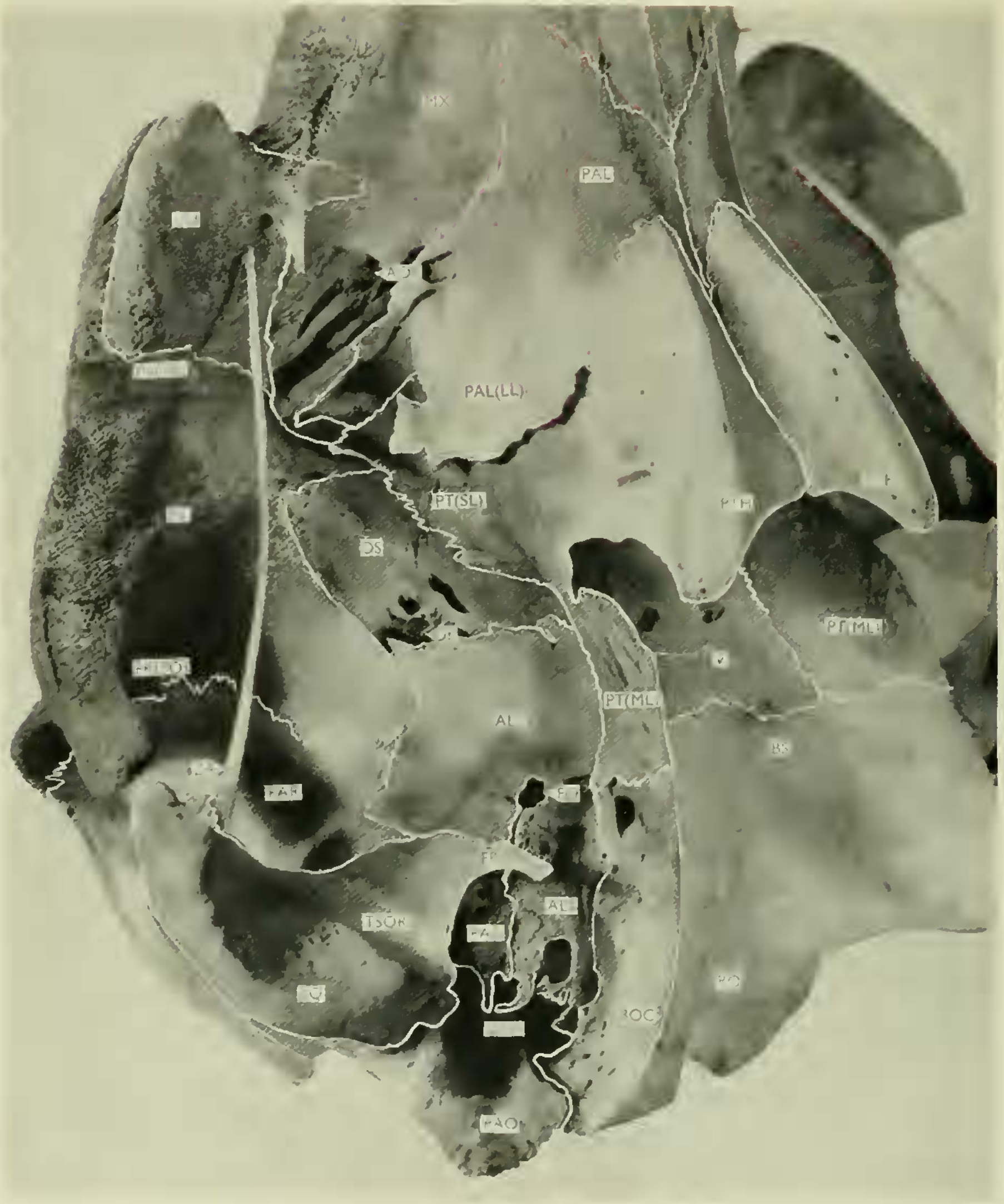

PLATE 43

Tursiops truncatus (Reg. No. 1951.11.26.2)
Ventro-lateral aspect of skull base.

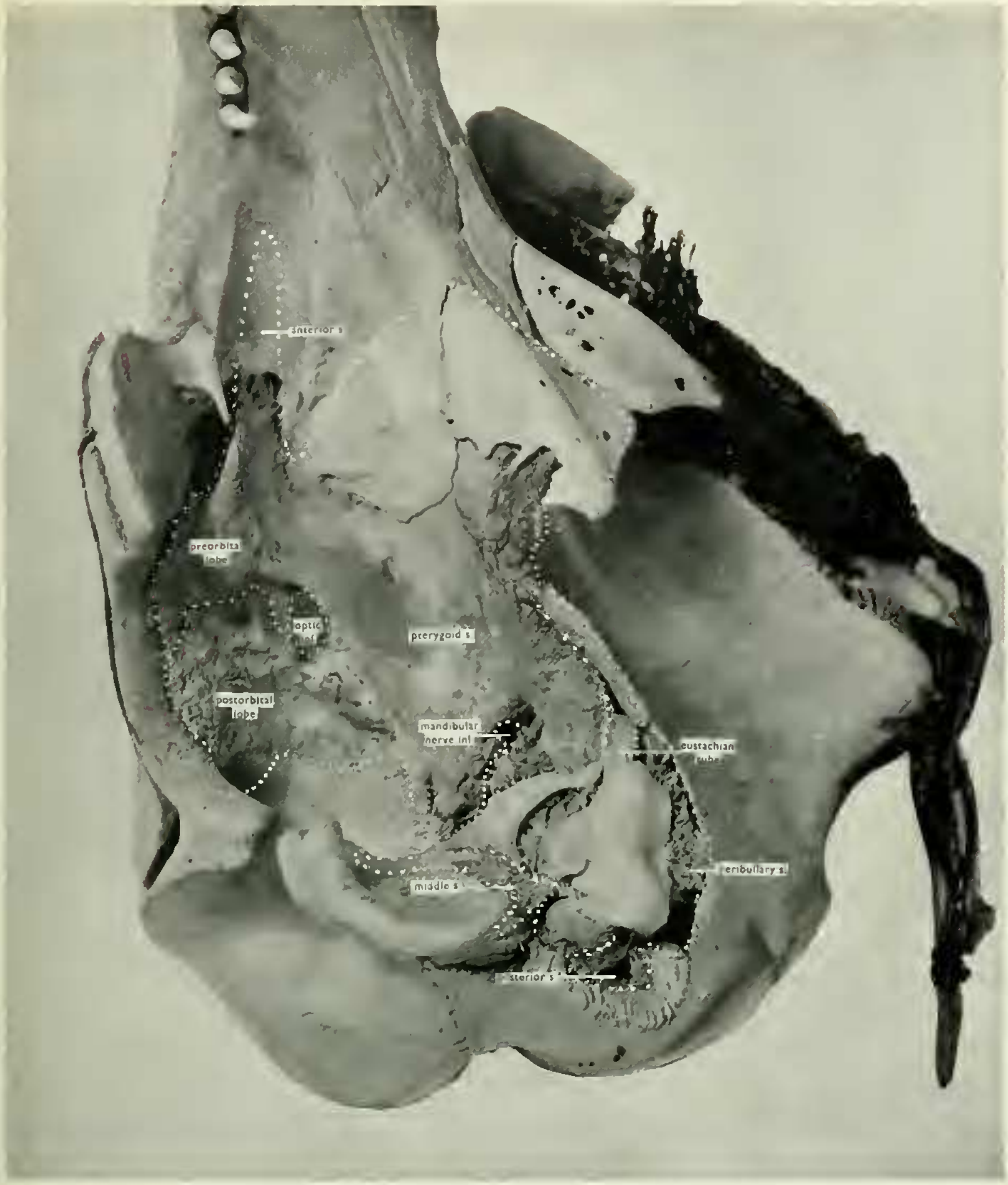

PLATE 44

Tursiops truncatus (Reg. No. 1951.11.26.1)
Skull showing internal cast of air sinuses.

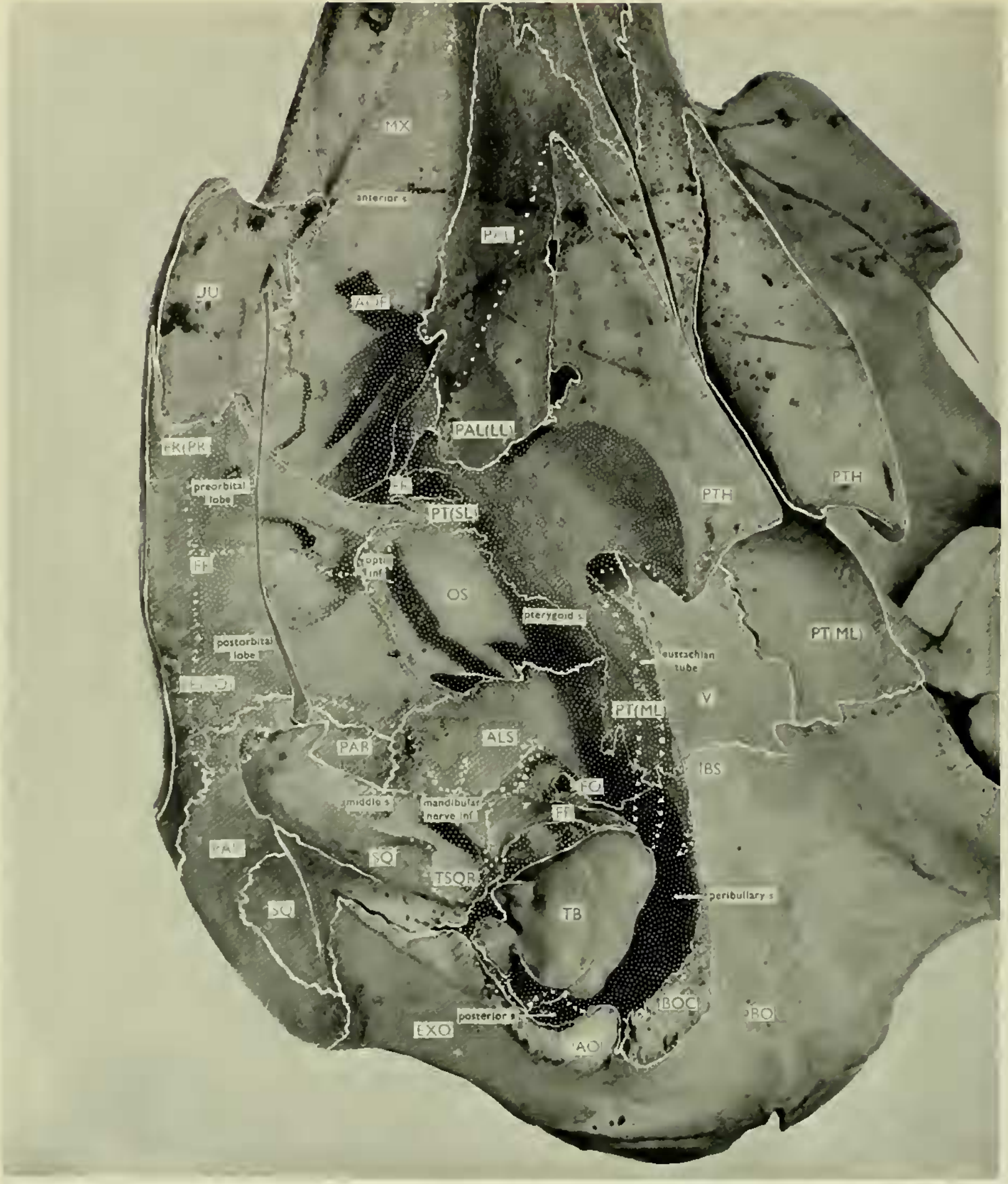

PLATE 45

Stenella euphrosyne (Reg. No. 1938.2.5.1)
Ventro-lateral aspect of skull base.

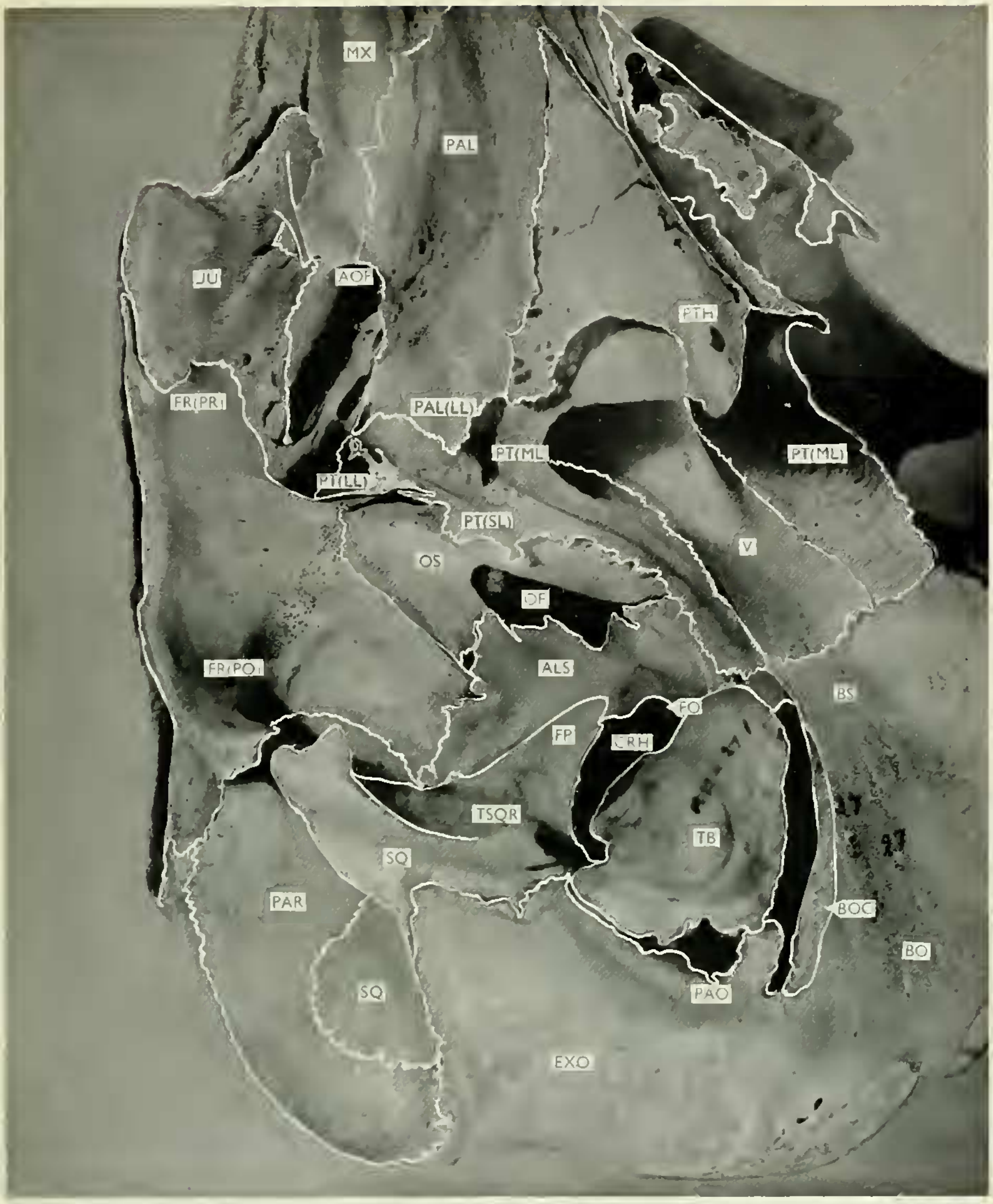

PLATE 46

Delphinus delphis (Reg. No. 1937.11.27.1)
Ventro-lateral aspect of skull base.

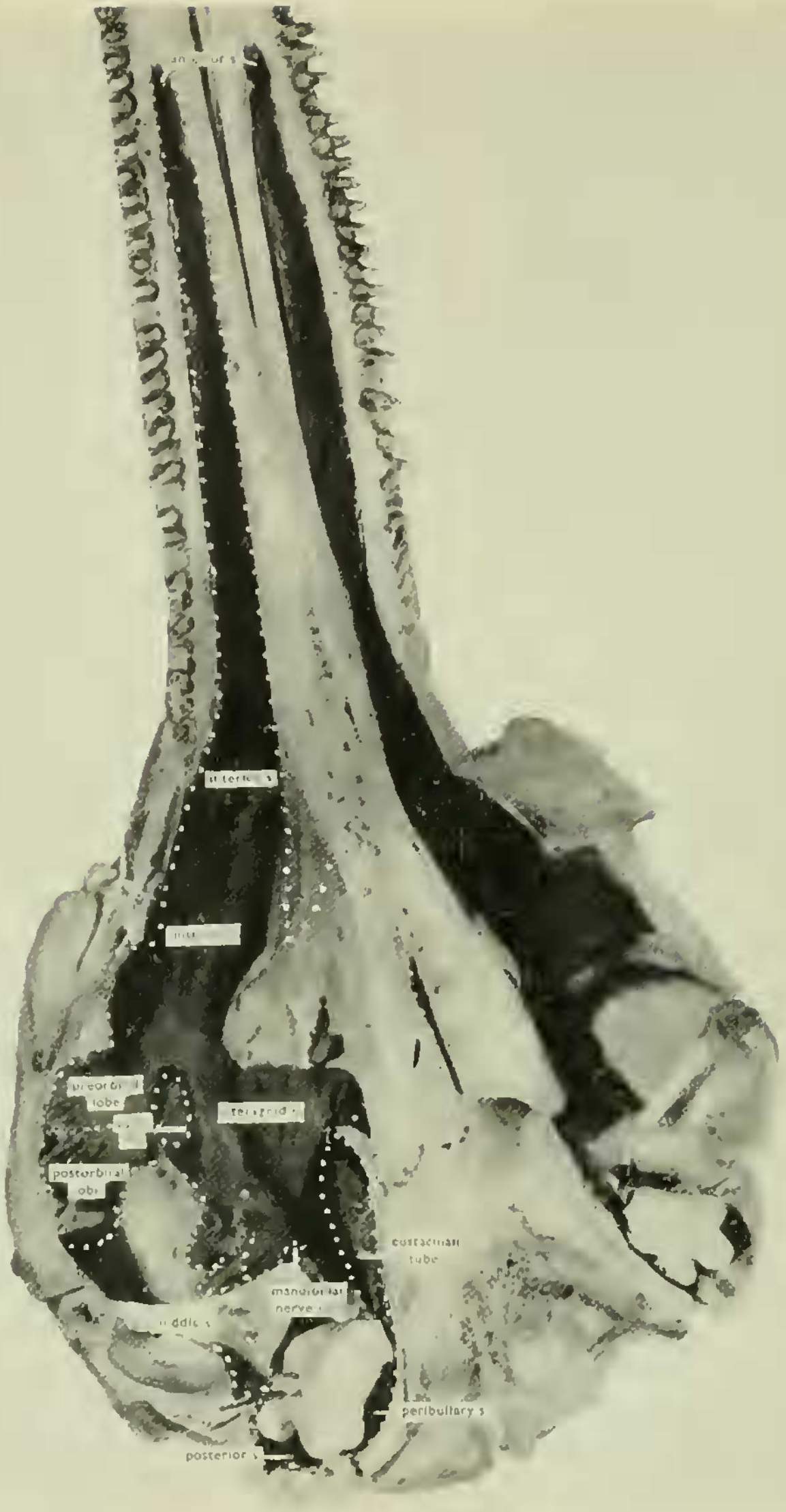

PLATE 47

Delphinus delphis (Reg. No. S.W. 1952/2)
Skull showing internal cast of air sinuses.

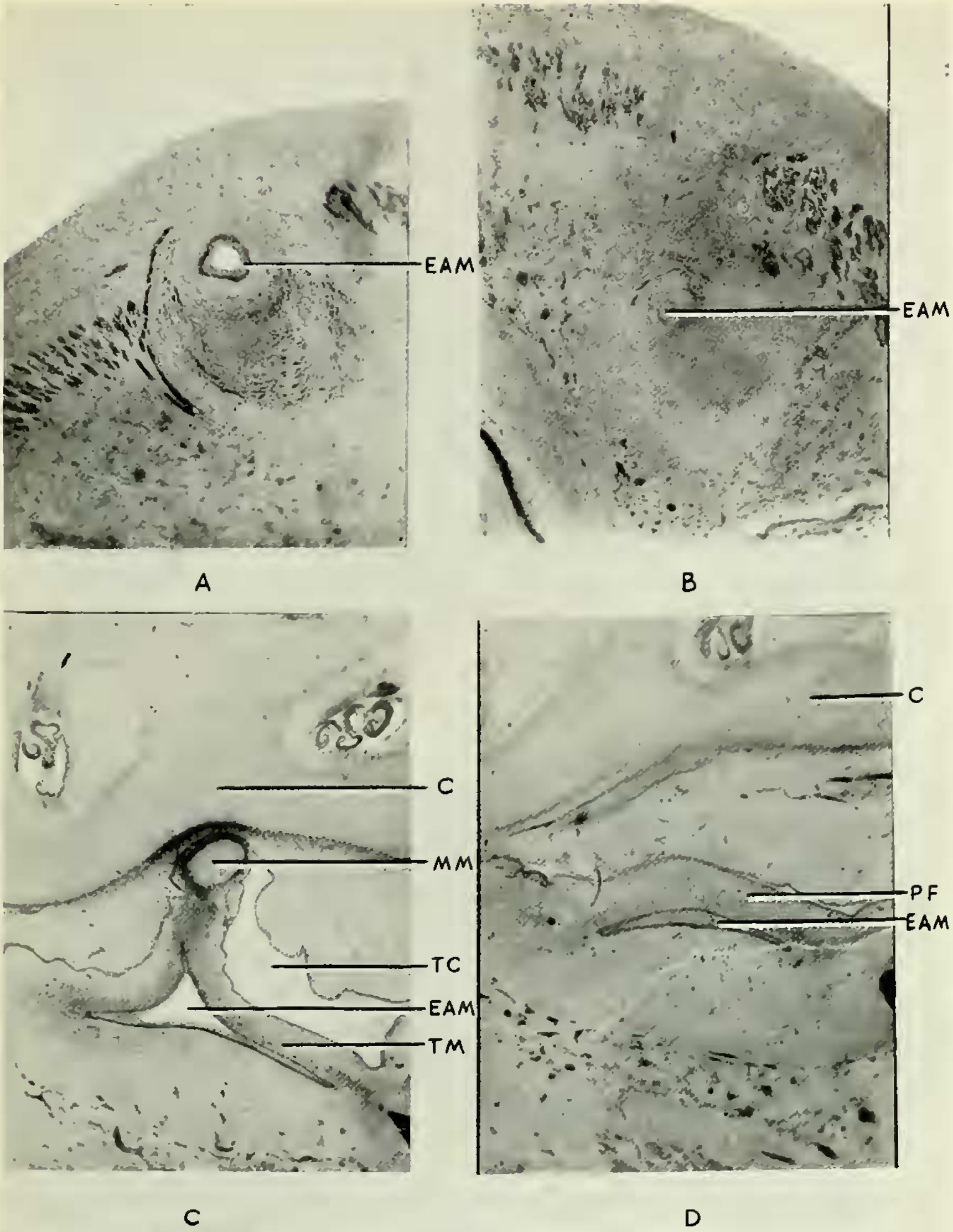

PLATE 48

Longitudinal sections in the region of the ear of a foetal Humpback, *Megaptera novaeangliae*

(A) Distal end of external auditory meatus (× 40).

(B) Closed portion of external auditory meatus (× 40).

(C) Section through tympanic membrane, manubrium mallei and tympanic cavity (× 40).

(D) Pars flaccida of the tympanic membrane (× 40).

PLATE 49

Dissection of the middle ear of *Globicephala melaena* (cf. Text-figure 26)

PLATE 50

Dissection of the middle ear of *Balaenoptera acutorostrata* (cf. Text-figure 27)

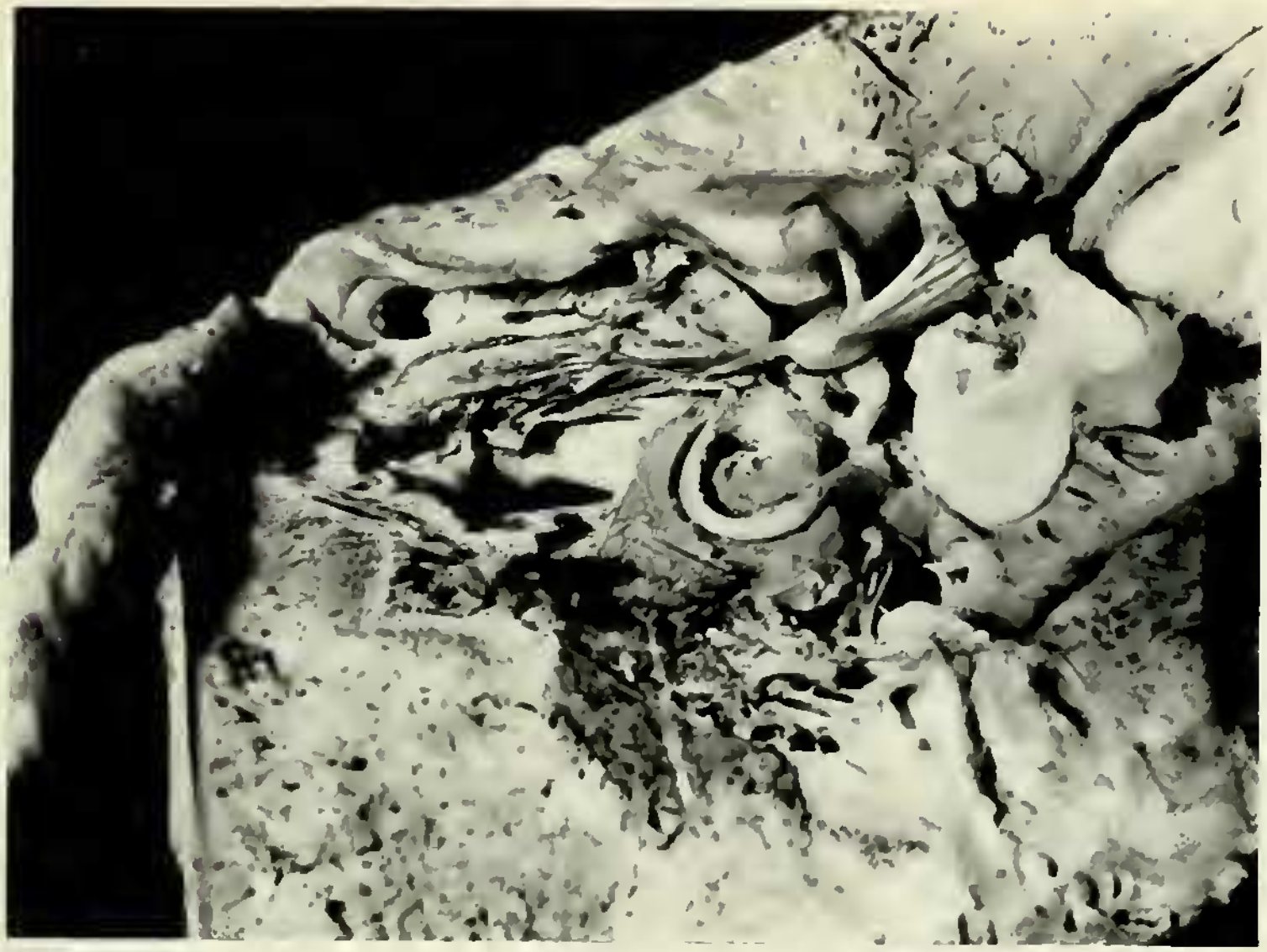

PLATE 51

Dissection of the ear of *Balaenoptera physalus*

Starting from the right of the figure the following features in succession -open pigmented part of the external meatus with blubber adjacent ; auricular cartilage with muscles attached ; the cord-like portion of meatus, the proximal portion of the meatus lying in the squamo-mastoid groove with part of the corium removed to show the ear plug and glove finger, the tympanic bulla with mesial half removed to show middle ear cavity and pterygoid sinus. Acoustic probes are shown in three of the positions used for testing sound attenuation.

PLATE 52

Dissection of the ear of *Balaenoptera physalus* showing glove finger and ear plug.

The ear plug has been bisected to show laminations, but in life it would completely envelop the glove finger of which it is the zona cornea. The extension of the middle ear cavity into the pterygoid sinus shows part of the fibro-venous plexus (bottom left). Acoustic probes are placed on the malleus and ear plug.

PLATE 51

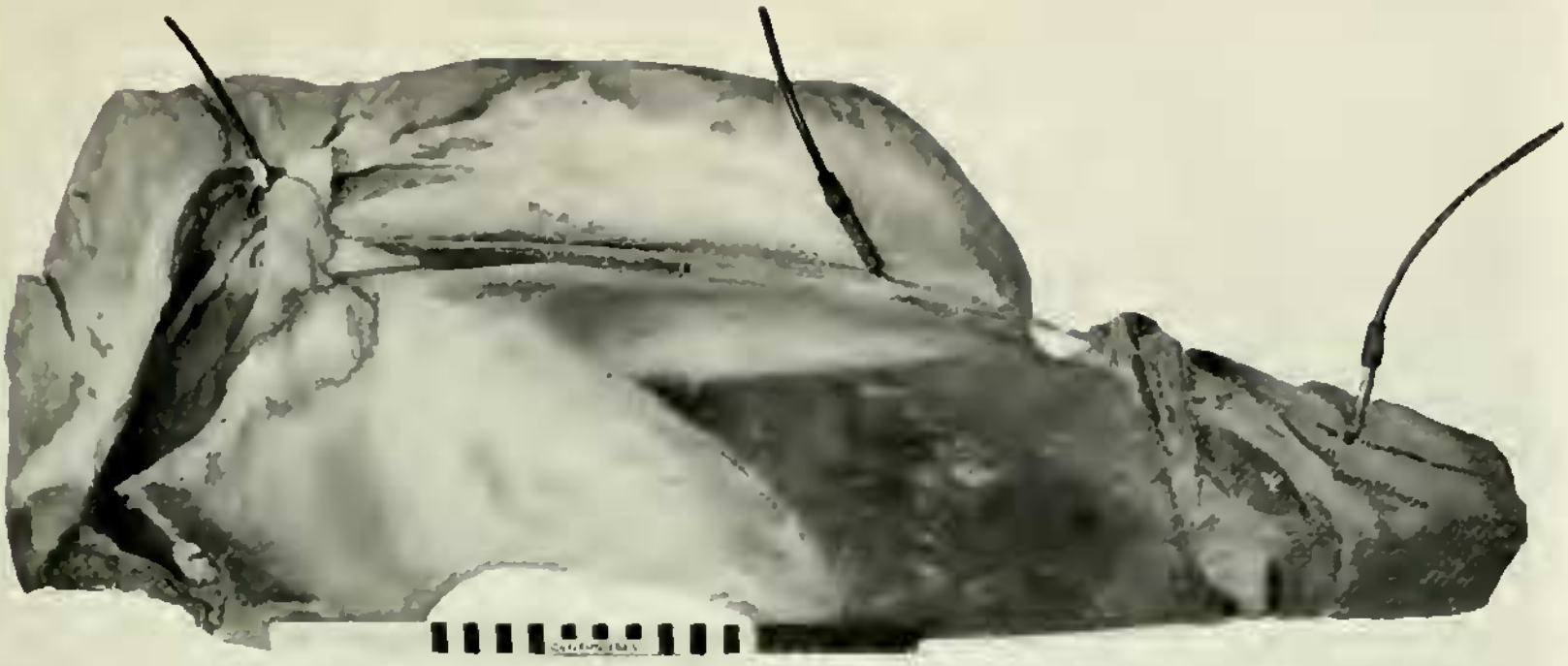

PLATE 52

PLATE 53

Dissection of the middle ear and cochlea of *Balaenoptera physalus*

Dissection shows the tympanic ligament (TL) attached to the malleus (MM) which is fused to the sigmoid process of tympanic bulla. The tensor tympani muscle (TT) passes obliquely downwards to the right of the exposed cochlea (C). The incus (I) and stapes (ST) are situated above the cochlea. The atrophied internal carotid artery (ACI) passes obliquely across the tympanic cavity to the left of the cochlea. The groove in which the stapedial muscle (SM) lies can be seen above the cochlea. Note the muscle mass (M) the tendon of which passes through the tympanic annulus to the internal face of the "glove-finger" (Shrapnell's membrane, GL).

By courtesy of "Endeavour".


CI
M
I
T
C
GL
M
TL
SP
MM
TT